

# Gastrocnemius Muscle Flap and Its Application in Lower Extremity Reconstruction

Ali Karbalaieikhani,<sup>1</sup> Salman Dekhoda,<sup>2</sup> Hossein Saremi<sup>3\*</sup>

*Department of Hand and Microsurgery,<sup>1</sup> and Department of Surgery,<sup>2</sup> Emam Reza Hospital, AJA University of Medical Sciences, Tehran, Iran.*

*<sup>3</sup> Department of Hand and Microsurgery, Besat Hospital, Hamedan University of Medical Sciences, Hamedan, Iran.*

**Keywords:** limb salvage procedures; gastrocnemius muscle flaps, skeletal reconstruction; reconstructive surgical procedures; tibial bone coverage.

AMHSR 2015;13:154-156  
www.journals.ajajms.ac.ir

## INTRODUCTION

Lower extremity trauma due to a car crash or war mine explosion is still challenging. The early history of the lower extremity reconstruction dates back to the Hippocrates (460-370BC). Since then, until the First World War, amputation was the best option for saving the lives of the patients.<sup>(1)</sup> Sushruta Sumhita (600BC) was the first person who used the cheek flap for nasal reconstruction.<sup>(2)</sup> However, the new era of the flap reconstruction commenced during the First World War. Although in that time Stark was the first person who used muscle flap to cover lower extremity due to osteomyelitis, the first report of the lower extremity reconstruction by muscle flap was done by Ger.<sup>(2)</sup> Gastrocnemius muscle has also been used to cover the exposed implant of tibia and knee prosthesis.<sup>(3,4)</sup> Early coverage of the complicated wound of the tibia by the gastrocnemius muscle flap can prevent major complications.<sup>(5,6)</sup>

Based on the Mathes and Nahai classification<sup>(7)</sup> for vascular pedicle, gastrocnemius muscle flap is classified as type one and it has one vascular pedicle. The gastrocnemius muscle flap is often used to cover soft tissue defects of the knee and the upper third of the leg. Its major benefits include minimal donor morbidity, easy harvest and reliability.<sup>(8)</sup>

## CASE PRESENTATION

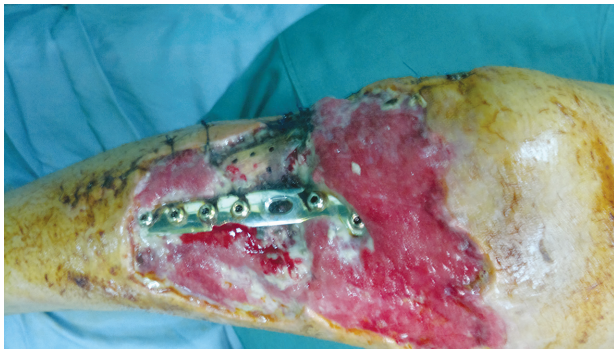
A 76-year-old man was brought to the emergency room of our center because of a car crash. He had multiple traumas. Traumas to the head and neck, chest, and abdomen were rolling out. His right leg was injured

and the tibial bone was fractured at plateau and upper tibial shaft but without vascular trauma. He was admitted in the emergency ward after stabilization.

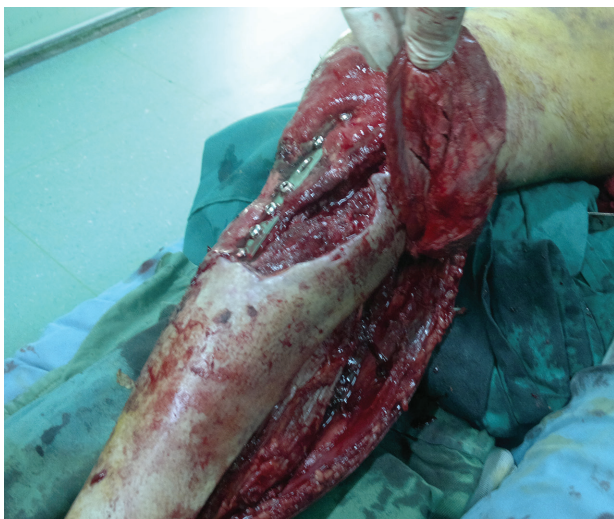### Treatment

The patient was taken to the operation room under spinal anesthesia. Open reduction and internal fixation of the tibia fracture was performed by hardware plate. Few days after the operation, soft tissue necrosis was seen at the incision site and the implanted hardware was exposed **Figure 1**. It was decided to cover the exposed hardware by medial head of the gastrocnemius muscle flap. Then the patient was taken to operation room. After preparation under spinal anesthesia in the supine position, the right limb was externally rotated and the knee slightly flexed. The incision started at midcalf, 2 cm behind the posteromedial border of the tibial bone, and was curved proximally to reach the popliteal fossa. Then, the skin, subcutaneous tissue and deep fascia were incised on the line of the incision, and a large skin flap was retracted posteriorly until the plane between the two heads of the gastrocnemius muscle was exposed. The intermuscular plane was developed with finger between soleus and the medial head of the gastrocnemius. The plantaris tendon was dissected, the sural nerve and the saphenous vein between the two heads of the gastrocnemius muscle were identified and saved. Then distal tendon of the medial head was divided. The muscle was progressively raised in a distal to proximal direction by cutting the aponeurotic sheet that joins the two heads. The motor to gastrocnemius was easily accessible but not divided. The medial head was completely freed (**Figure2**).

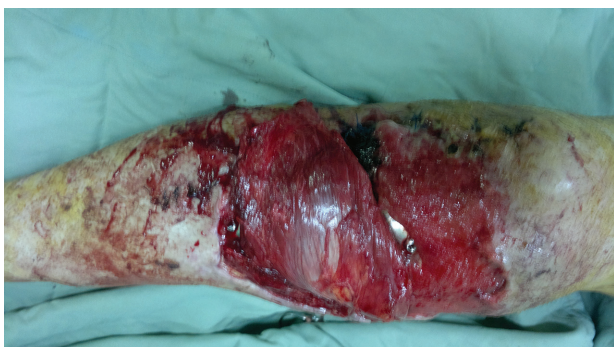A tunnel was made underneath the bipedicle fasciocutaneous flap between the incision and exposed hardware. The muscle was passed through the tunnel. The muscle flap was inset and covered the wound completely (**Figure 3**). Afterwards, the muscle flap was covered by split thickness skin graft from the same thigh and the grafted area was tied over (**Figure 4**).



**Figure 1.** Right tibial bone fracture and exposed hardware after open reduction and internal fixation.



**Figure 2.** Right medial head of gastrocnemius is freed and ready to transfer to the donor area.



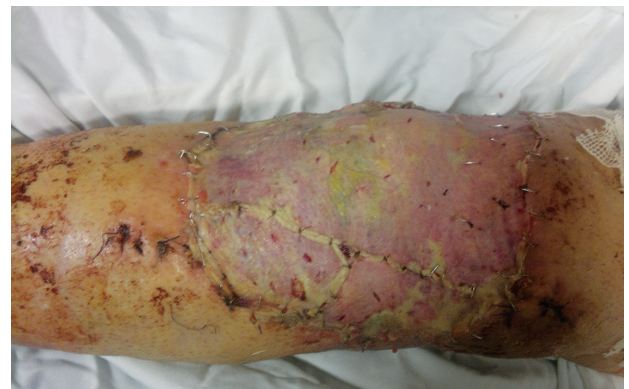**Figure 3.** The medial head of the gastrocnemius is passed through fasciocutaneous tunnel and inset to the donor area.

### Outcome

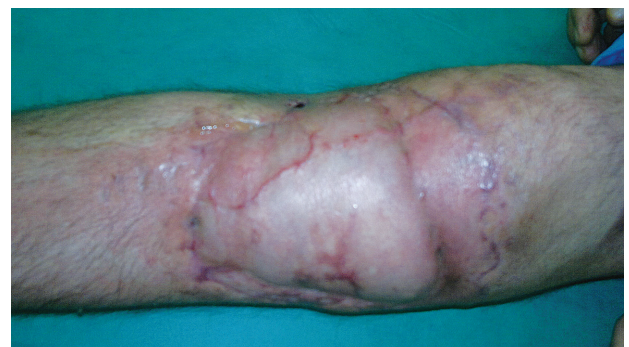After five days the tie over of the grafted muscle flap was removed. Complete healing of the exposed area and exposed hardware occurred without any complication (**Figure 5**). Two weeks after gastrocnemius muscle flap transfer, the patient was discharged from the hospital. He had intact tibial and peroneal nerves and his arteries were intact. He started physical therapy for getting the range of motion for knee joint. The patient was satisfied of his knee and limb function.

### DISCUSSION

The tissue defect has always been a challenge for reconstructive surgeons. The first systemic procedure using flap for repairing a mutilated nose in an adult is attributed to Sushruta, who lived in the sixth or seventh century BC.<sup>(9)</sup> In 1892 the Italian surgeon Ignio Tansini, the professor of surgery at the University of Pavia, perfected the method of breast amputation for breast cancer by radical removal of the tumor with the overlying skin.<sup>(10)</sup> On an early attempt, Tansini covered the resulting defect by a dorsal flap whose pedicle was based in the arm pit. But the flap did not survive completely. Tansini,



**Figure 4.** The gastrocnemius muscle flap after removing of the tie over, five days after the operation.



**Figure 5.** Final result of the repaired leg by the muscle flap.

then, studied the vascular anatomy of the region with the anatomist Sala and described the correct anatomy of the pedicle of the latissimus dorsi muscle flap.<sup>(10)</sup>

The gastrocnemius muscle is the most superficial muscle of the posterior calf. It has two heads, medial and lateral, which form the distal border of the popliteal fossa. Each head can be used as a separate muscle or musculocutaneous unit, based on its own pedicle. The medial head originates from the medial condyle of the femur and the lateral from the lateral condyle of the femur. Both heads insert to the calcaneus through the Achilles tendon. The gastrocnemius muscle helps the plantar flexion of the foot. One or both heads of the muscle are expandable if the soleus muscle is intact.

The blood supply to the muscles has been studied and defined, particularly by Mathes and Nahai, who proposed a classification based on the type of vascularization 1981.<sup>(7)</sup> Based on this classification the gastrocnemius muscle is type I vascular pedicle which penetrates the muscle belly at its proximal pole (the medial muscle is supplied by the medial sural artery and the lateral muscle is supplied by the lateral sural artery). Each head of gastrocnemius is a good illustration of this type. The muscular body of the medial head is longer and the arc of rotation of the transfer allows easy coverage of the inferior thigh, anterior and medial aspect of the knee, and upper third of the tibia.<sup>(11)</sup>

Contraindications to the use of a gastrocnemius flap and its medial head include vascular compromise of the muscle itself by disruption of the sural artery pedicle, compromise of the popliteal artery from which it emanates, or occlusion of the proximal arterial tree. Significant local trauma to the muscle itself, although rare, prevents its successful rotation.<sup>(12)</sup>

## CONCLUSIONS

The gastrocnemius muscle flap and its medial head are reliable to cover the exposed knee and upper third of the leg, without any significant loss of the lower leg and ankle function.

## CONFLICT OF INTEREST

The authors would like to thank Seyed Muhammed Hussein Mousavinasab for his sincere cooperation in editing this text.

## REFERENCES

- Aldea PA, Shaw WW. The evolution of the surgical management of severe lower extremity trauma. *Clin Plast Surg.* 1986;13:549-69.
- Ger R. The technique of muscle transposition in the operative treatment of traumatic and ulcerative lesions of the leg. *J Trauma.* 1971;11:502-10.
- Sanders R, O'Neill T. The gastrocnemius myocutaneous flap used as a cover for the exposed knee prosthesis. *J Bone Joint Surg Br.* 1981;63-B:383-6.
- Meller I, Ariche A, Sagi A. The role of the gastrocnemius muscle flap in limb-sparing surgery for bone sarcomas of the distal femur: a proposed classification of muscle transfers. *Plast Reconstr Surg.* 1997;99:751-6.
- Byrd HS, Spicer TE, Cierney G 3rd. Management of open tibial fractures. *Plast Reconstr Surg.* 1985;76:719-30.
- Osman GM, Ayad WM, El-Moghazy AE. Versatility of the gastrocnemius muscle flap for coverage of upper third leg and knee with reconstruction of quadriceps apparatus. *AAMJ.* 2005;3:191-9.
- Mathes SJ, Nahai F. Classification of the vascular anatomy of muscles: experimental and clinical correlation. *Plast Reconstr Surg.* 1981;67:177-87.
- Hendy A, Abdel-Mohsen Allam MD, Abdel-Khalek AH, et al. Split Gastrocnemius Muscle Flap. *Egypt J Plast Reconstr Surg.* 2003;27:181-7.
- Bhishagratna KL, editor. An English translation of the Sushruta Samhita based on original Sanskrit text. Philadelphia, United States: Wilkin's Press;1907. p. 107.
- Nuovo processo per amputations della mammella per cancro. *Reform Med.* 1896;12:3-5.
- Veber M, Vaz G, Braye F, et al. Anatomical study of the medial gastrocnemius muscle flap: a quantitative assessment of the arc of rotation. *Plast Reconstr Surg.* 2011;128:181-7.
- Wiss DA, editor. *Fractures.* Philadelphia, United States: Lippincott Williams & Wilkins; 2006.

### Corresponding Author:

Hossein Saremi, MD  
Besat Hospital, Mazdaghineh St., Beheshti Blvd., Hamedan, Iran.  
Tel: +98 811 8218541  
Fax: +98 811 2561515  
E-mail: drsaremi.shoulder@yahoo.com

Received: October 2015

Accepted: November 2015