

Study of Median Palmar Cutaneous Nerve Involvement in a Patient with Wrist Ganglion

Seyed Mansoor Rayegani¹, Elham Loni¹, Leyla Sedighipour^{1*}

¹Physical Medicine and Rehabilitation research center, Shohada Hospital, Shahid Beheshti University of Medical Sciences, Tehran, Iran.

ABSTRACT

Background: Few reports represent palmar cutaneous nerve neuropathy in the wrist due to a ganglion cyst.

Case Presentation: A 25-year-old female was presented with a mass at volar side of the wrist and hypoesthesia at the base of thenar eminence. At ultrasonographic examination, a simple cyst was detected. Sensory response of palmar cutaneous branch of median nerve was absent at the affected side.

Treatment: Ultrasound guided drainage of the cyst was performed. At 3 months follow up examination, the patient was symptom-free.

Learned Lessons: This case was rare among cases involving palmar cutaneous branch of median nerve due to the wrist ganglion documented by Nerve Conduction Studies (NCS).

Keywords: hand; innervation; median nerve; pathology; injuries; electrodiagnosis.

AMHSR 2015;13:119-121
www.journals.ajau.ac.ir

BACKGROUND

The ganglion is a benign mucin filled cyst¹. It is the most common soft tissue tumor of the hand. Ganglia develop at dorsal wrist 70% or volar wrist in up to 20% of cases². Frequently, volar wrist ganglia arise from the radioscaphoid or scaphotrapezoid joint, with a smaller percentage emanating from the pisotriquetral joint³. Patients with a wrist ganglion usually complain about a hand mass with a retinacular cyst and slight discomfort upon gripping.^{1,3} Some previous reports suggest that median neuropathy is sporadically caused by ganglion cysts.⁴⁻⁶ Few reports represent palmar cutaneous nerve neuropathy in the wrist due to a ganglion cyst. Here, we describe a case with volar wrist ganglion and palmar cutaneous nerve entrapment.

CASE PRESENTATION

The patient was a 25-year-old female presented with a mass at volar side of the wrist of her dominant hand; appeared 10 days before coming to our center. She mentioned altered sensation at the base of right

thenar eminence since the appearance of the mass. She had no history of hand or neck trauma, also no history other neuromuscular disease. On physical examination, a mass was seen at the 1 cm proximal to distal crease of right wrist. The mass was tensile, mobile and non-tender (Figure 1). In sensory examination, two-point discrimination was normal but patient mentioned hypoesthesia in right thenar region. Compression test and Phalen test for median neuropathy at wrist were negative. Range of motion of neck, manual muscle test, deep tendon reflexes and other neurological examinations were normal. Review of systems and past medical history revealed no pathologic point.

INVESTIGATIONS/DIFFERENTIAL DIAGNOSIS/TREATMENT

Electro diagnostic study including nerve conduction study (NCS) and electromyography were performed at the date of referral. Right hand's median and ulnar nerve conduction studies are depicted in Table 1. NCS of other

nerves were normal compared to left side. Sensory palmar cutaneous branch of right median nerve action potential was absent but it was obtainable in the left side (Figure 2). Electromyography needle examination was normal.

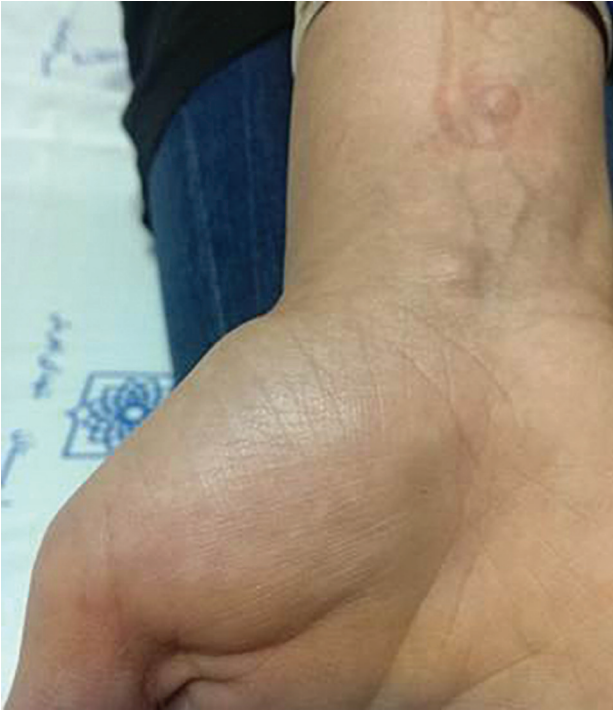

Figure 1. A soft mass at 1 cm proximal to distal crease of right hand.

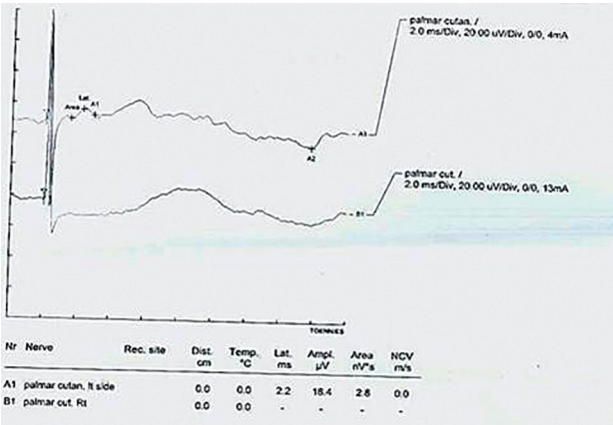


Figure 2. Sensory response of palmar cutaneous branch of right median nerve (absent in right but obtainable in left side).

Table 1. Sensory nerve conduction study (Right side).

Nerve	SNAP Amplitude (μV)	SNAP Latency (ms)	CMAP Amplitude (mV)	CMAP Latency (ms)
Median	31	3	12	3.2
Ulnar	25	2.9	18	3

Abbreviations: CMAP, compound muscle action potential; SNAP, sensory nerve action potential.

We, then, investigated cyst by ultrasonography. It was a simple non-septated cyst. Complete ultrasound guided drainage of the cyst was performed. Its content was apple jelly in appearance (Figures 3 and 4)

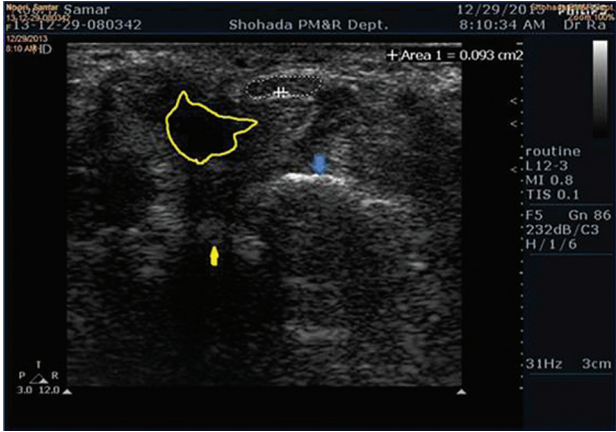


Figure 3. Longitudinal ultrasound image through view of entrance carpal tunnel (proximal to distal crease), demonstrates median nerve (discontinuous line). Lunate is located below median nerve (wide arrow), ganglion cyst was demonstrated (continuous line); palmar cutaneous nerve (thin arrow) is too small to detect.

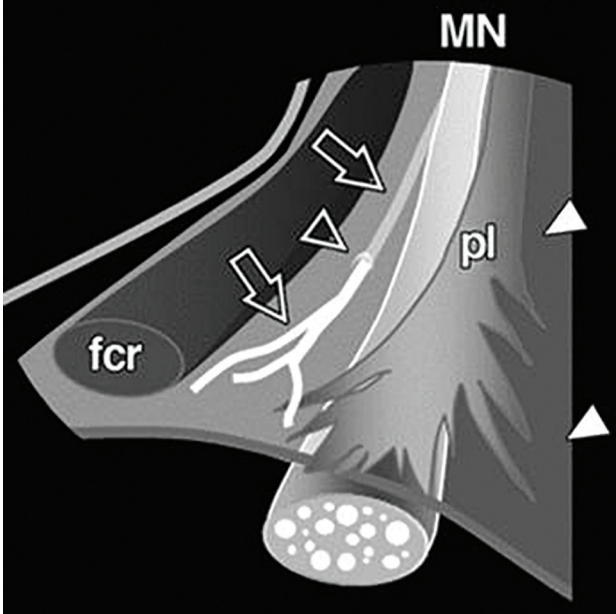


Figure 4. Schematic picture of palmar cutaneous nerve.

OUTCOME

At a 3-month follow up examination, the patient was symptom free and there was no complaint of any mass or hypoesthesia at the base of the thenar area. At ultrasonographic examination there were no remnants of the cyst.

DISCUSSION

We reported a case with isolated palmar cutaneous nerve involvement. Wrist ganglia are common finding in patients with wrist mass.¹⁻³ In literature it was mentioned that ganglia often involve wrist at volar side and less commonly at dorsal side.¹ It can rarely involve nerves innervating the wrist.⁵ In volar ganglia, ulnar and median and their branches can be entrapped.⁵⁻⁹

Some studies reported compression of the ulnar nerve in Guyon's canal due to wrist ganglia.^{7,8} Median nerve involvement due to ganglia was also reported in other studies. Okada and colleagues investigated median nerve neuropathy in the forearm resulting from recurrence of anterior wrist ganglion.⁵ Rizzello and colleagues reported a wrist ganglion compressing motor fibers of median nerve.⁶

However, there are limited reports on entrapment of palmar cutaneous nerve in the literature.^{9,12} In 1993, Al-Qattan and Robertson mentioned that during operation, there was a ganglion compression isolating the palmar cutaneous branch of the median nerve.⁹ Semer and colleagues described isolated neuropathy of the palmar cutaneous branch of the median nerve in a woman with complaint of a mass in volar side of wrist justified by ante brachial fascia on the ulnar aspect of the flexor carpi radialis tendon.¹⁰ In 1987, another case was reported with only numbness in the thenar and a painful mass. Surgery was performed and a ganglion was detected.¹¹ In 2007, Lomax and colleagues reported 2 cases with palmar cutaneous involvement due to neuroma and wrist ganglion by surgical exploration.¹²

This study was the first report of palmar cutaneous nerve entrapment due to wrist ganglion detected by ultrasonography.

LESSONS LEARNED

Simple cyst in the hand may rarely lead to neurologic deficit, hence careful attention and precise investigation is necessary for accurate diagnosis. In these cases, simple cyst aspiration or excision treats patients' symptoms completely.

REFERENCES

1. Gude W, Morelli V. Ganglion cysts of the wrist: pathophysiology, clinical picture, and management. *Curr Rev Musculoskelet Med*. 2008;1:205-11.
2. Lidder S, Ranawat V, Ahrens P. Surgical excision of wrist ganglia; literature review and nine-year retrospective study of recurrence and patient satisfaction. *Orthop Rev (Pavia)*. 2009;1:5.
3. Battaglia TC, Pannunzio ME, Chhabra AB. A Carpometacarpal Joint Ganglion Cyst Causing Median Neuropathy. *Am J Orthop (Belle Mead NJ)*. 2006;35:186-8.
4. Hirano M, Kuroda K, Kunimoto M, Tanohata K, Inoue K. A case of carpal tunnel syndrome caused by a ganglion cyst--diagnosis and follow-up study with magnetic resonance imaging. *Rinsho Shinkeigaku*. 1995;35:80-2. Japanese.
5. Okada K, Miyake J, Kataoka T, Moritomo H, Murase T, Yoshikawa H. Median nerve neuropathy in the forearm due to recurrence of anterior wrist ganglion that originates from the scaphotrapezoid joint: Case Report. *J Brachial Plex Peripher Nerve Inj*. 2012;7:1.
6. Rizzello G, Longo UG, Franceschi F, et al. Compression neuropathy of the motor fibers of the median nerve at wrist level. *J Chin Med Assoc*. 2009;72:268-70.
7. Kwak KW, Kim MS, Chang CH, Kim SH. Ulnar Nerve Compression in Guyon's Canal by Ganglion Cyst. *J Korean Neurosurg Soc*. 2011;49:139-41.
8. Pearce C, Feinberg J, Wolfe SW. Ulnar neuropathy at the wrist. *HSS J*. 2009;5:180-3.
9. Al-Qattan MM, Robertson GA. Entrapment neuropathy of the palmar cutaneous nerve within its tunnel. *J Hand Surg Br*. 1993;18:465-6.
10. Semer N, Crimmins C, Jones NF. Compression neuropathy of the palmar cutaneous branch of the median nerve by the antebrachial fascia. *J Hand Surg Br*. 1996;21:666-7.
11. Buckmiller JF, Rickard TA. Isolated compression neuropathy of the palmar cutaneous branch of the median nerve. *J Hand Surg Am*. 1987;12:97-9.
12. Lomax A, Cheng K, Sianos G. Neuropathy of the palmar cutaneous nerve in association with palpable swellings at the wrist: A report of two cases. *Int J Hand Surg*. 2007;2.
13. Dumitru D, Amato AA, Zwarts MJ. *Electrodiagnostic Medicine*. Philadelphia: Hanley & Belfus; 2002.

Corresponding author:

Leyla Sedighpour

Address: Physical Medicine and Rehabilitation Department, Shohada Hospital, Shahid Beheshti University of Medical Sciences, Tehran, Iran.

Postal Code: 1989934148

Tel: +98 21 22731112

E-mail: lsedighy@yahoo.com

Received at July 2015

Accepted at August 2015