



Previously Diagnosed HIV Infection in Patients with COVID-19 and Advanced HIV Disease Improves Their Survival

Anna Eduardovna Tsygankova ^{1,2,*}, Andrey Nikolaevich Gerasimov ³, Vladimir Petrovich Chulanov ¹, Olga Valerievna Darvina ¹, Karina Turakbaevna Umbetova ¹, Valerii Anatolevich Malov ¹ and Elena Vasilevna Volchkova ¹

¹I.M. Sechenov First Moscow State Medical University (Sechenov University), Moscow, Russian Federation

²Department of Moscow Health, Infectious Clinical Hospital No.2, Moscow, Russian Federation

³Central Research Institute of Epidemiology, Moscow, Russian Federation

*Corresponding author: I.M. Sechenov First Moscow State Medical University (Sechenov University), Moscow, Russian Federation. Email: anna.tsygankova.inf@gmail.com

Received 2023 October 29; Accepted 2023 November 17.

Abstract

Background: Currently, the global HIV epidemic remains ongoing, with a significant number of patients having undiagnosed advanced HIV disease. Providing medical care to patients with both COVID-19 and advanced HIV disease presents specific challenges due to the simultaneous lung damage caused by the SARS-CoV-2 virus and opportunistic pathogens.

Objectives: This study aimed to explain the rationale behind recommending HIV screening for patients with severe COVID-19.

Methods: A single-center retrospective cohort study was conducted using electronic medical records from a specialized hospital in Moscow that focused on coinfection with HIV/COVID-19. Among the 3,563 patients hospitalized in the relevant departments during the study period, 408 patients were included based on the inclusion/exclusion criteria. Out of the 408 patients with both COVID-19 and advanced HIV disease, 132 individuals were newly diagnosed with HIV infection, while 276 individuals had a previously established HIV diagnosis.

Results: The mortality rate in the group of patients with COVID-19 and advanced HIV disease was 31.7% (95% CI, 27.3 - 36.3%). Among patients with COVID-19 and newly diagnosed advanced HIV disease, the mortality rate was 45.5% (95% CI, 37.1 - 54%), while in the group of patients with previously diagnosed advanced HIV disease, the mortality rate was 25% (95% CI, 20.2 - 30.4%). The proportion of individuals with critical CT-4 lung disease in the first group was 32.3% compared to 9.4% in the second group ($P < 0.001$). The median CD4+ count was 20 cells/ μ L in the first group compared with 88 cells/ μ L in the second group ($P < 0.001$).

Conclusions: The presence of pneumocystis pneumonia increased the risk of death by 2.51 times in patients with COVID-19 and newly diagnosed advanced HIV disease. Additionally, Kaposi's sarcoma increased the risk of death by 1.31 times in the same patient group. Furthermore, the detection of HIV infection for the first time during hospitalization due to COVID-19 in the entire study cohort increased the risk of death by 2.21 times.

Keywords: COVID-19, SARS-CoV-2, HIV

1. Background

Based on 2021 data, every day, 4 000 people worldwide become infected with HIV, and every minute, a person dies from AIDS-related causes, resulting in 650 000 deaths annually (1). Eastern Europe and Central Asia are experiencing the fastest-growing HIV epidemic in the world (2). In 2021, 160,000 people were newly infected with HIV in Eastern Europe, with the highest rates recorded in the Russian Federation at 40.2 per 100,000 population. Additionally, 13% of newly diagnosed patients in the

Russian Federation had CD4+ lymphocyte counts of less than 200/ mm^3 (2).

According to the Russian Federal Register of COVID-19 survivors, for the study period from March 1, 2020, to December 31, 2022, a total of 21,798,509 patients with COVID-19 were identified in the Russian Federation. Among them, 393 712 patients died. Additionally, there were 24,444 patients with COVID-19 and HIV coinfection, of which 4960 patients died (3).

2. Objectives

Providing medical care to patients with both COVID-19 and advanced HIV disease presents specific challenges due to the simultaneous lung damage caused by the SARS-CoV-2 virus and opportunistic pathogens (4-6).

3. Methods

During the study period, a total of 3,563 patients were hospitalized at Infectious Diseases Hospital No. 2 in Moscow due to COVID-19. Out of these, 2,962 patients did not meet the inclusion criteria for the study.

Inclusion criteria were a positive PCR test result for SARS-CoV-2 in a sample of nasopharyngeal and oropharyngeal swabs, radiological infiltrates of COVID-19 on chest CT scans, and an established diagnosis of advanced HIV disease according to the WHO definition, which includes a CD4+ lymphocyte count below 200 cells/mm³ or stage 3 or 4 according to the WHO clinical classification in adults and adolescents (7).

A total of 101 patients were excluded from the study due to various exclusion criteria: 38 patients had a tuberculosis diagnosis, 14 patients had severe liver failure, 28 patients had severe renal failure, 17 patients had other serious conditions that could potentially bias the study results, and 4 patients had insufficient time on hospitalization with insufficient data for analysis.

As a result, a total of 408 patients were included in the study. Among these 408 patients, 132 were newly diagnosed with HIV infection, while 276 patients had previously diagnosed advanced HIV disease (Figure 1).

No ethics committee approval was sought due to the retrospective design of the study. Our study was performed in accordance with the ethical standards of the Helsinki Declaration, which was accepted by the World Health Community in 1975 (revised in 2013).

The initial data were collected, adjusted, and systematized using Microsoft Office Excel 2016 spreadsheets. Statistical Package for the Social Sciences (SPSS) version 22 was used for statistical analysis. The significance of distribution function differences was determined using the non-parametric Mann-Whitney and Kolmogorov-Smirnov tests. The applicability of parametric statistical methods was assessed through calculations of skewness and kurtosis coefficients. Statistical significance was defined as $P < 0.05$.

4. Results

The primary outcome of our study was death.

We stratified all patients according to the severity of COVID-19 using the eight-step scale proposed by Beigel et al. (8). The characteristics of patients at the time of inclusion in the study are presented in Table 1.

The mortality rate in the group of patients with COVID-19 and advanced HIV disease (31.6% CI, 27.4 - 36.1%). The mortality rate in the group of patients with COVID-19 and newly diagnosed advanced HIV disease at the time of hospitalization (group 1) was 46.2% (CI, 38.2 - 54.3%), and in the group of patients with COVID-19 and a previously established diagnosis of advanced HIV disease (group 2), it was 24.6% (CI, 20.0 - 29.8%).

The study groups were comparable by gender ($P = 0.451$) and age ($P = 0.67$). Patients from group 1 were admitted to the specialized infectious hospital later than those from group 2 (median 16 and 8 days; $P < 0.001$) and stayed longer (Me 22 and 14 days; $P < 0.001$).

A total of 108 patients (81.8%) with COVID-19 and newly diagnosed advanced HIV disease were hospitalized in a non-specialized infectious center and were subsequently transferred to an infectious hospital No.2 in Moscow.

Patients from group 1 were significantly more likely to require oxygen support: 102/132 (77.3%) patients from group 1 compared to 164/276 (59.4%) patients from group 2 ($P < 0.001$). Patients in group 1 demonstrated more severe respiratory failure, requiring high-flow oxygen in 30/132 (22.7%) patients in group 1 compared to 24/276 (8.4%) patients in group 2 ($P < 0.001$).

However, 77 patients (27.9%) in group 2 kept silent about their HIV status, and they were hospitalized in other medical institutions.

Of these 77 patients who did not choose to disclose their HIV status in the outpatient setting, death occurred in 25 patients (32.5% CI, 23.4 - 42.7%). Fourteen patients (18.2%) were adherent to antiretroviral therapy (ART); the HIV viral load was below detectable levels only in 4 patients (5.2%; Table 2).

Group 1 experienced a more severe course of COVID-19. Among these patients, CT scans of the chest revealed more extensive lung damage, with a notably higher percentage of individuals exhibiting critical CT-4 lesions (33.1% in group 1 compared to 12% in group 2), as illustrated in Figure 2.

Although not all patients from group 2 were adherent to ART and had an undetectable HIV viral load, in general, patients from group 1 demonstrated more severe immunodeficiency (Figure 3).

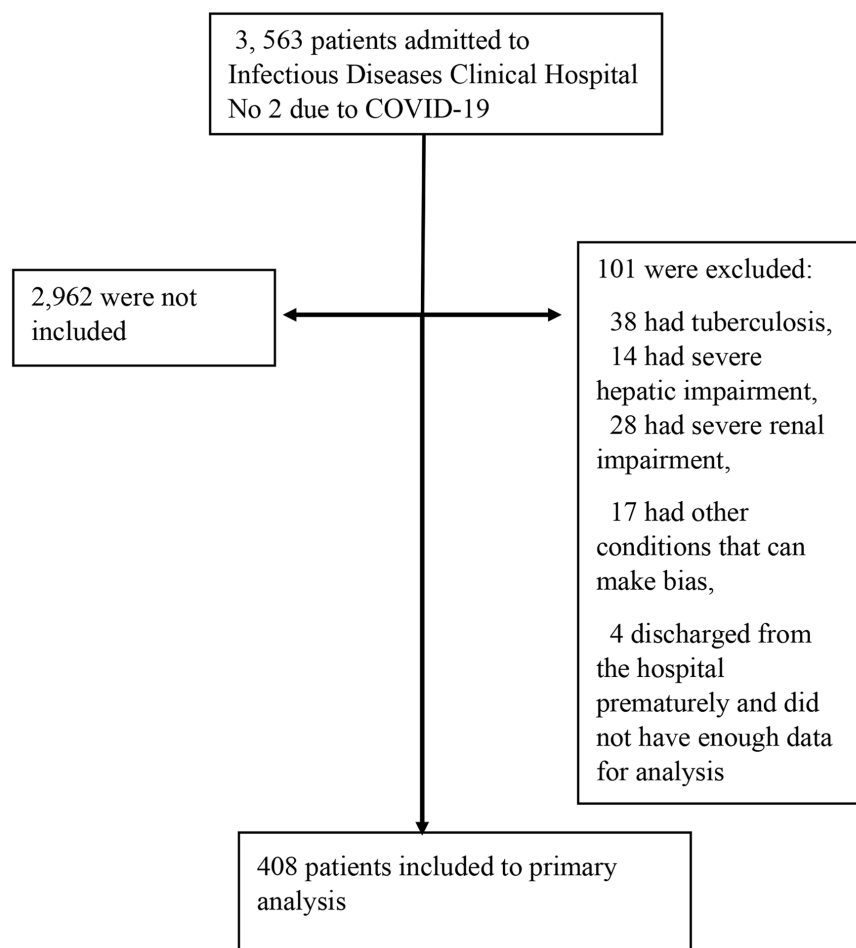


Figure 1. Study design

We additionally selected a subgroup of patients from group 2 who were adherent to ART and had a suppressed HIV viral load. In this subgroup, the mortality rate was (10.7% CI, 4.0 - 23.5%), as shown in Table 3.

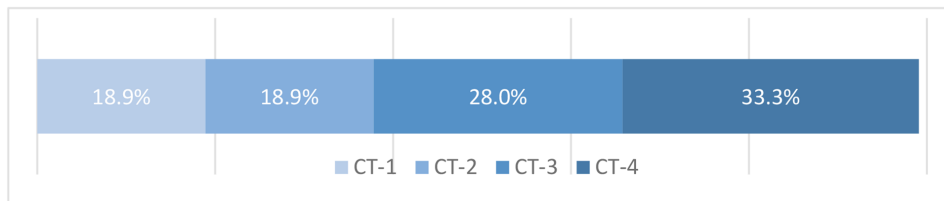
The most significant opportunistic infections and conditions that increased the risk of death in patients with both COVID-19 and newly diagnosed HIV infection were *pneumocystis* pneumonia and a body weight deficiency of more than 10%. No significant differences were observed between groups 1 and 2 in terms of patients with cytomegalovirus (CMV) pneumonitis, bacterial pneumonia, and sepsis, as indicated in Table 4 and Figure 4.

5. Discussion

Dramatic differences in COVID-19 outcomes in the group of patients with COVID-19 and newly diagnosed advanced HIV disease at the time of hospitalization and in the patient group with COVID-19 and previously diagnosed advanced HIV disease can be explained by the fact that there are a number of signs that can mislead clinicians when providing care to patients with COVID-19 and advanced HIV disease.

First, differentiating COVID-19 pneumonia from other lung infections can be very difficult, especially from other viral or atypical pneumonia (9). The spectrum of HIV-associated opportunistic pneumonia is wide and includes bacterial, mycobacterial, fungal, viral, and parasitic pneumonia (10). In patients with immunodeficiency due to HIV infection and COVID-19, it

Group of patients with COVID-19 and newly diagnosed advanced HIV disease



Group of patients with COVID-19 and previously diagnosed advanced HIV disease

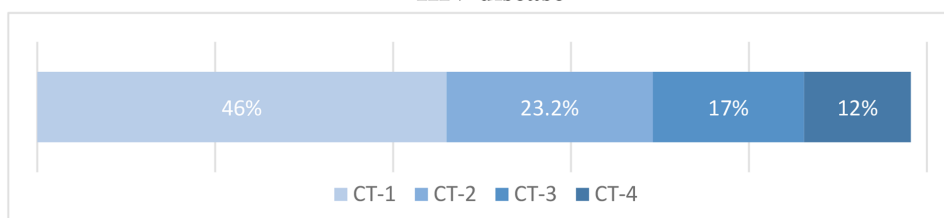
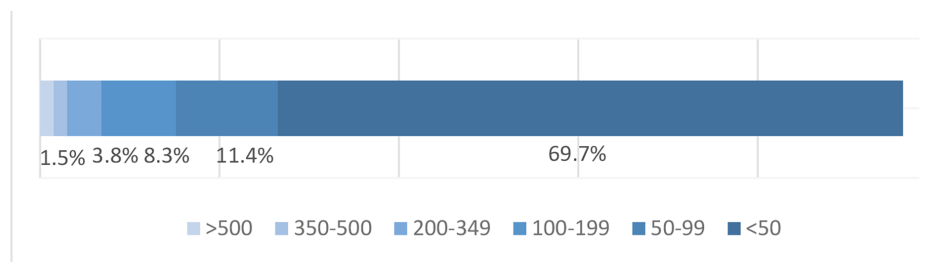


Figure 2. Comparison of the percentage of lung tissue involvement on chest CT scans in patients with COVID-19 and newly diagnosed advanced HIV disease and in the group of patients with previously diagnosed advanced HIV disease.

Group of patients with COVID-19 and newly diagnosed advanced HIV disease



Group of patients with COVID-19 and previously diagnosed advanced HIV disease

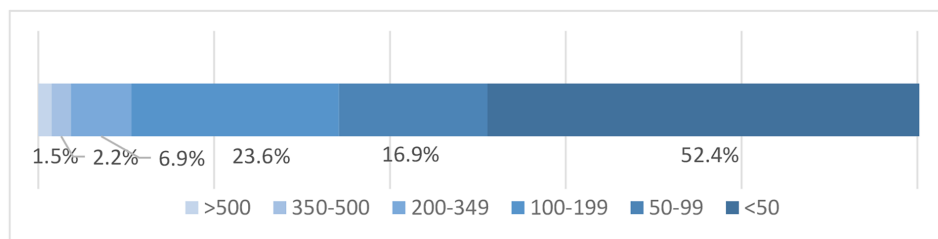


Figure 3. Comparison of CD4+ cell levels in patients with COVID-19 and newly diagnosed advanced HIV disease and in the group of patients with previously diagnosed advanced HIV disease.

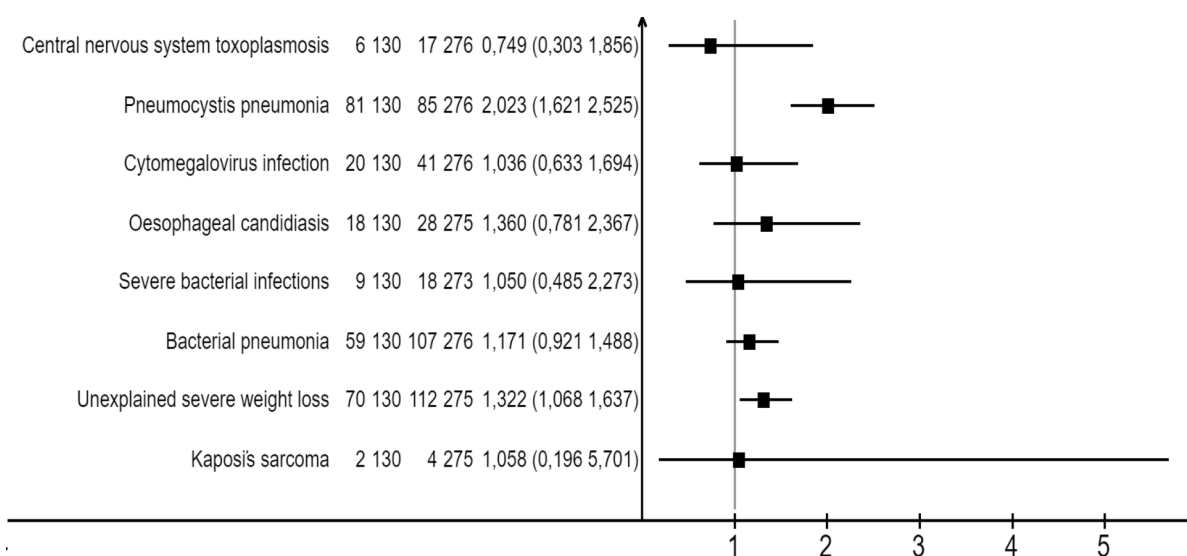


Figure 4. Factors affecting the risk of death in patients with COVID-19 and newly diagnosed advanced HIV disease

is most often necessary to differentiate lung damage from *Pneumocystis* pneumonia, cytomegalovirus pneumonitis, fungal infections, and bacterial pneumonia due to the similarity of the CT image (11).

Pneumonia, which is caused by *Pneumocystis jirovecii*, is characterized by long-term increases in shortness of breath (for weeks or months), fever, and dry cough. *Pneumocystis* pneumonia is often combined with oropharyngeal candidiasis (12, 13). During a CT examination, the following signs should be taken into account: A “ground glass” pattern, the affected areas are located more often in the root of the lung and the middle zone, thickening of the interlobular septa, which, in combination with ground glass type consolidations, can form a cobblestone pattern pavement (11, 14-19). Air cysts, areas of consolidation, focal compaction, and a complication of *pneumocystis* pneumonia-spontaneous pneumothorax can also form (14-19). To confirm the diagnosis, the PCR testing of sputum and bronchoalveolar lavage should be used if the patient’s condition is stable (12).

Isolated lung damage during CMV infection develops only with severe immunodeficiency (CD4 + below 50 cells/mm³) (20); however, combined damage with other opportunistic infections can occur with a higher immune status. Clinically, CMV pneumonitis is indistinguishable from *pneumocystis* pneumonia; however, one should remember the possible multiple organ damage

during CMV infection: In addition to pneumonitis, the development of retinitis, encephalitis, ulcerative colitis, esophagitis, pancreatitis, and polyneuropathy is possible (21). The CT scan of the lungs with CMV pneumonitis is similar to the lesions with *pneumocystis* pneumonia and can be combined; however, there are a number of differences: Ground glass lesions with cytomegalovirus infection appear in the peripheral parts of the lower lobes of the lungs and gradually spread to the roots, and with *pneumocystis* pneumonia, lesions spread from the roots to the periphery “like the wings of a butterfly” (10, 20). The small focal consolidation characteristics of CMV infection are also relatively uncommon in pneumocystis pneumonia (PCP) (10), as it is a pleural effusion (22). The diagnosis of CMV infection of target organs is usually made based on the clinical picture and, if possible, the presence of the virus in tissues. Histological examination reveals cytomegaly and intracellular inclusions, surrounded by a clear halo in the form of an “owl’s eye” (23). The pp65 antigen test is highly sensitive but cannot be used in patients with leukopenia because this test detects antigens in neutrophils (24). A combination of clinical manifestations, a significant decrease in CD4+ cells per mm³, CT imaging, and PCR analysis of blood, sputum, and bronchoalveolar lavage can also provide valuable information.

Aspergillosis is extremely rare, even in patients with HIV infection (25), but the widespread use of

Table 2. The Characteristics of Patients with COVID-19 and Previously Known Advanced HIV Disease Who Did Not Choose to Disclose Their HIV Status^a

Index	Patients with COVID-19 and Previously Known Advanced HIV Disease Who Did Not Choose to Disclose Their HIV Status (N = 77)
Day of COVID-19 at the time of hospitalization median (min-max)	13 (1-130)
Vaccination against COVID-19	9.75 (11.7)
Years passed since the diagnosis of HIV infection, median (min-max)	
Adherent to ART	14.77 (18.2)
Suppressed HIV viral load	4.48 (5.2)
CD 4+ > 500, cells/ μ L	0.73 (0)
CD 4+ 350 - 500, cells/ μ L	0.73 (0)
CD 4+ 200 - 349, cells/ μ L	1.73 (1.3)
CD 4+ 100 - 199, cells/ μ L	16.73 (21.9)
CD 4+ 50 - 99, cells/ μ L	9.73 (12.3)
CD 4+ < 50, cells/ μ L	47.73 (61)
Immunoregulatory index within reference values (1.20 - 2.50)	1.73 (1.3)
Opportunistic infections and conditions	
Toxoplasmosis	3.77 (3.9)
Pneumocystis pneumonia	30.77 (39)
Manifest CMV infection with lung involvement	22.77 (28.6)
Oropharyngeal candidiasis	41.77 (53.2)
Candidiasis of the gastrointestinal tract, respiratory organs, genitourinary system	5.77 (6.5)
Kaposi's sarcoma	1.77 (1.3)
Shingles	3.77 (3.9)
Encephalitis	13.77 (16.9)
Cryptococcosis	1.77 (1.3)
Cancer	3.77 (3.9)
Lymphoproliferative disease	1.77 (1.3)
Breast cancer	0.34 (0)
Cancer of the vulva	1.34 (2.9)
Kidney cancer	1.77 (1.3)
Body mass index below 10%	30.77 (39.0)
Sepsis	5.77 (6.5)
Bacterial pneumonia	36.77 (46.8)
Fungal pneumonia	16.77 (20.8)
Urinary tract infection	5.77 (6.5)
Associated chronic infectious agents	
Chronic viral hepatitis C	23.76 (29.9)
Chronic viral hepatitis C treated	1.77 (1.3)
Chronic viral hepatitis B	2.77 (2.6)
Traditional risk factors for severe COVID-19	
Diabetes	0.77 (0)
Obesity	2.77 (2.6)
Arterial hypertension	4.77 (5.2)
Chronic kidney disease	3.77 (3.9)
Gout	0.77 (0)

Abbreviations: ECMO, extracorporeal membrane oxygenation; CMV, cytomegalovirus.

^a Values are expressed as n/No. (%) unless otherwise indicated.

corticosteroids for COVID-19 has led to an increased incidence of Aspergillosis in the general population (26). Risk factors for aspergillosis include neutropenia (absolute neutrophil count less than 1,000) and a history of corticosteroid use (24, 25). Clinical manifestations may vary depending on the form but are generally not specific: Fever, cough, and shortness of breath. Hemoptysis can

occur when the cavity is localized in the upper lobes of the lungs or in the obstructive form of bronchopulmonary aspergillosis (25-29). Typical pulmonary CT findings include multiple poorly defined peripheral small lesions, predominantly in the upper lobes of the lungs, which gradually coalesce into larger masses or areas of lobular to diffuse consolidation. These lesions consist of a hemorrhagic component and post-infarction lung tissue. When reabsorption of necrotic tissue begins, this is manifested by the retraction of the infarct zone, and air fills the space between them - the 'air crescent sign' manifests as the presence of a crescent-shaped air pocket surrounding the soft tissue component of the pathological cavity. Additionally, the 'Monod sign' may be observed, wherein the Aspergillus-formed ball within the cavity shifts when the patient's body position changes during a CT examination (10, 11, 16).

The clinical picture of community-acquired pneumonia does not differ from that of patients without HIV, but there is a tendency for rapid progression (30). Typical CT findings include unilateral focal consolidation. Other CT findings include cavity formation, pleural effusion, and lymphadenopathy. Ground glass changes may be present very early in the disease (11). Pleural empyema may be present in pneumonia caused by *Staphylococcus aureus* (11, 30).

Second, lymphopenia of COVID-19 is also present in HIV infection, especially in the later stages (31). Acute SARS-CoV-2 infection is associated with lymphopenia in approximately 80% of patients (32). This may be due to the production of excessive amounts of pro-inflammatory cytokines due to COVID-19 infection, which induces lymphocyte apoptosis (33-35). There is also evidence that during severe COVID-19, blood lactate levels increase, and this may suppress lymphocyte production (36). As for HIV infection, during its natural course, during the acute phase, there is a sharp decrease in CD4+T lymphocytes, and when infected CD4+T lymphocytes are completely destroyed, they release more copies of HIV into the bloodstream (37). These new copies of the virus find and attack more CD4 cells, and the cycle continues. This results in far fewer HIV-free, functionally active CD4 cells. In the absence of HIV suppression by ART, the lymphocyte population becomes depleted over time and is characterized by a low CD4/CD8 ratio (38).

Third, in patients with severe immunodeficiency, SARS-CoV-2 viral shedding persists for an extremely long time (39, 40) and, having a confirmed diagnosis in hand, the practitioner may not continue the diagnostic search in

Table 4. Factors Affecting the Risk of Death in Patients with COVID-19 and Newly Diagnosed Advanced HIV Disease

Patient Status	N	n	Mortality Rate (%)	Relative Risk	P-Value
Central nervous system toxoplasmosis				0.75	0.354
Newly diagnosed advanced HIV disease	130	6	4.6		
Previously diagnosed advanced HIV disease	276	17	6.2		
Pneumocystis pneumonia^a				2.02	< 0.001
Newly diagnosed advanced HIV disease	130	81	62.3		
Previously diagnosed advanced HIV disease	276	85	30.8		
Cytomegalovirus infection with lung involvement^b				1.04	0.499
Newly diagnosed advanced HIV disease	130	20	15.4		
Previously diagnosed advanced HIV disease	276	41	14.9		
Oesophageal candidiasis (or candidiasis of the trachea, bronchi, or lungs)				1.36	0.179
Newly diagnosed advanced HIV disease	130	18	13.8		
Previously diagnosed advanced HIV disease	275	28	10.2		
Severe bacterial infections (bacteremia)				1.05	0.527
Newly diagnosed advanced HIV disease	130	9	6.9		
Previously diagnosed advanced HIV disease	273	18	6.6		
Bacterial pneumonia				1.17	0.124
Newly diagnosed advanced HIV disease	130	59	45.4		
Previously diagnosed advanced HIV disease	276	107	38.8		
Unexplained severe weight loss (> 10% of presumed or measured body weight)				1.32	0.009
Newly diagnosed advanced HIV disease	130	70	53.8		
Previously diagnosed advanced HIV disease	275	112	40.7		
Kaposi's sarcoma				1.06	0.636
Newly diagnosed advanced HIV disease	130	2	1.5		
Previously diagnosed advanced HIV disease	275	4	1.5		

^a *Pneumocystis pneumonia* (PCP) was confirmed by specific PCP chest CT infiltrates and a positive PCR reaction for *Pneumocystis jirovecii* in sputum or a bronchoalveolar lavage.

^b Cytomegalovirus (CMV) pneumonitis was confirmed by specific CMV chest CT infiltrates and a qRT-PCR for CMV in a bronchoalveolar lavage more than 10,000 copies (additional criteria: qRT-PCR in plasma more than 100,000 copies and/or positive RT-PCR in sputum).

the area of concomitant infections, which may determine the severity of the patient's condition.

5.1. Conclusions

The similarity of CT picture, lymphopenia, and prolonged viral shedding of SARS-CoV-2 may mislead doctors who treat patients with COVID-19. We recommend HIV testing in patients with severe COVID-19 to determine appropriate management because mortality in the patient group with COVID-19 and newly diagnosed advanced HIV disease at the time of hospitalization was extremely high and amounted to 46.2% (CI, 38.2 - 54.3%). The presence of this factor in the overall study cohort of patients increased the risk of death by 2.21 times.

Footnotes

Authors' Contribution: V. C.: Development of study design; A. G.: Development of study design, statistical analysis of data, writing the article; A.T.: Processing of archival medical histories, selection and analysis of literary sources, statistical analysis of obtained data, writing the article; K. U. and O. D.: Selection and analysis of literary sources. E. V. and V. M.: Proofreading of the article, edits, and approval of the manuscript for peer review.

Conflict of Interests: We have no conflicts of interest to disclose.

Funding/Support: The authors received no financial support for the research, authorship, and/or publication of this article.

References

1. Full report- In Danger: UNAIDS Global AIDS Update 2022. UNAIDS; 2022, [cited 2023 Jun 13]. Available from: <https://www.unaids.org/en/resources/documents/2022/in-danger-global-aids-update>.
2. HIV/AIDS surveillance in Europe 2022 (2021 data). European Centre for Disease Prevention and Control; 2023, [cited 2023 Jun 12]. Available from: <https://www.ecdc.europa.eu/en/publications-data/hiv-aids-joint-report-surveillance-2021-data>.
3. Operational data. 2023, [cited 2023 Jul 03]. Available from: <https://xn--80aesfpebagmflbc0a.xn--ptai/information/>.
4. Basoulis D, Mastrogianni E, Voutsinas PM, Psychogiou M. HIV and COVID-19 Co-Infection: Epidemiology, Clinical Characteristics, and Treatment. *Viruses*. 2023;**15**(2). [PubMed ID: 36851791]. [PubMed Central ID: PMC9962407]. <https://doi.org/10.3390/v15020577>.
5. Mang S, Kaddu-Mulindwa D, Metz C, Becker A, Seiler F, Smola S, et al. Pneumocystis jirovecii Pneumonia and Severe Acute Respiratory Syndrome Coronavirus 2 Coinfection in a Patient With Newly Diagnosed HIV-1 Infection. *Clin Infect Dis*. 2021;**72**(8):1487-9. [PubMed ID: 32607564]. [PubMed Central ID: PMC7337649]. <https://doi.org/10.1093/cid/ciaa906>.
6. Merchant EA, Flint K, Barouch DH, Blair BM. Co-infection with coronavirus disease 2019, previously undiagnosed human immunodeficiency virus, Pneumocystis jirovecii pneumonia and cytomegalovirus pneumonitis, with possible immune reconstitution inflammatory syndrome. *IDCases*. 2021;**24**. e01153. [PubMed ID: 33977081]. [PubMed Central ID: PMC8103711]. <https://doi.org/10.1016/j.idcr.2021.e01153>.
7. WHO case definitions of HIV for surveillance and revised clinical staging and immunological classification of HIV-related disease in adults and children. World Health Organization; 2007.
8. Beigel JH, Tomashek KM, Dodd LE, Mehta AK, Zingman BS, Kalil AC, et al. Remdesivir for the Treatment of Covid-19 - Final Report. *N Engl J Med*. 2020;**383**(19):1813-26. [PubMed ID: 32445440]. [PubMed Central ID: PMC7262788]. <https://doi.org/10.1056/NEJMoa2007764>.
9. Cozzi D, Cavigli E, Moroni C, Smorchkova O, Zantonelli G, Pradella S, et al. Ground-glass opacity (GGO): a review of the differential diagnosis in the era of COVID-19. *Jpn J Radiol*. 2021;**39**(8):721-32. [PubMed ID: 33900542]. [PubMed Central ID: PMC8071755]. <https://doi.org/10.1007/s11604-021-01120-w>.
10. Huang L, Crothers K. HIV-associated opportunistic pneumonias. *Respirology*. 2009;**14**(4):474-85. [PubMed ID: 19645867]. [PubMed Central ID: PMC2835537]. <https://doi.org/10.1111/j.1440-1843.2009.01534.x>.
11. Abuladze LR, Blokhin IA, Gonchar AP, Suchilova MM, Vladzimirskyy AV, Gombolevskiy VA, et al. CT imaging of HIV-associated pulmonary disorders in COVID-19 pandemic. *Clin Imaging*. 2023;**95**:97-106. [PubMed ID: 36706642]. [PubMed Central ID: PMC9846904]. <https://doi.org/10.1016/j.clinimag.2023.01.006>.
12. Siegel M, Masur H, Kovacs J. Pneumocystis jirovecii Pneumonia in Human Immunodeficiency Virus Infection. *Semin Respir Crit Care Med*. 2016;**37**(2):243-56. [PubMed ID: 26974301]. <https://doi.org/10.1055/s-0036-1579556>.
13. Selwyn PA, Pumerantz AS, Durante A, Alcabes PG, Gourevitch MN, Boiselle PM, et al. Clinical predictors of Pneumocystis carinii pneumonia, bacterial pneumonia and tuberculosis in HIV-infected patients. *AIDS*. 1998;**12**(8):885-93. [PubMed ID: 9631142]. <https://doi.org/10.1097/00002030-199808000-00011>.
14. Acar J. Pneumocystis jirovecii and Cytomegalovirus Co-Infection in AIDS Patients. *J Med Cases*. 2013;**6**(4):402-6. <https://doi.org/10.4021/jmci249w>.
15. Averyanov AV, Sotnikova AG, Lesnyak VN. Pneumocystis pneumonia mimicking COVID-19. *J Clin Pract*. 2020;**11**(2):87-92.
16. Li H. *Radiology of Infectious Diseases: Volume 1*. SpringerLink; 2015.
17. De Castro N, Scemla A, Gallien S, Molina JM. [Pneumocystis jirovecii pneumonia in HIV-infected patients]. *Rev Mal Respir*. 2012;**29**(6):793-802. [PubMed ID: 22742466]. <https://doi.org/10.1016/j.rmr.2011.10.975>.
18. Kanne JP, Yandow DR, Meyer CA. Pneumocystis jirovecii pneumonia: high-resolution CT findings in patients with and without HIV infection. *AJR Am J Roentgenol*. 2012;**198**(6):W555-61. [PubMed ID: 22623570]. <https://doi.org/10.2214/AJR.11.7329>.
19. Thomas CJ, Limper AH. Pneumocystis pneumonia. *N Engl J Med*. 2004;**350**(24):2487-98. [PubMed ID: 15190141]. <https://doi.org/10.1056/NEJMra032588>.
20. Salomon N, Perlman DC. Cytomegalovirus pneumonia. *Semin Respir Infect*. 1999;**14**(4):353-8. [PubMed ID: 10638515].
21. Munshi A, Almarhabi H, Mujalled MK, Alturkistani F, Althaqafi A. Simultaneous Occurrence of Cytomegalovirus Colitis and Retinitis as the Initial Presentation of Human Immunodeficiency Virus Infection in a Patient With Zero CD4 Count. *Cureus*. 2022;**14**(2). <https://doi.org/10.7759/cureus.22455>.
22. Salomon N, Gomez T, Perlman DC, Laya L, Eber C, Mildvan D. Clinical features and outcomes of HIV-related cytomegalovirus pneumonia. *AIDS*. 1997;**11**(3):319-24. [PubMed ID: 9147423]. <https://doi.org/10.1097/00002030-199703110-00009>.
23. *Guidelines for the Prevention and Treatment of Opportunistic Infections in Adults and Adolescents with HIV*. Clinical Info; 2023, [cited 2023 Jun 22]. Available from: <https://clinicalinfo.hiv.gov/en/guidelines/hiv-clinical-guidelines-adult-and-adolescent-opportunistic-infections/cytomegalovirus>.
24. Fox EF, Smith NA, Rice P, Dunn H, Peters BS. Cytomegalovirus pp65 antigenaemia as an indicator of end-organ disease in AIDS. *Int J STD AIDS*. 1998;**9**(9):545-7. [PubMed ID: 9764940]. <https://doi.org/10.1258/0956462981922809>.
25. Holding KJ, Dworkin MS, Wan PC, Hanson DL, Klevens RM, Jones JL, et al. Aspergillosis among people infected with human immunodeficiency virus: incidence and survival. Adult and Adolescent Spectrum of HIV Disease Project. *Clin Infect Dis*. 2000;**31**(5):1253-7. [PubMed ID: 11073760]. <https://doi.org/10.1086/317452>.
26. Salmanton-Garcia J, Sprute R, Stemler J, Bartoletti M, Dupont D, Valerio M, et al. COVID-19-Associated Pulmonary Aspergillosis, March-August 2020. *Emerg Infect Dis*. 2021;**27**(4):1077-86. [PubMed ID: 33539721]. [PubMed Central ID: PMC8007287]. <https://doi.org/10.3201/eid2704.204895>.
27. *Aspergillosis in AIDS*. Aspergillus and Aspergillosis; [cited 2023 Jun 14]. Available from: https://www.aspergillus.org.uk/new_treatment/aspergillosis-in-aids/.
28. Kaur R, Mehra B, Dhakad MS, Goyal R, Dewan R. Pulmonary aspergillosis as opportunistic mycoses in a cohort of human immunodeficiency virus-infected patients: Report from a tertiary care hospital in North India. *Int J Health Sci*. 2017;**11**(2):45. [PubMed Central ID: PMC5426406].
29. Miller WJ, Sais GJ, Frank I, Geffer WB, Aronchick JM, Miller WT. Pulmonary aspergillosis in patients with AIDS. Clinical and radiographic correlations. *Chest*. 1994;**105**(1):37-44. [PubMed ID: 8275779]. <https://doi.org/10.1378/chest.105.1.37>.
30. Waite S, Jeudy J, White CS. Acute lung infections in normal and immunocompromised hosts. *Radiol Clin North Am*. 2006;**44**(2):295-315. ix. [PubMed ID: 16500210]. [PubMed Central ID: PMC7119122]. <https://doi.org/10.1016/j.rcl.2005.10.009>.
31. Peng X, Ouyang J, Isnard S, Lin J, Fombuena B, Zhu B, et al. Sharing CD4+ T Cell Loss: When COVID-19 and HIV Collide on Immune System.

- Front Immunol.* 2020;**11**:596631. [PubMed ID: 33384690]. [PubMed Central ID: PMC7770166]. <https://doi.org/10.3389/fimmu.2020.596631>.
32. Zhou Y, Zhang Z, Tian J, Xiong S. Risk factors associated with disease progression in a cohort of patients infected with the 2019 novel coronavirus. *Ann Palliat Med.* 2020;**9**(2):428–36. [PubMed ID: 32233642]. <https://doi.org/10.21037/apm.2020.03.26>.
 33. Wang X, Liu Z, Lu L, Jiang S. The putative mechanism of lymphopenia in COVID-19 patients. *J Mol Cell Biol.* 2022;**14**(5). [PubMed ID: 35641108]. [PubMed Central ID: PMC9412754]. <https://doi.org/10.1093/jmcb/mjac034>.
 34. Shen X, Geng R, Li Q, Chen Y, Li S, Wang Q, et al. ACE2-independent infection of T lymphocytes by SARS-CoV-2. *Sign Trans Target Ther.* 2022;**7**(1):83. <https://doi.org/10.1038/s41392-022-00919-x>.
 35. Fathi N, Rezaei N. Lymphopenia in COVID-19: Therapeutic opportunities. *Cell Biol Int.* 2020;**44**(9):1792–7. [PubMed ID: 32458561]. [PubMed Central ID: PMC7283672]. <https://doi.org/10.1002/cbin.11403>.
 36. Tan L, Wang Q, Zhang D, Ding J, Huang Q, Tang YQ, et al. Lymphopenia predicts disease severity of COVID-19: a descriptive and predictive study. *Signal Transduct Target Ther.* 2020;**5**(1):33. [PubMed ID: 32296069]. [PubMed Central ID: PMC7100419]. <https://doi.org/10.1038/s41392-020-0148-4>.
 37. Vidya Vijayan KK, Karthigeyan KP, Tripathi SP, Hanna LE. Pathophysiology of CD4+ T-Cell Depletion in HIV-1 and HIV-2 Infections. *Front Immunol.* 2017;**8**:580. [PubMed ID: 28588579]. [PubMed Central ID: PMC5440548]. <https://doi.org/10.3389/fimmu.2017.00580>.
 38. Sereti I, Krebs SJ, Phanuphak N, Fletcher JL, Slike B, Pinyakorn S, et al. Persistent, Albeit Reduced, Chronic Inflammation in Persons Starting Antiretroviral Therapy in Acute HIV Infection. *Clin Infect Dis.* 2017;**64**(2):124–31. [PubMed ID: 27737952]. [PubMed Central ID: PMC5215214]. <https://doi.org/10.1093/cid/ciw683>.
 39. Leung WF, Chorlton S, Tyson J, Al-Rawahi GN, Jassem AN, Prystajek N, et al. COVID-19 in an immunocompromised host: persistent shedding of viable SARS-CoV-2 and emergence of multiple mutations: a case report. *Int J Infect Dis.* 2022;**114**:178–82. [PubMed ID: 34757008]. [PubMed Central ID: PMC8553657]. <https://doi.org/10.1016/j.ijid.2021.10.045>.
 40. Meiring S, Tempia S, Bhiman JN, Buys A, Kleynhans J, Makhasi M, et al. Prolonged Shedding of Severe acute respiratory syndrome coronavirus 2 (SARS-CoV-2) at High Viral Loads Among Hospitalized Immunocompromised Persons Living With Human Immunodeficiency Virus (HIV), South Africa. *Clin Infect Dis.* 2022;**75**(1):e144–56. [PubMed ID: 35134129]. [PubMed Central ID: PMC8903337]. <https://doi.org/10.1093/cid/ciac077>.

Table 1. Baseline Patient Characteristics ^a

Index	Group 1 (N = 132)	Group 2 (N = 276)	P-Value ^b
Age; median (min - max) (y)	43 (23 - 76)	43 (21 - 71)	0.207,0.607
Gender (female)	46.132 (34.8)	93.276 (33.7)	0.451
Vaccination against COVID-19	24.138 (17.4)	33.359 (9.2)	
Day from onset of COVID-19 symptoms at the time of hospitalization; median (min - max)	16 (1 - 171)	9 (1 - 130)	0.017
Score On Ordinal Scale^c			
Hospitalized, not requiring supplemental oxygen, requiring ongoing medical care (degree of physical impairment = 4)	49.132 (37.1)	165.276 (59.8)	0.001
Hospitalized, requiring supplemental oxygen (degree of physical impairment = 5)	83.132 (62.9)	111.276 (40.2)	< 0.001
Hospitalized, receiving noninvasive ventilation or high-flow oxygen devices (degree of physical impairment = 6)	30.132 (22.7)	24.276 (8.4)	< 0.001
Hospitalized, receiving invasive mechanical ventilation or ECMO (degree of physical impairment = 7)	11.132 (8.3)	12.276 (4.3)	< 0.001
Admission to non-HIV medical center	108.132 (81.8)	77.276 (27.9)	< 0.001
Prescription of immunobiological monoclonal antibodies	37.126 (29.4)	22.268 (8.2)	< 0.001
Intensive care unit admission	28.132 (21.2)	25.275 (9.1)	0.001
Oxygen support	102.132 (77.3)	164.276 (59.4)	< 0.001
Low flow oxygenation	83.132 (62.9)	111.276 (40.2)	< 0.001
High flow oxygenation	30.132 (22.7)	24.276 (8.4)	< 0.001
Mechanical ventilation	11.132 (8.3)	12.276 (4.3)	0.083
Proportion of Lung Tissue Damage According to the Results of Computed Tomography of the Lungs			
CT 1 (up to 25%)	25.131 (18.9)	127.272 (46.0)	< 0.001
CT 2 (up to 50%)	24.131 (18.9)	65.272 (23.2)	0.127
CT 3 (up to 75%)	38.131 (28)	46.272 (17)	0.004
CT 4 (more than 75%)	44.131 (33.3)	33.272 (12)	< 0.001
Laboratory tests			
Lymphocytes (absolute count); less than 1.0×10^9	87.129 (65.9)	152.269 (55.1)	0.024
C-reactive protein; above 10 mg/L	71.128 (55.5)	206.266 (77.4)	< 0.001
Platelets (absolute count); less than 150×10^9	29.130 (22.3)	97.269 (36.1)	0.004
Ferritin; above 600 ng/L	64.84 (76.2)	98.143 (68.5)	0.140
Lactate dehydrogenase; above 460 U/L	77.94 (81.9)	137.185 (74.1)	0.092
D-dimer; above 250 ng/mL	73.111 (65.8)	168.225 (74.7)	0.058
Fibrinogen; above 3.97 g/L	58.124 (46.9)	160.258 (62)	0.003
Immune Status Indicators			
CD 4+ > 500 cells/ μ L	2.123 (1.6)	4.267 (1.5)	0.614
CD 4+ 350 - 500 cells/ μ L	2.123 (1.6)	6.267 (2.2)	0.512
CD 4+ 200 - 349 cells/ μ L	1.123 (0.8)	18.267 (6.9)	0.006
CD 4+ 100 - 199 cells/ μ L	11.123 (8.9)	63.267 (23.6)	< 0.001
CD 4+ 50 - 99 cells/ μ L	15.123 (12.2)	45.267 (16.9)	0.150
CD 4+ < 50 cells/ μ L	92.123 (74.8)	140.267 (52.4)	< 0.001
Immunoregulatory index within reference values (1.20 - 2.50)	1.123 (0.8)	7.267 (2.6)	0.223
HIV viral load less than detectable level	0.88 (0)	29.154 (10.5)	< 0.001
Opportunistic Infections and Other Conditions			
Toxoplasmosis	6.130 (4.6)	17.276 (6.2)	0.354
<i>Pneumocystis pneumonia</i> ^d	81.130 (62.3)	85.276 (30.8)	< 0.001
CMV pneumonitis ^e	66.130 (50.8)	55.275 (20.0)	< 0.001

Continued on next page

Table 1. Baseline Patient Characteristics ^a (Continued)

Oropharyngeal candidiasis	79.130 (60.8)	142.275 (51.6)	0.053
Candidiasis of the gastrointestinal tract, respiratory organs, genitourinary system	18.130 (13.8)	28.275 (10.2)	0.179
Kaposi's sarcoma	2.130 (1.5)	4.275 (1.5)	0.626
Shingles	4.129 (3.1)	3.268 (1.1)	0.159
Encephalitis	14.130 (10.8)	35.273 (12.8)	0.340
Cryptococcosis	2.129 (1.6)	1.272 (0.4)	0.243
Oncological disease	2.129 (1.6)	6.276 (2.2)	0.492
Lymphoproliferative disease	2.129 (1.6)	4.273 (1.5)	0.625
Cancer of the vulva	0.45 (0)	1.91 (1.1)	0.669
Kidney cancer	0.132 (0)	1.276 (0.4)	0.676
Body mass index below 10%	70.130 (53.8)	112.275 (40.7)	0.009
Sepsis	9.130 (6.9)	18.273 (6.6)	0.527
Bacterial pneumonia	59.130 (45.4)	107.276 (38.8)	0.124
Fungal pneumonia	29.130 (22.3)	53.276 (19.2)	0.274
Urinary tract infection	9.130 (6.9)	23.276 (8.3)	0.392
Associated Chronic Infectious Agents			
Chronic viral hepatitis C	27.130 (20.8)	125.275 (45.5)	< 0.001
Chronic viral hepatitis C treated	0.130 (0)	4.276 (1.4)	0.212
Chronic viral hepatitis B	6.130 (4.6)	16.276 (5.8)	0.409
Traditional risk factors for severe COVID-19			
Diabetes	1.130 (0.8)	4.275 (1.5)	0.485
Obesity	1.128 (0.8)	5.276 (1.8)	0.383
Arterial hypertension	10.130 (7.7)	14.275 (5.1)	0.204
Chronic kidney disease	0.130 (0)	7.275 (2.5)	0.065
Gout	0.128 (0)	2.276 (0.7)	0.466

Abbreviations: ECMO, extracorporeal membrane oxygenation; CMV, cytomegalovirus.

^a Values are expressed as n/No. (%) unless otherwise indicated.

^b Differences were considered statistically significant at $P < 0.05$.

^c Scale was proposed by Beigel et al. (8).

^d *Pneumocystis pneumonia* (PCP) was confirmed by specific PCP chest CT infiltrates and a positive PCR reaction for *Pneumocystis jirovecii* in sputum or bronchoalveolar lavage.

^e Cytomegalovirus (CMV) pneumonitis was confirmed by specific CMV chest CT infiltrates and a qRT-PCR for CMV in a bronchoalveolar lavage more than 10,000 copies (additional criteria: qRT-PCR in plasma more than 100 000 copies and/or positive RT-PCR in sputum).

Table 3. The Characteristics of Patients Who Were Adherent to Antiretroviral Therapy (ART) and Had a Suppressed HIV Viral Load and Died

Variables	Patient 1		Patient 2		Patient 3	
	M	M	M	M	M	M
Gender						
Age	42	56	49	56	49	49
Years have passed since the diagnosis of HIV infection	9	20	5	20	5	5
Years have passed since the beginning of ART	2 months	unknown	unknown	unknown	unknown	unknown
Immune status	CD4 33 cells/ μ L, CD8 453 cells/ μ L, CD4/CD8 0.07	CD4 453 cells/ μ L, CD8 453 cells/ μ L, CD4/CD8 0.07	CD4 151 cells/ μ L, CD8 153 cells/ μ L, CD4/CD8 0.98	CD4 151 cells/ μ L, CD8 153 cells/ μ L, CD4/CD8 0.98	CD4 301 cells/ μ L, CD8 419 cells/ μ L CD4/CD8 0.71	CD4 301 cells/ μ L, CD8 419 cells/ μ L CD4/CD8 0.71
ART scheme	DRV(600) ^r + 3TC + TDF	DRV(600) ^r + 3TC + TDF	RAL + 3TC + RPV	RAL + 3TC + RPV	EFV + 3TC + TDF	EFV + 3TC + TDF
Opportunistic diseases	Pathological anatomical diagnosis: Bilateral polysegmental pneumonia of mixed etiology (intra-vital detection of Herpes simplex virus 2, Klebsiella pneumoniae, Candida albicans, Candida glabrata DNA in sputum; autopsy tank; examination of lung tissue: Growth of Pseudomonas aeruginosa) with abscess formation. Subacute leptomeningitis (autopsy bacterial examination of cerebrospinal fluid: Growth of Klebsiella pneumoniae; Pseudomonas aeruginosa). Kaposi's sarcoma of the skin on the face, trunk, and extremities with metastases to the base of the tongue, larynx, and lungs. Mycotic erosive and ulcerative esophagitis. Cachexia. Primary complications: Respiratory distress syndrome. Inflammatory syndrome associated with immune system restoration. Necrophrosis. Disseminated intravascular coagulation (DIC) syndrome; Hemorrhages in the conjunctiva, subpleural membrane, and epicardium; splenic involvement; blood clots in the vessels of internal organs and the brain; focal necrosis of the pancreas and adrenal glands. Pseudomembranous enterocolitis with predominant involvement of the large intestine (bacterial study of contents from the small and large intestine: Growth of Candida species was detected, analysis for Clostridium was negative).	Pathological anatomical diagnosis: Bilateral polysegmental pneumonia of mixed etiology (intra-vital detection of Herpes simplex virus 2, Klebsiella pneumoniae, Candida albicans, Candida glabrata DNA in sputum; autopsy tank; examination of lung tissue: Growth of Pseudomonas aeruginosa) with abscess formation. Subacute leptomeningitis (autopsy bacterial examination of cerebrospinal fluid: Growth of Klebsiella pneumoniae; Pseudomonas aeruginosa). Kaposi's sarcoma of the skin on the face, trunk, and extremities with metastases to the base of the tongue, larynx, and lungs. Mycotic erosive and ulcerative esophagitis. Cachexia. Primary complications: Respiratory distress syndrome. Inflammatory syndrome associated with immune system restoration. Necrophrosis. Disseminated intravascular coagulation (DIC) syndrome; Hemorrhages in the conjunctiva, subpleural membrane, and epicardium; splenic involvement; blood clots in the vessels of internal organs and the brain; focal necrosis of the pancreas and adrenal glands. Pseudomembranous enterocolitis with predominant involvement of the large intestine (bacterial study of contents from the small and large intestine: Growth of Candida species was detected, analysis for Clostridium was negative).	Pathological anatomical diagnosis: Bilateral polysegmental pneumonia of mixed etiology (microbiological examination of the lungs during autopsy detected Klebsiella pneumoniae and fungus pseudomycetium was detected histobacterioscopically). Primary complication: Diffuse alveolar damage in the exudative phase. Disseminated intravascular coagulation (DIC) syndrome: Widespread hemorrhages, thrombosis of small vessels in the skin, mucous membranes of the respiratory, digestive, and urinary-genital tracts in the lungs, kidneys, and adrenal glands; hemorrhagic erosion of the stomach, focal necrosis of the adrenal glands and pancreas. Acute renal failure: Proteinuria 1.45 g/L; uremia with creatinine level of 314 μ mol/L and urea level of 29.3 mmol/L. Coexisting conditions: Obesity. Chronic viral hepatitis C. Underlying disease: Chronic mesangiocapillary glomerulonephritis. Renal arterial hypertension with eccentric myocardial hypertrophy (heart weight 360 g, left ventricular wall thickness 1.7 cm, right ventricle 0.3 cm).	Pathological anatomical diagnosis: Bilateral polysegmental pneumonia of mixed etiology (microbiological examination of the lungs during autopsy detected Klebsiella pneumoniae and fungus pseudomycetium was detected histobacterioscopically). Primary complication: Diffuse alveolar damage in the exudative phase. Disseminated intravascular coagulation (DIC) syndrome: Widespread hemorrhages, thrombosis of small vessels in the skin, mucous membranes of the respiratory, digestive, and urinary-genital tracts in the lungs, kidneys, and adrenal glands; hemorrhagic erosion of the stomach, focal necrosis of the adrenal glands and pancreas. Acute renal failure: Proteinuria 1.45 g/L; uremia with creatinine level of 314 μ mol/L and urea level of 29.3 mmol/L. Coexisting conditions: Obesity. Chronic viral hepatitis C. Underlying disease: Chronic mesangiocapillary glomerulonephritis. Renal arterial hypertension with eccentric myocardial hypertrophy (heart weight 360 g, left ventricular wall thickness 1.7 cm, right ventricle 0.3 cm).	Bilateral polysegmental pneumonia of a severe course. Systemic inflammatory response syndrome of infectious origin with organ dysfunction. Severe anemia. History of Kaposi's sarcoma.	Bilateral polysegmental pneumonia of a severe course. Systemic inflammatory response syndrome of infectious origin with organ dysfunction. Severe anemia. History of Kaposi's sarcoma.

Abbreviation: ART, antiretroviral therapy.