

Invasive aspergillosis of pituitary gland in an immunocompetent patient

Davood Yadegarynia^{1*}, Mehrdad Haghghi¹, Farhad Abbasi¹, Sharareh Gholamian¹, Sina Yadegarynia²

¹ Infectious Diseases and Tropical Medicine Research Center, Shahid Beheshti University, M.C., Tehran, Iran

² San Jose state University, USA

ABSTRACT

Background: Invasive aspergillosis is a major cause of morbidity and mortality in immunosuppressed patients. This infection is caused by *Aspergillus*, a hyaline mold, which is the etiologic agent for many different manifestations.

Patient: A 63 year old diabetic housewife woman, living in northern Iran, presented with the history of right eye ptosis after a mild head trauma since about 3 weeks ago. She had positive history of intermittent headache several weeks before ptosis. On physical examination, the patient was afebrile and other vital signs were normal. Brain MRI showed a pituitary mass measuring about 4 cm. Pathological study showed hyphae in favor of aspergillosis. Amphotericin B was started and after 10 days changed to itraconazole.

Conclusion: It is important to consider fungal infection as a differential diagnosis of cerebral lesions even in the immunocompetent hosts. The clinical presentation of cerebral aspergillosis is nonspecific and is characterized by focal neurologic signs, alteration in mental status and headache.

Keywords: *Aspergillosis, Pituitary gland, Itraconazole*
(Iranian Journal of Clinical Infectious Diseases 2008;3(3):163-165).

INTRODUCTION

Invasive aspergillosis is a major cause of morbidity and mortality in immunosuppressed patients. This infection is caused by *Aspergillus*, a hyaline mold, which is the etiologic agent for many different manifestations. Although the infection can occur in apparently normal host, aspergillosis is extremely uncommon in immunocompetent hosts (1).

In recent years *Aspergillus* and aspergillosis have been a major focus of clinical mycology

because the number of patients with this disease has risen dramatically and also because the diagnosis and treatment of this invasive infection has been difficult (2).

CASE PRESENTATION

A 63 year old housewife woman, living in northern Iran, presented with the history of right eye ptosis after a mild head trauma since about 3 weeks ago. She had positive history of intermittent headache, with a good response to analgesics several weeks before ptosis. The patient was a known case of poorly controlled insulin dependent

Received: 19 November 2007 Accepted: 13 April 2008

Reprint or Correspondence: Davood Yadegarynia, MD,
Infectious Diseases and Tropical Medicine Research Center,
Shahid Beheshti University, M.C., Tehran, Iran.

E-mail: yadegarinia@yahoo.com

diabetes mellitus since about 20 years ago. The patient was HIV negative and also no risk factor for immune deficiency was detected.

The patient's left eye was blind due to cataract. During this period the history of focal neurologic signs, left and right extremities weakness, inability to walk or sensory loss was negative.

On physical examination, the patient was afebrile and other vital signs were normal. Mild ptosis of right eye was detected. There was no change in right eye vision during this period. Right eye pupil reflex and extraocular movements of both eyes were normal. There was no sign in favor of facial nerve palsy. Other cranial nerves were normal. There was no neck rigidity. Kernig and Brudzinski signs were negative. Other neurologic examinations were normal. Physical examination of lung, heart, abdomen, and extremities was also normal.

Brain MRI showed a pituitary mass measuring about 4 cm. Differential diagnosis considered in this stage were pituitary adenoma, granulomatous diseases (tuberculosis, fungal infection, etc.) or vascular aneurysm.



Figure 1. The patient several days after surgery

Vascular aneurysm was ruled out by performing a CT-angiography. The mass was excised by trans-sphenoidal surgery. Pathological study showed hyphae in favor of aspergillosis but culture

evaluation was not performed. Amphotericin B was started and after 10 days changed to itraconazole. After surgery, during hospitalization course ptosis gradually improved and headache disappeared. The patient discharged with outpatient follow up program.

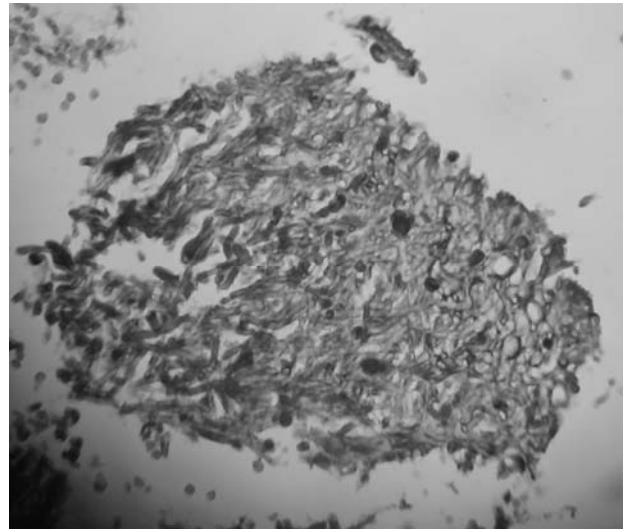


Figure 2. Microscopic view of *Aspergillus* hyphae

DISCUSSION

Cerebral aspergillosis is associated with the highest mortality rate (more than 90%) among invasive aspergillosis syndromes (3). Isolated cerebral aspergillosis can occur in immunocompetent patients or in the setting of injection drug use, in which it may be associated with a slightly better prognosis provided that the diagnosis is made early and surgical drainage or removal is performed (4).

Our patient was presumably immunocompetent and had no related underlying condition other than diabetes and removal surgery of the lesion was performed.

The hyphae of aspergillus is septated with dicutamus mycelium with 45 degree angle and 2.5 to 8 micrometer diameter whereas mucor has wide hyphae (3 to 25 micrometer diameter) with a thick wall(5), so that they can be differentiated easily from each other.

Based on Infectious Diseases Society of America (IDSA) Health Service grading system, a set of research-oriented definitions for invasive fungal infections (including invasive aspergillosis) was developed. Three levels of certainty of invasive aspergillosis were defined: proven, probable, and possible. The definition for proven aspergillosis requires histopathological documentation of infection and a positive result of culture of a specimen from a normally sterile site. The definition of probable aspergillosis requires the fulfillment of criteria within 3 categories: host factors, clinical manifestations (symptoms, signs, and radiological features), and microbiological evidence. Throughout these guidelines, the term "invasive aspergillosis" will assume a diagnostic certainty of proven or probable invasive aspergillosis. With 2 important exceptions, proven or probable infection requires the recovery of an organism. The first exception includes the fairly frequent occurrence of histopathological demonstration of hyphae consistent with *Aspergillus* species in patients with negative culture results (6).

According to this new ranking our patient was treated as a case of invasive aspergillosis without any need to be confirmed by culture or microbiology. Treatment with antifungal agents including itraconazole was started. Itraconazole is more frequently used in immunosuppressed patients who are able to take oral therapy and for use as sequential oral therapy.

It is important to consider fungal infection as a differential diagnosis of cerebral lesions even in the immunocompetent hosts. The clinical presentation of cerebral aspergillosis is nonspecific and is characterized by focal neurologic signs, alteration in mental status and headache (7).

Its appearance in CT scan of the brain is non specific and is similar to that of other infectious cause of brain abscess with ring enhancement of the abscess along with surrounding edema. Confirmation of the diagnosis requires biopsy,

even when therapy is begun promptly. Efficacy of many treatment regimens including amphotericin B is poor particularly in patient with disseminated or central nervous system diseases.

There are few cases of pituitary aspergillosis in literature and almost all of them are presented as case reports.

REFERENCES

1. Clancy CJ, Nguyen MH. Acute community-acquired pneumonia due to *Aspergillus* in presumably immunocompetent hosts: clues for recognition of a rare but fatal disease. *Chest* 1998;114:629-34.
2. Stevens DA, Kan VL, Judson MA, Morrison VA, Dummer S, Denning DW, et al. Practice guidelines for disease caused by *Aspergillus*. *Clin Infect Dis* 2000;30:696-709.
3. Lin SJ, Schranz J, Teutsch SM. Aspergillosis case-fatality rate: systematic review of the literature. *Clin Infect Dis* 2001;32:358-66.
4. Troke PF, Schwartz S, Ruhnke M, Ribaud P, Corey L, Driscoll T, et al. Voriconazole (VRC) therapy (Rx) in 86 patients with CNS aspergillosis (CNSA): a retrospective analysis. Program and abstracts the 43rd Annual ICAAC; September 14-17, 2003; Chicago, Illinois. Abstract M-1755.
5. Neva FA, Brown HW. Basic clinical parasitology. 6th ed. Philadelphia: Appleton and Lange; 1994.
6. Walsh TJ, Anaissie EJ, Denning DW, Herbrecht R, Kontoyannis DP, Marr KA, et al. Treatment of aspergillosis: clinical practice guidelines of the Infectious Diseases Society of America. *Clin Infect Dis* 2008;46:327-60.
7. Patterson TF, Kirkpatrick WR, White M, Hiemenz JW, Wingard JR, Dupont B, et al. Invasive aspergillosis. Disease spectrum, treatment practices, and outcomes. I3 *Aspergillus* Study Group. *Medicine (Baltimore)* 2000;79:250-60.