

A cauliflower-like lesion on back of the hand

Behrooz Barikbin, Zahra Ghoorchiani

Skin Research Center, Shahid Beheshti Medical University, Tehran, Iran

A healthy 35-year-old woman presented with a 2 months history of a cauliflower-like lesion on her right hand with no further lesions elsewhere. She declared that the disease began with one slightly elevated erythematous nodule with some exudate on its surface then grew slowly to form this vegetative plaque without any associated symptoms of itching or pain.

On her physical examination, an erythematous, indurated cauliflower-like vegetative plaque measuring 3×4cm was noted in association with crusted keratotic surface on dorsum of right hand (figure 1). There was no regional lymphadenopathy.

The findings of general physical examination were unremarkable except for the aforementioned skin lesion.

The patient had no constitutional symptoms and no significant past medical history. The lesion had been treated with cephalexin 2gr/daily for 3 weeks but her condition did not improve.

To confirm the diagnosis, a skin biopsy was achieved (figure 2).

Now, what is your diagnosis? (The answer is on page 159)

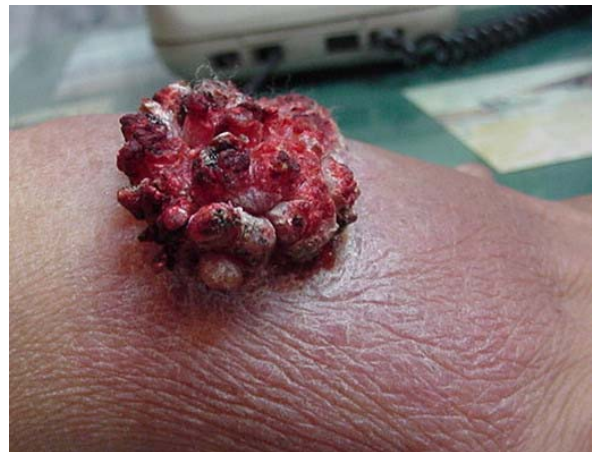

Figure 1. Cauliflower-like lesion on the hand

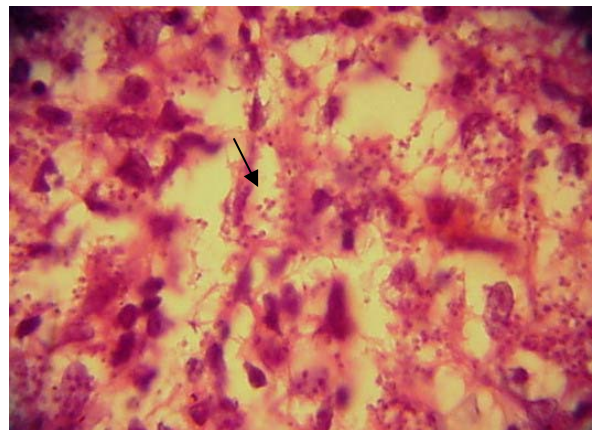


Figure 2. Histopathology of the lesion

Received: 18 May 2007 Accepted: 28 July 2007

Reprint or Correspondence: Behrooz Barikbin, MD.
Skin Research Centre, Loghman-Hakim Hospital, Shahid
Beheshti Medical University.

E-mail: bbarikbin@yahoo.com