

A 22 month-old girl with generalized tonic-colonic seizure

Monireh Kamali^{1*}, Fariba Farnaghi², Gyv Sharifi³, Masoud Mardani¹

¹ Infectious Diseases and Tropical Medicine Research Center, Shahid Beheshti University, M.C., Tehran, Iran

² Department of Pediatrics, Shahid Beheshti University, M.C., Tehran, Iran

³ Department of Neurosurgery, Shahid Beheshti University, M.C., Tehran, Iran

A 22-month-old girl was referred to our hospital from Dasht Moqan (northern part of Iran) with history of seizure since one year ago. Her last episode of seizure was on the day of admission with loss of consciousness, generalized tonic colonic movement of limbs, upward gaze, jaw locking and urinary incontinency similar to previous episodes. She was the second child of a family that has 3 normal children and their first child expired because of prematurity. Her parents did not have familial relationship and any familial history of seizure. She had normal growth and developmental history. Her previous episode of seizure was without fever.

On physical examination the temperature was 37°.5C and pulse was 120/min. There were normal head and neck examination without meningeal signs and increased head circumference. Decreased breathing sound of right lower lung with dullness and increased tactile ferimitus was detected in lung examination. Abdominal and neurologic examinations were within normal range. Laboratory test results included hemoglobin 11.7g/dl, white blood cell 9900 leukocyte/mm³, and platelet 536000/mm³, calcium 9.9mg/dl, sodium 139meq/dl, potassium 4.1meq/dl and glucose 95mg/dl. Tests for liver and thyroid function were within normal range. Erythrocyte

sedimentation rate was 24 mm per hour and C-reactive protein was negative. Stool examination and urine analysis were normal.

Her brain MRI and chest x ray is show in figure 1 and 2.

Now, what is your diagnosis? (The answer is on page 241)

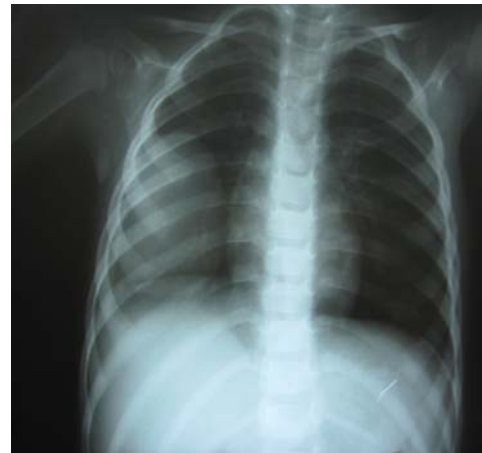

Figure 1. Chest x-ray of the patient.

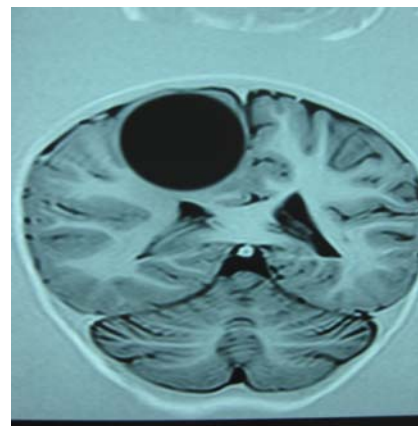


Figure 2. Brain MRI of the patient with generalized tonic-colonic seizure.

Received: 5 July 2009 Accepted: 7 September 2009

Reprint or Correspondence: Monireh Kamali, MD.

Infectious Diseases and Tropical Medicine Research Center, Shahid Beheshti University, M.C., Tehran, Iran.

E-mail: Monireh_kamali1980@yahoo.com