

Case Report

Sternoclavicular Joint Tuberculosis With Cold Abscess

Maliheh Metanat, Roya Alavi-Naini

Abstract

All organ systems may be affected by tuberculosis (TB) but tuberculosis arthritis is responsible for approximately 1% of TB patients. Weight bearing joints such as hips and knees are most commonly affected; whereas involvement of sternoclavicular joint with tuberculosis is a very rare disease. In this case report we present a 63-year old woman with tuberculosis of the sternoclavicular joint. Her chief complaint was left shoulder pain and swelling over the left sternoclavicular region. It was diagnosed clinically and confirmed by histological results of the needle biopsy of tissue specimens. The diagnosis of tuberculous arthritis should be considered in any patient with unexplained shoulder pain and swelling in sternoclavicular joint in an endemic region for tuberculosis.

Background:

Tuberculous arthritis is an uncommon form of extrapulmonary tuberculosis (TB) which is more common in immune deficiency states. Tuberculosis of the joints is reported in approximately 1% of TB patients. On the other hand infection of the sternoclavicular joint is also rare and tuberculous infection of this joint is even less frequent (1,2).

In endemic regions of the developing countries, TB arthritis is mostly a disease of children and young adults while in developed countries the disease is predominantly seen in older adults and immunocompromised hosts. Mycobacterium tuberculosis causes a chronic granulomatous monoarthritis that is usually the result of hematogenous dissemination from a distant focus of infection. Articular infection may remain latent for long periods before clinical presentations. The clinical findings are usually indistinguishable from other infectious or noninfectious arthritis. Coexisting pulmonary or other extra-articular infections may be evident but in more than one half of cases co-infection is not present. Fever and

other constitutional symptoms of TB are often absent. Tuberculosis arthritis typically involves knees, hips and ankles but sternoclavicular joint involvement is extremely uncommon (3). Hereby, we report a rare case of unilateral tuberculosis sternoclavicular joint abscess without any demonstrable active foci of pulmonary or extra pulmonary TB.

Case description

A 63-year-old woman was admitted to the *affiliated teaching Hospital of Zahedan University of Medical Sciences* complaining of left shoulder pain and swelling over the left sternoclavicular region. The swelling had been progressed gradually over a seven-month period. She had a history of weight loss, low-grade fever and night sweats during that period. The patient did not have any risk factor for immune deficiency disorders and previous history of tuberculosis. She had a history of minor trauma in her left shoulder. Several antibiotics were prescribed for her condition without any improvement. On physical examination the temperature was 37.3°C on admission. A swelling was observed over the left sternoclavicular joint without any erythema or warmth. Laboratory tests revealed hemoglobin of 12.5gm% and white blood cells of 3700 cells/mm³. Erythrocyte sedimentation rate was 42 mm in the first hour. Destruction of the sternoclavicular joint was shown on plain radiography (**Figure 1**).

Infectious Diseases and Tropical Medicine Research Center, Zahedan University of Medical Sciences, Zahedan, Iran

Corresponding Author:

Roya Alavi-Naini, MD
Infectious Diseases and Tropical Medicine Research Center
Boo-Ali Hospital
Zahedan University of Medical Sciences Zahedan, Iran
Tel: +98/541 3228101
Fax: +98/541 3229197
Mobile: 09121194544
E-mail: ranani@gmail.com

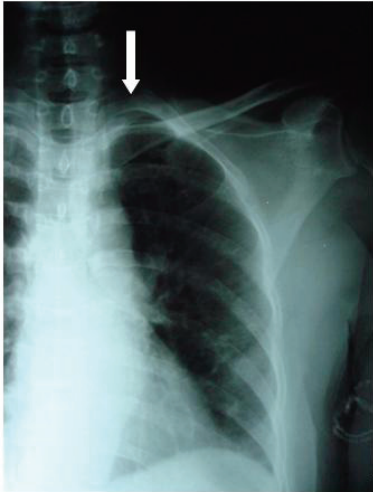


Fig.1: chest X-ray of the patient (PA view) showing osteolytic destruction of the sternal end of left clavicle (arrow)

The result of CXR was reported normal. Chest computerized tomography (CT) scan showed fluid collections of 2×4 cm in diameter; in and around left sternoclavicular joint, with erosions involving medial end of the clavicle and upper part of sternum (**Figure 2**).

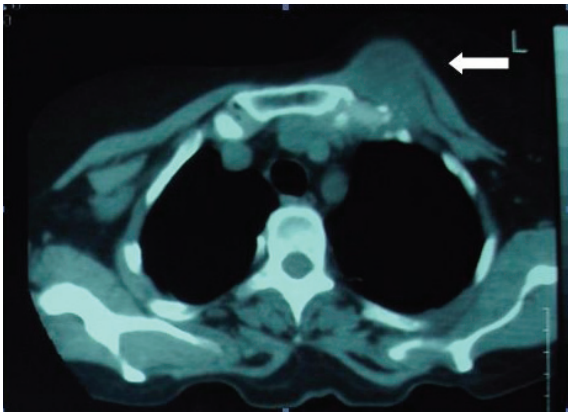


Fig. 2: Chest computerized tomography shows destruction of clavicular and sternal end of left sternoclavicular joint (arrow) with a soft tissue component, documenting the presence of cold abscess

Needle aspiration of the swellings yielded pus. Routine culture and Ziehl-Nielsen staining of the aspirated pus were negative. Fine Needle aspiration of cold abscess was performed and the diagnosis of sternoclavicular joint tuberculosis was made based on the presence of epithelioid cell granulomas with multinucleated giant cells and caseous necrosis in the tissue specimens. The patient was treated with isoniazid, ethambutol, rifampicin, and

pyrazinamid. There was an obvious improvement several months after the beginning of treatment.

Discussion:

Staphylococcus Aureus is the most common cause of bacterial sternoclavicular septic arthritis, especially in adults with infected central venous line. Other risk factors responsible for this kind of infection include intravenous drug abuse, distant-site infection, immune suppression, trauma and diabetes mellitus (4). Staphylococcus aureus and Pseudomonas aeruginosa represent two major causes of sternoclavicular septic arthritis in intravenous drug users. Sternoclavicular septic arthritis accounts for approximately 1% of septic arthritis in the general population and 17% of intravenous drug users. Microorganisms usually enter the sternoclavicular joint from adjacent valves of subclavian vein after injecting contaminated drugs into the upper extremity (5). Bacteria can easily pass from the subclavian vein into the joint space causing infection of this area. Sternoclavicular infection can also be secondary to a skin infection after distant sites of infection like urinary and respiratory tract infections, pericarditis; and intra-abdominal abscess. In these circumstances Staphylococcus aureus is responsible for the majority of the cases (49%), followed by Pseudomonas aeruginosa (10%) and Mycobacterium tuberculosis (3%). Most cases of Pseudomonas infection affecting the sternoclavicular joint have been reported in immunosuppressed intravenous drug users (6). Sternoclavicular arthritis has also been described in healthy adults without associated predisposing risk factors (5). Approximately one-tenth of extra pulmonary TB involves bone and joints, accounting for 1% to 3% of all TB cases (7). Sternoclavicular joint is an extremely rare site for occurrence of tuberculous arthritis and involves 1-2% of all cases of peripheral tuberculous arthritis (8). The rarity of its occurrence can be attributed to the special blood supply of this area. Tuberculous sternoclavicular arthritis most commonly presents as a cystic, globular, minimally tender, non-pulsatile swelling without any erythema or warmth over the involved joint (9). Diagnosis is often delayed by several weeks or months due to the absence of constitutional symptoms and indolent nature of the disease. Complications include compression and erosion of the large blood vessels at the base of the neck and migration of tuberculosis abscesses to the mediastinum causing mediastinitis (10). The reported patient had a history of trauma that could be a predisposing factor for tuberculosis. Trauma is responsible for activation of TB in some literatures (11,12).

CT scan usually shows destruction of the osteoarticular part of the joint as well as the exact extension of the disease. Diagnosis becomes straightforward, if acid-fast bacilli are isolated from aspirate and/ or if pathological

tissue specimens reveal epitheloid cells and Langerhan's giant cells and/or if there is evidence of tuberculosis in other parts of the body. Otherwise definitive diagnosis may require surgical procedure for biopsy of tissue specimens for both pathology and culture. Empirical antituberculous therapy (ATT) may be started on the basis of clinical findings and the appearance of cold abscess in the joint in areas endemic for tuberculosis. Clinical improvement is usually seen with standard ATT (13). Presence of chronic inflammation with granuloma formation on histopathological examination is an important clue for the diagnosis, especially for residents of endemic zones and travelers from those areas. A high index of suspicion with smear and histopathological examination and early ATT is the key to success and could prevent the extension of the disease. Tuberculosis should be considered in any patient with chronic arthritis in an unusual location such as sternoclavicular joint in an endemic region.

Consent

Written informed consent was obtained from the patient for publication of this case report and any accompanying images.

Competing interests:

The authors received no financial or other type of support to carry out this study. There is no conflict of interests. This article has not been published in any other journal.

References

1. Tuli SM: Tuberculosis of the Skeletal System: Bones, Joints, Spine and Bursal Sheaths. New Delhi: Jaypee, 1993:121-123.
2. Fukasawa H, Suzuki H, Kato A, Yamamoto T, Fujigaki Y, Yonemura K, Hishida A: Tuberculous arthritis mimicking neoplasm in a hemodialysis patient. *Am J Med Sci.* 2001 Dec, 322(6):373-5.
3. Yasljda T, Tamiika K, Yasljda M, Tamiika K, Fijjiwaka M: Tuberculous Arthritis of the Sternoclavicular Joint. *J of bone and joint surgery.* 1995, 77(1):136-139.
4. Ross JJ, Shamsuddin H: Sternoclavicular septic arthritis. Review of 180 cases. *Medicine.* 2004, 83 (3): 139-148.
5. Bar-Natan M, Salai M, Sidi Y, Gur H: Sternoclavicular infectious arthritis in previously healthy adults. *Semin Arthritis Rheum* 2002, 32(3):189-195.
- 6- Kaw D, Yoon Y. Pseudomonas sternoclavicular pyarthrosis. *South Med J.* 2004;97(7):705-706.
7. Ma zlavija KN, kotwal PP: Arthritis associated with tuberculosis. *Best Pract Res Clin Rheumatol.* 2003, 17:319-343.
8. Bezza A, Niamane R, Benbouazza K, el Maghraoui A, Lazrak N, Kettani M, Missaoui A, Bensabbah R, Rhazali L, Hassouni F, Mohattane A, Hajjaj-Hassouni N: Tuberculosis of the sternoclavicular joint. Report of two cases. *Rev Rhum Engl Ed.* 1998, 65(12):791-794.
9. Pandita KK, Sharma R, Dogra S, Pandita S: Bilateral sternoclavicular joint tuberculous cold abscess. *Ann Thorac Med* 2010, 5:56-57.
10. Katsoulis I.K, Bossi M, Damani N, Livingstone J.I: Arthritis of the sternoclavicular joint masquerading as rupture of the cervical oesophagus: a case report. *Journal of Medical Case Reports* 2009, 3:40; <http://www.jmedicalcasereports.com/content/3/1/40>
11. Jackson RH, King JW: Tenosynovitis of the hand: A forgotten manifestation of tuberculosis. *Review of infectious diseases.* 1989, 11(4):616-618.
12. Weir WRC, Muraleedharan MV: Tuberculosis arising at the site of physical injury: eight case histories. *Journal of Infection.* 1983, 7(1):63-66.
13. Shrivastav A, Pal J, Karmakar P.S, Debnath N.B: Tuberculosis of sternoclavicular joint- uncommon manifestation of a common disease. *J Medicine* 2010, 11:102-104.