



# Heterotopic Pregnancy After In Vitro Fertilization Ending with a Successful Term Labor, a Case Report

Somayeh Livani <sup>1</sup> and Alireza Fatemi <sup>2,\*</sup>

<sup>1</sup>Clinical Research Development Unit (CRDU), Sayad Shirazi Hospital, Golestan University of Medical Sciences, Gorgan, Iran

<sup>2</sup>Golestan Research Center of Gastroenterology and Hepatology, Golestan University of Medical Sciences, Gorgan, Iran

\*Corresponding author: Golestan Research Center of Gastroenterology and Hepatology, Golestan University of Medical Sciences, Gorgan, Iran. Email: seyedalireza.fatemi@gmail.com

Received 2021 March 02; Revised 2021 March 13; Accepted 2021 March 15.

## Abstract

**Introduction:** Heterotopic pregnancy is defined as the simultaneous presence of intrauterine and ectopic pregnancies, manifesting with abdominal pain and vaginal bleeding. Previous tubal surgeries and pelvic inflammatory diseases increase the risk of this anomaly. In this case report, heterotopic pregnancy after in vitro fertilization (IVF) in a 32-year-old female was reported.

**Case Presentation:** A 32-year-old female was referred to our medical center, presenting with abdominal pain and vaginal bleeding. She had IVF pregnancy seven weeks ago without a history of any other illness or consuming a specific drug. According to ultrasound results, heterotopic pregnancy was diagnosed. Therefore, we decided to perform the salpingectomy and laparotomy of the fetus. The patient had a normal delivery via cesarean section at term (the 38th week of pregnancy). The patient remained stable without any further referral for the mentioned condition.

**Conclusions:** Due to the importance of heterotopic pregnancy and its prevalence among women using fertility procedures and assisted reproduction techniques (such as IVF), even in the presence of a gestational sac containing yolk sac and after the detection of the embryo in the endometrium cavity, the adnexa should be well checked to rule out heterotopic pregnancy to obviate the risk of abortion and other fatal outcomes.

**Keywords:** Case Report, Heterotopic Pregnancy, In Vitro Fertilization

## 1. Introduction

Heterotopic pregnancy refers to the coexistence of intrauterine and extrauterine pregnancy. At its early stages, heterotopic pregnancy presents with nonspecific features mimicking other abnormal manifestations of pregnancy (1). Although the phenomenon is rare, it occurs more frequently nowadays and may be associated with life-threatening complications such as ruptured uterus and massive bleeding. Previous tubal surgeries and pelvic inflammatory diseases increase the risk of this anomaly (2). Surgery may successfully save most of these types of pregnancies and therefore embryos if the condition is diagnosed early. Careful clinical or ultrasound examination of adnexa in asymptomatic patients is necessary and helpful for achieving an accurate diagnosis and formulating a logical therapeutic plan (3).

We here presented a female with heterotopic pregnancy after undergoing IVF. In addition to ultrasound assessment, salpingectomy and laparotomy of the fetus were

performed, leading to a normal term delivery.

## 2. Case Presentation

A 32-year-old pregnant female was referred to the emergency department of our medical center with abdominal pain extending to feet and vaginal bleeding. She had undergone IVF pregnancy seven weeks ago and had no history of any other illness or consuming a specific drug. Some of her vital signs were stable, including blood pressure (110/70 mmHg) and body temperature (38°C), but her pulse rate was high (110/bpm). The patient had a generalized abdominal tenderness but no dyspnea. Laboratory evaluation revealed that hemoglobin and hematocrit levels were lower than normal (6 g/dL and 19.1%, respectively). Other laboratory parameters, including white blood cell count, blood urea nitrogen, mean corpuscular volume, creatinine, and uric acid, were within normal ranges.

Ultrasound revealed an intrauterine gestational sac containing the yolk sac and a fetal pole with a normal heart

activity within the endometrial cavity. The yolk sac had a normal size and shape. The gestational age based on a crown lump length of 12 mm was estimated seven weeks  $\pm$  3 - 4 days (Figure 1). The trophoblastic tissue was circular. There was no subchorionic hematoma, and the Internal orifice of the uterus was closed. Ovaries were normal in size and shape. A 14  $\times$  11 mm isoechoic ringlike lesion was visualized in the left adnexa (Figure 2). Color doppler also demonstrated a ring of fire sign (Figure 3). Moreover, a 40  $\times$  22 mm isoechoic irregular-shaped lesion was also visualized around it, which was suggestive of a clot (Figure 4). Also, large amounts of free fluid with internal echo were illustrated in the abdominal and pelvic cavities, compatible with hemoperitoneum and suggestive for ruptured ectopic pregnancy (Figure 5).

### 3. Discussion

Heterotopic pregnancy is defined as the concurrent presence of intrauterine and ectopic pregnancies. Due to the increasing use of artificial reproductive techniques, the incidence of heterotopic pregnancies is rising; however, it is still an uncommon condition (4).

The prevalence of heterotopic pregnancy is estimated to be 1-3% in the women undergoing assisted reproductive technologies, especially ovulation induction pregnancy through IVF, which was the case in the present report (5). Assisted reproduction technologies have increased the incidence of concurrent intrauterine and extrauterine pregnancies, which has been reported to be 9 in 10000 pregnancies (6).

The most common site of heterotopic pregnancy is the ampulla portion of the fallopian tube, as it was the case in our patient, which is diagnosed when symptoms present. Patients with previous tubal surgeries are at an increased risk for this condition (7). The history of implementing an intrauterine device in patients with pelvic inflammatory diseases increases the risk of ectopic pregnancy (8). Our patient presented about five weeks after IVF with no noticeable past medical history.

It is essential to avoid life-threatening consequences by the early diagnosis and treatment of heterotopic pregnancy, such as hypovolemic shock, maternal mortality, and fetal loss. However, due to the possibility of concomitant intrauterine pregnancy, heterotopic pregnancy can be difficult to be diagnosed at early stages. Accordingly, the presence of heterotopic pregnancy risk factors may assist the diagnosis by raising suspicion. The level of hemoglobin in

our patient was remarkably below the normal range, and there were considerable amounts of free fluid in the internal echo of the pelvis. In addition, the presence of a mass in the adnexa and a history of IVF raised the suspicion of heterotopic pregnancy (9).

Heterotopic pregnancy is very uncommon in spontaneously occurring pregnancies and is associated with increased maternal and child mortality. According to this, careful clinical and ultrasound investigations, especially adnexa examination findings, are necessary in asymptomatic patients. Due to the importance of heterotopic pregnancy and its prevalence among the patients using fertility medications and assisted reproduction techniques, such as IVF, the adnexa should be well checked even after detecting a gestational sac containing the yolk sac and observing an embryo in the endometrial cavity to rule out heterotopic pregnancy (3).

Finally, salpingectomy and laparotomy of the fetus were performed, leading to a normal and term (the week 38th) delivery via cesarean section. During follow-up, the patient and her baby remained stable without any further referrals for the mentioned condition.

#### 3.1. Conclusion

Considering the importance of heterotopic pregnancy and its high incidence among the patients using assisted reproduction techniques such as IVF, clinicians should pay special attention to carefully check the adnexa, even after discerning a gestational sac containing the yolk sac and detecting an embryo in the endometrial cavity, to rule out heterotopic pregnancy.

#### Footnotes

**Authors' Contribution:** Study concept and design, A.F.; Acquisition of data, S.L.; Analysis and interpretation of data, S.L.; Drafting of the manuscript, A.F.; Critical revision of the manuscript for important intellectual content, S.L.; Administrative, technical, and material support, S.L.; Study supervision, S.L.

**Conflict of Interests:** No conflict of interest exists.

**Funding/Support:** None to declare.

**Informed Consent:** Written informed consent was obtained from the patient's parents.

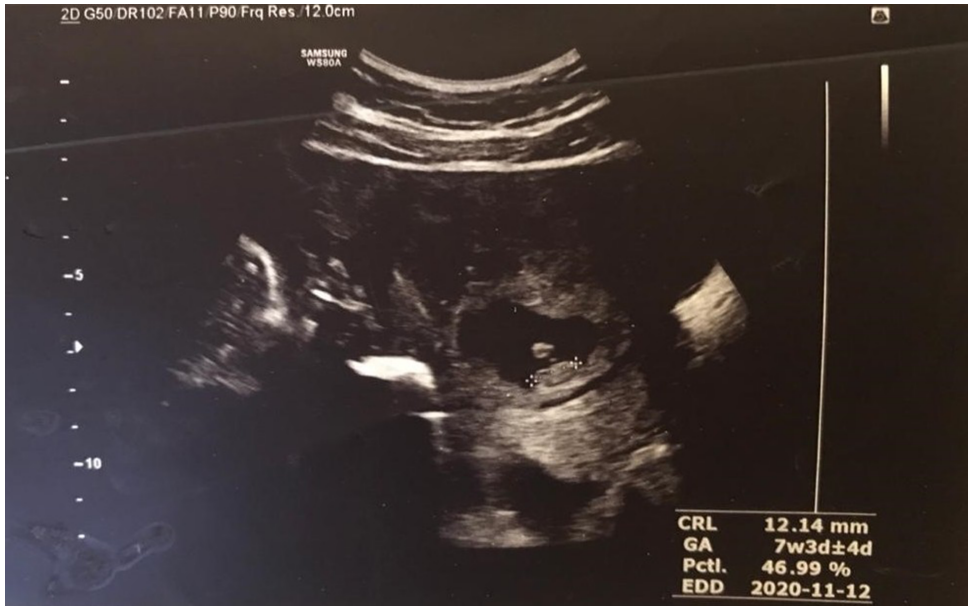

Figure 1. Ultrasound results showing a live embryo with the crown lump length of 12 mm and an estimated gestational age of seven weeks ± three or four days

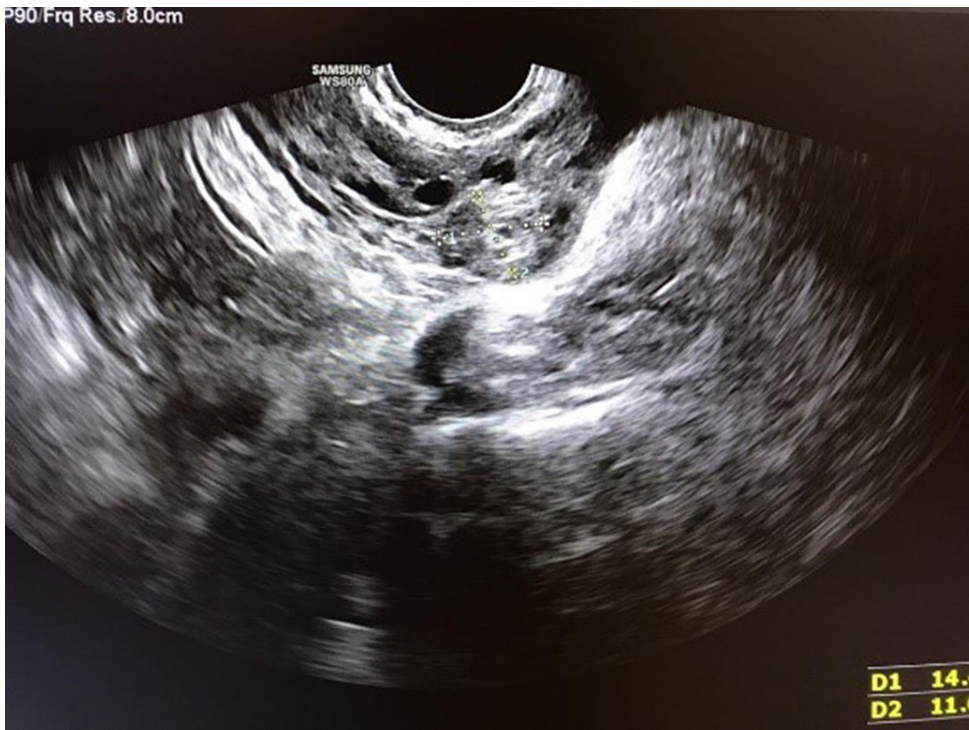
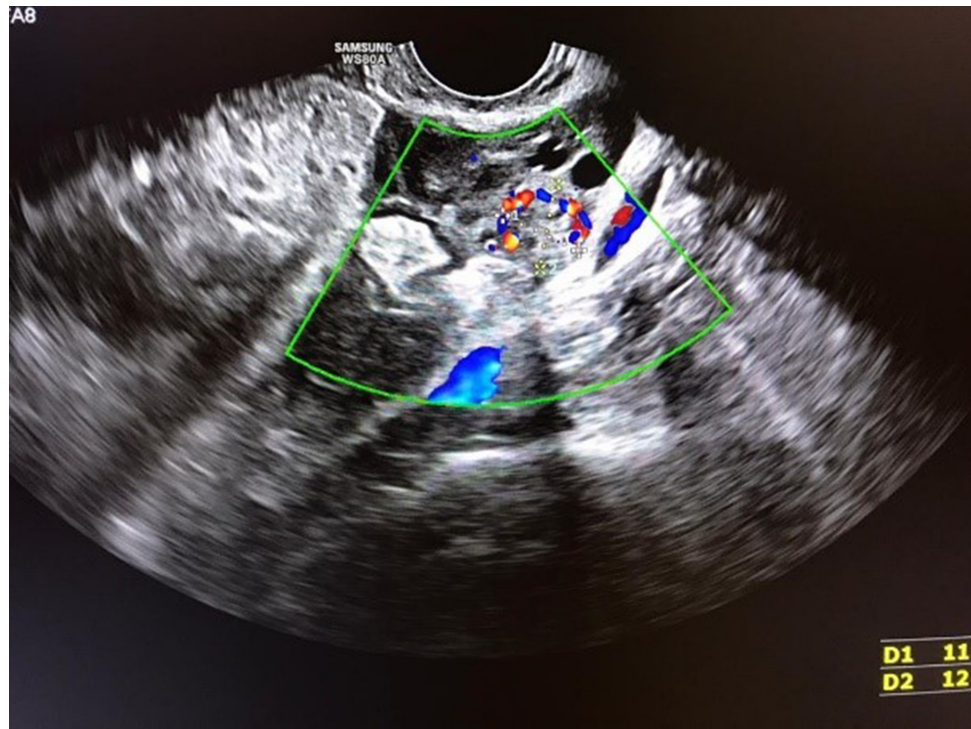
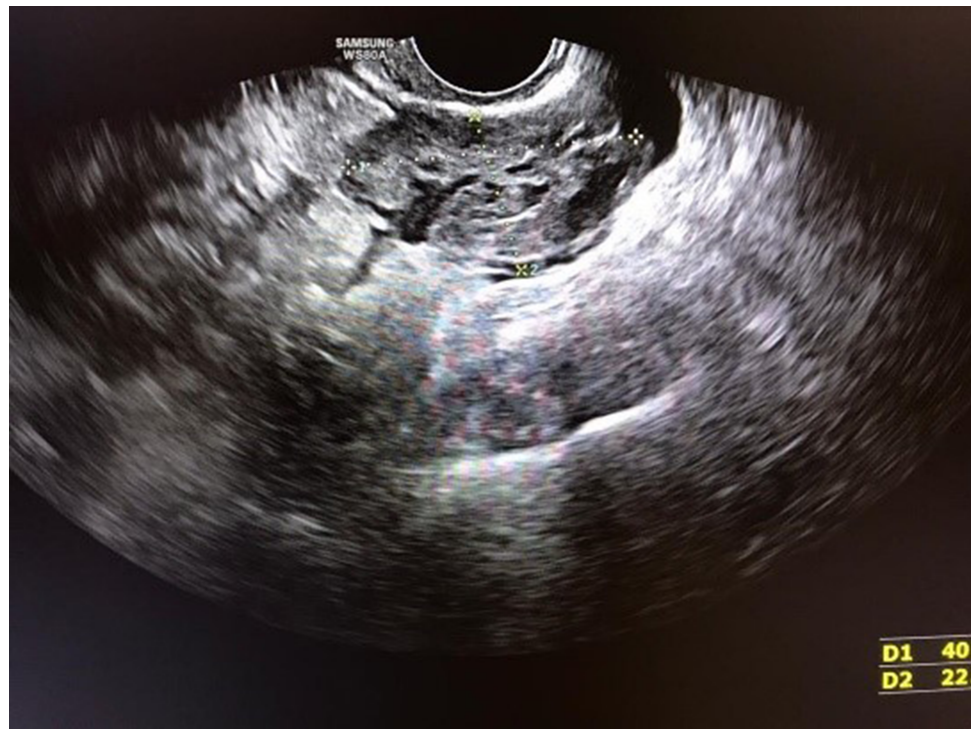
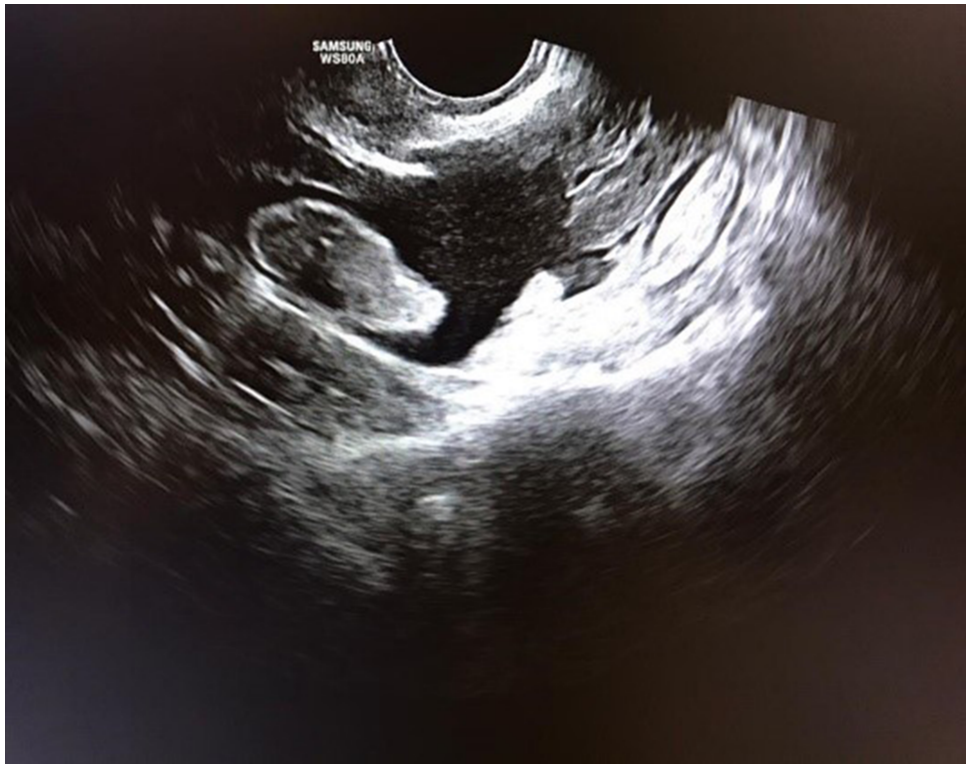Figure 2. Ultrasound findings showing a 14 × 11 mm isoechoic ringlike lesion in the left adnexa, compatible with ectopic pregnancy



**Figure 3.** Color doppler ultrasound demonstrating the ring of fire sign



**Figure 4.** Ultrasound findings showing a 40 × 22 mm isoechoic irregular-shaped lesion in the left adnexa mimicking a clot



**Figure 5.** Ultrasound results showing free fluid with internal echo in the pelvic cavity, compatible with hemoperitonea

## References

1. Stanic Z, Roje D, Matic D, Persec Z, Dapic K, Vidakovic MR, et al. Spontaneous heterotopic pregnancy as an uncommon clinical problem. *Z Geburtshilfe Neonatol.* 2020;**224**(4):223–6. doi: [10.1055/a-1079-6260](https://doi.org/10.1055/a-1079-6260). [PubMed: [32143229](https://pubmed.ncbi.nlm.nih.gov/32143229/)].
2. Lee KN, Ham HJ, Whang EJ, Eun-Ji J, Seung-Hye C, Lee KY. Successful heterotopic pregnancy with prior radical trachelectomy after trans-abdominal cervico isthmic cerclage with methotrexate treatment. *J Obstet Gynaecol Res.* 2020;**46**(4):663–7. doi: [10.1111/jog.14196](https://doi.org/10.1111/jog.14196). [PubMed: [32028544](https://pubmed.ncbi.nlm.nih.gov/32028544/)].
3. Wang X, Ma D, Zhang Y, Chen Y, Zhang Y, Liu Z, et al. Rare heterotopic pregnancy after frozen embryo transfer: A case report and literature review. *BMC Pregnancy Childbirth.* 2020;**20**(1):542. doi: [10.1186/s12884-020-03214-1](https://doi.org/10.1186/s12884-020-03214-1). [PubMed: [32943000](https://pubmed.ncbi.nlm.nih.gov/32943000/)]. [PubMed Central: [PMC7500546](https://pubmed.ncbi.nlm.nih.gov/PMC7500546/)].
4. Nabi U, Yousaf A, Ghaffar F, Sajid S, Ahmed MMH. Heterotopic pregnancy - a diagnostic challenge. Six case reports and literature review. *Cureus.* 2019;**11**(11). e6080. doi: [10.7759/cureus.6080](https://doi.org/10.7759/cureus.6080). [PubMed: [31853431](https://pubmed.ncbi.nlm.nih.gov/31853431/)]. [PubMed Central: [PMC6894893](https://pubmed.ncbi.nlm.nih.gov/PMC6894893/)].
5. Esterle J, Schieda J. Hemorrhagic heterotopic pregnancy in a setting of prior tubal ligation and re-anastomosis. *J Radiol Case Rep.* 2015;**9**(7):38–46. doi: [10.3941/jrcr.v9i7.2386](https://doi.org/10.3941/jrcr.v9i7.2386). [PubMed: [26629296](https://pubmed.ncbi.nlm.nih.gov/26629296/)]. [PubMed Central: [PMC4638409](https://pubmed.ncbi.nlm.nih.gov/PMC4638409/)].
6. Taylor HS, Pal L, Sell E. *Speroff's clinical gynecologic endocrinology and infertility.* Alphen aan den Rijn, Netherlands: Wolters Kluwer Health; 2019.
7. Shetty SK, Shetty AK. A case of heterotopic pregnancy with tubal rupture. *J Clin Diagn Res.* 2013;**7**(12):3000–1. doi: [10.7860/JCDR/2013/7526.3826](https://doi.org/10.7860/JCDR/2013/7526.3826). [PubMed: [24551707](https://pubmed.ncbi.nlm.nih.gov/24551707/)]. [PubMed Central: [PMC3919400](https://pubmed.ncbi.nlm.nih.gov/PMC3919400/)].
8. Chadee A, Rezai S, Kirby C, Chadwick E, Gottimukkala S, Hamaoui A, et al. Spontaneous heterotopic pregnancy: Dual case report and review of literature. *Case Rep Obstet Gynecol.* 2016;**2016**:2145937. doi: [10.1155/2016/2145937](https://doi.org/10.1155/2016/2145937). [PubMed: [27413561](https://pubmed.ncbi.nlm.nih.gov/27413561/)]. [PubMed Central: [PMC4930808](https://pubmed.ncbi.nlm.nih.gov/PMC4930808/)].
9. Jeon JH, Hwang YI, Shin IH, Park CW, Yang KM, Kim HO. The risk factors and pregnancy outcomes of 48 cases of heterotopic pregnancy from a single center. *J Korean Med Sci.* 2016;**31**(7):1094–9. doi: [10.3346/jkms.2016.31.7.1094](https://doi.org/10.3346/jkms.2016.31.7.1094). [PubMed: [27366008](https://pubmed.ncbi.nlm.nih.gov/27366008/)]. [PubMed Central: [PMC4901002](https://pubmed.ncbi.nlm.nih.gov/PMC4901002/)].