



Leydig Cell Tumor in a 53-Year-Old Patient with Gynecomastia and Gynecodynia: A Case Report and Literature Review

Piergustavo De Francesco,^{1*} Jamil Ghahhari,¹ Pietro Castellan,² Michele Nicolai,² Graziano De Luca,³ Michele Marchioni,¹ Giulia Primiceri,¹ Ambra Rizzoli,¹ Carlo D'orta,¹ Manuela Ingrosso,¹ Francesco Berardinelli,² Luca Cindolo,² and Luigi Schips²

¹Department of Urology, SS. Annunziata Hospital, "G.D'Annunzio" University of Chieti, Chieti, Italy

²Department of Urology, ASL Abruzzo2, Chieti, Italy

³Department of Anatomical Pathology, Torvergata University, Rome, Italy

*Corresponding author: Piergustavo De Francesco, MD, "G. D' Annunzio" University, 66100, Department of Urology, "SS Annunziata" Hospital, Via dei Vestini Chieti, 66100, Italy. Tel: +390-871358477, Fax: +390-871358269, E-mail: piergustavodf@hotmail.it

Received 2017 April 02; Revised 2017 July 05; Accepted 2017 October 23.

Abstract

Introduction: Testicular cancer is a rare neoplasm that afflicts men particularly in specific age-range. 5% to 6% of these tumors are non-germ cell tumors, in which Leydig cell tumors (LCTs) are included.

Case Presentation: This case report describes an uncommon presentation of a Leydig tumor cell in a 53 year old man with gynecomastia and gynecodynia

Conclusions: LCT is a rare neoplasm of the testis; its origin is still unknown and it could also present out of the normal range-age with the highest incidence. The radical surgery is still preferred, even if an organ sparing approach is reported. There are a lot of reports and case series in literature about LCT's but our work focus the attention of uncommon signs of presentation of this disease, especially gynecodynia.

Keywords: Testicular Cancer, Leydig Cell Tumor, Urology, Testis, Elderly, Gynecomastia, Gynecodynia

1. Introduction

Testicular cancer is a rare neoplasm with an incidence of 2/100.000 men. Approximately, 5% to 6% of these are non-germ cell tumors (1), in which Leydig cell tumors (LCTs) are included. LCTs account for 0.8% to 3% of all testicular tumors in adults and 4% in prepubescent children with typical presentation between 5 to 10 and 25 to 35 years (2).

Although they are usually clinically benign, about 10% of the reported cases have been associated with a malignant course (3).

LCTs frequently appear as unilateral mass with variable endocrinal manifestations according to the age. In pre-pubescent patients, the signs of gynecomastia are detectable in 10% of the cases often associated with premature virilization, while in adults, gynecomastia is found in 20% to 40%, associated with decreased libido and infertility. In this report, we presented a case of Leydig cell tumor of the testis with uncommon clinical manifestations.

2. Case Presentation

A 53-year-old Caucasian man was sent to our attention by an endocrinologist for a bilateral gynecomastia and gynecodynia, requiring a urological evaluation. He had visible bilateral breast enlargement and the palpation examination demonstrated bilateral palpable, tender, firm, mobile, disc-like mound of tissues, just under the nipple-areolar complex. No nodules were found and the patients referred gynecodynia (pain during the palpation as well as spontaneous). The scrotum examination revealed a 2 cm soft palpable mass on the upper pole of the right testis. No other signs, including swelling of superficial lymph nodes were observed. Scrotal ultrasonography revealed a non-homogenous hypoechogenic tumoral mass in the right testis of 25 × 22 mm (Figure 1). General blood tests were negative; alpha-fetoprotein (AFP) and β -human chorionic gonadotropin (β -hCG) were 4.6 ng/mL and < 1 mIU/mL, respectively (normal range: < 6 ng/mL and < 1.4 mIU/mL, respectively); hormonal setting showed high level of β -estradiol (73 pg/mL) and progesterone (1.56 ng/mL) (normal range: 10 - 40 pg/mL and 0.20 - 1.40 ng/mL, respectively). Total testosterone, FSH, LH, and prolactin were 0.96

ng/ml, 2.2 mIU/ml, 0.8 mU/mL, and 3.6 mg/mL, respectively (normal range: 2.10 - 7,50 ng/mL, 1.5-12.4 mIU/mL, 1,8 - 12,0 mIU/mL, and 2 - 18 ng/mL, respectively).

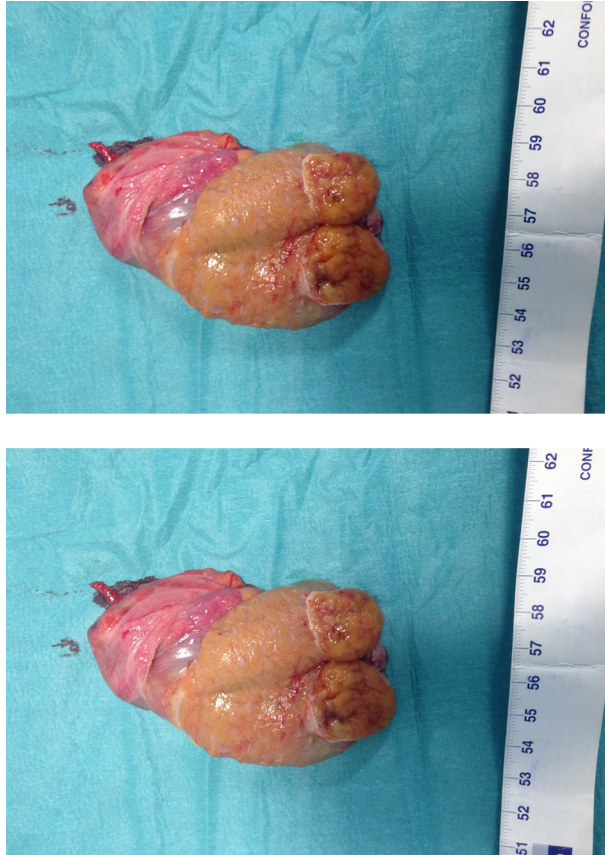

Figure 1. Right Radical Orchidectomy

Abdominal contrast-enhanced CT scan showed no abnormal findings. A radical approach was proposed to the patient. After obtaining an informed consent, right radical orchidectomy with testicular prosthesis implant was performed (Figure 1) with an uneventful postoperative course. The macroscopic examination showed a normal sized testicle with a soft, rubbery, and yellowish little mass on the upper pole. The histopathological examination revealed a Leydig cell tumor with regular growing pattern without any signs of vascular or perineural invasion. Moreover, no necrotic areas were observed and the mitotic index was low (Figure 2). Immunohistochemical profile showed diffuse positive staining for Calretinin, Vimentin, and Chromogranin, and negative staining for Synaptophysin, Cytokeratin AE1/AE3, S100, CD99, and CKIT.

Clinically, the bilateral gynecomastia disappeared after surgery, while gynecomastia decreased considerably af-

ter 4 weeks. At the first week, all blood test results were normal. Only β -estradiol serum level was moderately increased. At 1 month follow up, the full body CT scan result was negative.

At 16 weeks, hormonal investigations showed a normal level of β -estradiol, AFP, and β -hCG, while gynecomastia still persisted even if reduced.

3. Discussion

Leydig cell tumors are uncommon. The etiology is unknown and it seems to be a heterogeneous disease. Some authors have reported a somatic activating mutation in the guanine nucleotide-binding protein α gene (4). Some others reported an inherited fumarate hydratase mutation, which appeared to cause tumor growth through the activation of the hypoxia pathway (5). Alterations in local stimuli, including mullerian-duct inhibitory factor, inhibin, growth factors, and temperature may also create favorable conditions for tumorigenesis (6). Berthold hypothesized a possible relationship between LCTs and finasteride (7).

The clinical presentation of LCTs is usually unilateral and only 10% is associated with a malignant course (3). In rare cases, a primary presentation in the epididymis could occur (8).

Although LCTs mostly affected men between 5 to 10 years and 25 to 35 years, in our case, the tumor presentation was in an adult man out of the typical age of incidence.

Normally, LCTs are incidental findings on scrotal ultrasonography performed for other indications (9) and the scrotum ultrasound is useful to confirm the suspected diagnosis of testicular tumor (4). In our case, the patient was symptomatic and the scrotal ultrasonography just supported the physical examination, revealing a non-homogenous hypoechoic tumoral mass in the right testis.

In patients with LCTs, the tumor markers (AFP, β -hCG, and lactate dehydrogenase) are commonly in the normal ranges with secretion of hormones (testosterone and estrogens). In our case, tumor markers were steadily negative (before and after surgery); estrogens were pre-operatively elevated and became normal few weeks after surgery. From a clinical perspective, gynecomastia disappeared almost soon, whereas gynecomastia shortly regressed.

Abdominal and pelvic CT scan and chest radiography are indicated if malignancy is suspected; however, in this case, the imaging was normal.

Commonly, the surgical management of LCTs is the radical orchidectomy (10, 11). Nevertheless, an organ sparing surgery was reported by Suardi in small LCTs with benign characteristics (12, 13).

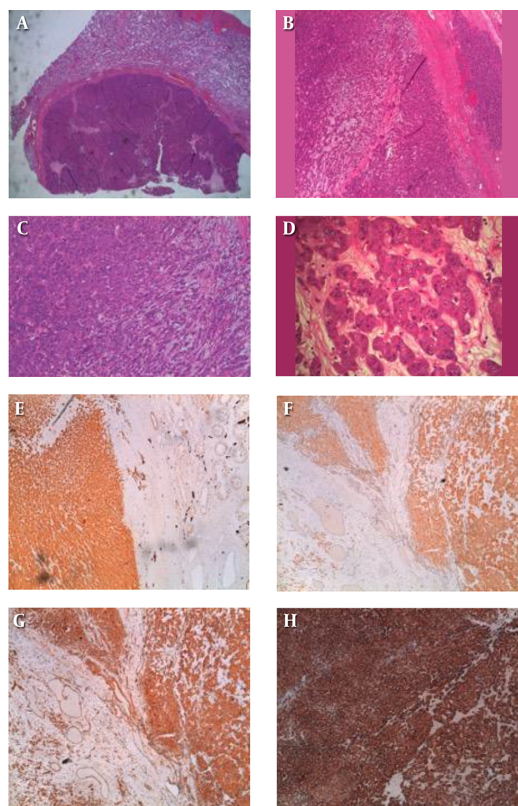


Figure 2. Histopathological Examination

The pathological exam with immunohistochemistry is essential for the final diagnosis. Even in our case, the histopathology confirmed the diagnosis without any suspect of malignancy. The results of immunoreactive tests were consistent with the existing literature (3). Although a long-term follow up is needed, we reported that after 16 months, the patient was free of disease with no evidence of recurrence or metastasis, with a normal serum levels of hormones and tumor markers, and without any signs of recurrence in the subsequent CT scan.

It is known that LCTs is a rare but possible disease; it has been yet described by many authors and for this reason, it is well known among the scientific community. There are a lot of reports and case series, including patients out of the common incidence range of age. In our study (Table 1), we found LCT's presentation, consisting of gynecomastia and gynecodynia. While gynecomastia is already present in their studies, surprisingly no cases with gynecomastia are reported.

Leydig cell tumors are uncommon neoplasms, arising from gonadal stroma. The self-examination of testicles and ultrasonography exam appear to be a very important step

for the diagnosis of testicular tumors. Also, other signs such as gynecomastia could be important to identify these types of tumor and they can influence the hormonal aspect of the patient.

In Leydig cell tumors, orchiectomy is the primary treatment, although an organ sparing approach for small lesion has been supported (13). Likewise, in the absence of any sign of malignancy, long-term follow up is necessary to exclude recurrence or metastasis.

(FIG.1: intraoperative image of right testis with tumor on the upper pole sectioned) (FIG.2: This nodular neoplasm shows a thick fibrous pseudo-capsule (1-4) and it is constituted by sheets, cords and solid nests of polygonal cells (3, 4), with scant edematous myxoid stroma (4). At higher magnification (4) epithelioid neoplastic cells have markedly eosinophilic granular cytoplasm with small vacuoles and round nuclei with prominent nucleoli. There are no atypical mitoses or necrosis.

The tumor cells are strongly and diffusely positive for Vimentin (c), with marked cytoplasm staining, while pan-cytokeratins are negative (not shown). Also Calretinin (a) and Inhibin (d) show a diffuse and intense cytoplasmic

Table 1. Review of Literature and Our Case

Study	Type of Study	Number of Cases	Age or Median Age	Gynecomastia (n)	Gynecodynia (n)	Malignant Course (n) (Medium Follow Up: 30 Months)
Gheorghisan-Galateanu AA. Leydig cell tumors of the testis: a case report. <i>BMC Res. Notes.</i> 2014; 7:656.	Case report	1	29 y	0	0	0
Tazi MF et al Leydig cell hyperplasia revealed by gynecomastia. <i>Rev. Urol.</i> 2008;10: 164 - 7.	Case report	1	17 y	1	0	0
Sugimoto K, et al. A malignant Leydig cell tumor of the testis. <i>Int. Urol. Nephrol.</i> 2006;38: 291 - 2.	Case report	1	68 y	1	0	0
Libe R, et al. A rare cause of hypertestosteronemia in a 68-year-old patient)...activating mutation. <i>J. Androl.</i> 2012;33: 578 - 84.	Case series	29	48 y (MA)	unspecified	0	2
Lejeune H et al. Origin, proliferation and differentiation of Leydig cells. <i>J. Mol. Endocrinol.</i> 1998;20:1 - 25.	Case report	1	36 y	1	0	0
Berthold D, et al. Finasteride-related Leydig cell tumour: report of a case and literature review. <i>Andrologia.</i> 2012;44 Suppl 1:836 - 7.	Case report	1	40 y	1	0	1
Albers P, et al. Guidelines on Testicular Cancer: 2015 Update. <i>Eur. Urol.</i> 2015;68:1054 - 68.	Case report	1	60 y	0	0	1
Our Case	Case report	1	53 y	1	1	0

stain in the solid cords of tumor cells. These three markers, joined to the morphological features, are sufficient to make diagnosis of Leydig cell tumor. Another immunohistochemical stain used was Chromogranin (b), which was positive, but not essential for diagnosis).

Acknowledgments

None declared.

Footnotes

Authors' Contribution: Study concept and design: Piergustavo De Francesco, Michele Nicolai; acquisition of data: Piergustavo De Francesco, Graziano De Luca, Michele Marchioni, Ambra Rizzoli, Giulia D'Orta, Giulia Primiceri, drafting the manuscript: Piergustavo De Francesco, Pietro Castella, Luigi Schips, Luca Cindolo; Critical revision of the manuscript for important intellectual content: Piergustavo De Francesco, Luca Cindolo, Luigi Schips; obtaining funding: none; Administrative, technical, or material support: none; supervision: Luca Cindolo, Berardinelli, Michele Nicolai, Luigi Schips; other (specify): none.

Conflict of Interest: None declared.

Financial Disclosures: All authors certified that all conflicts of interest, including specific financial interests and relationships and affiliations relevant to the subject matter or materials discussed in the manuscript (eg, employment/affiliation, grants or funding, consultancies, honoraria, stock ownership or options, expert testimony, royalties, or patents filed, received, or pending) are the following: none.

References

- Gheorghisan-Galateanu AA. Leydig cell tumors of the testis: a case report. *BMC Res Notes.* 2014;7:656. doi: [10.1186/1756-0500-7-656](https://doi.org/10.1186/1756-0500-7-656). [PubMed: [25230718](https://pubmed.ncbi.nlm.nih.gov/25230718/)].
- Tazi MF, Mellas S, El Fassi MJ, Farih MH. Leydig cell hyperplasia revealed by gynecomastia. *Rev Urol.* 2008;10(2):164-7. [PubMed: [18660859](https://pubmed.ncbi.nlm.nih.gov/18660859/)].
- Sugimoto K, Matsumoto S, Nose K, Kurita T, Uemura H, Park YC, et al. A malignant Leydig cell tumor of the testis. *Int Urol Nephrol.* 2006;38(2):291-2. doi: [10.1007/s11255-006-6661-8](https://doi.org/10.1007/s11255-006-6661-8). [PubMed: [16868700](https://pubmed.ncbi.nlm.nih.gov/16868700/)].
- Libe R, Fratticci A, Lahlou N, Jornayvaz FR, Tissier F, Louisset E, et al. A rare cause of hypertestosteronemia in a 68-year-old patient: a Leydig cell tumor due to a somatic GNAS (guanine nucleotide-binding protein, alpha-stimulating activity polypeptide 1)-activating mutation. *J Androl.* 2012;33(4):578-84. doi: [10.2164/jandrol.111.013441](https://doi.org/10.2164/jandrol.111.013441). [PubMed: [22016347](https://pubmed.ncbi.nlm.nih.gov/22016347/)].
- Carvajal-Carmona LG, Alam NA, Pollard PJ, Jones AM, Barclay E, Wortham N, et al. Adult leydig cell tumors of the testis caused by germline fumarate hydratase mutations. *J Clin Endocrinol Metab.* 2006;91(8):3071-5. doi: [10.1210/jc.2006-0183](https://doi.org/10.1210/jc.2006-0183). [PubMed: [16757530](https://pubmed.ncbi.nlm.nih.gov/16757530/)].
- Lejeune H, Habert R, Saez JM. Origin, proliferation and differentiation of Leydig cells. *J Mol Endocrinol.* 1998;20(1):1-25. [PubMed: [9513078](https://pubmed.ncbi.nlm.nih.gov/9513078/)].
- Berthold D, Lhermitte B, Uffer M, Doerfler A. Finasteride-related Leydig cell tumour: report of a case and literature review. *Andrologia.* 2012;44 Suppl 1:836-7. doi: [10.1111/j.1439-0272.2011.01214.x](https://doi.org/10.1111/j.1439-0272.2011.01214.x). [PubMed: [21950360](https://pubmed.ncbi.nlm.nih.gov/21950360/)].
- Huang Y, Song J, Xu M, Zan Q. Primary Leydig cell tumour of epididymis: a rare case report with review of literature. *Andrologia.* 2013;45(6):430-3. doi: [10.1111/and.12049](https://doi.org/10.1111/and.12049). [PubMed: [23194277](https://pubmed.ncbi.nlm.nih.gov/23194277/)].
- Butruille C, Marcelli F, Ghoneim T, Lemaitre L, Puech P, Leroy X, et al. [Management of testicular lesions in a population of infertile patients]. *Prog Urol.* 2012;22(1):45-52. doi: [10.1016/j.purol.2011.08.030](https://doi.org/10.1016/j.purol.2011.08.030). [PubMed: [22196005](https://pubmed.ncbi.nlm.nih.gov/22196005/)].
- Albers P, Albrecht W, Algaba F, Bokemeyer C, Cohn-Cedermark G, Fizazi K, et al. Guidelines on Testicular Cancer: 2015 Update. *Eur Urol.* 2015;68(6):1054-68. doi: [10.1016/j.eururo.2015.07.044](https://doi.org/10.1016/j.eururo.2015.07.044). [PubMed: [26297604](https://pubmed.ncbi.nlm.nih.gov/26297604/)].
- Bertram KA, Bratloff B, Hodges GF, Davidson H. Treatment of malignant Leydig cell tumor. *Cancer.* 1991;68(10):2324-9. [PubMed: [1913469](https://pubmed.ncbi.nlm.nih.gov/1913469/)].

12. Giannarini G, Mogorovich A, Menchini Fabris F, Morelli G, De Maria M, Manassero F, et al. Long-term followup after elective testis sparing surgery for Leydig cell tumors: a single center experience. *J Urol.* 2007;**178**(3 Pt 1):872-6. quiz 1129. doi: [10.1016/j.juro.2007.05.077](https://doi.org/10.1016/j.juro.2007.05.077). [PubMed: [17631320](https://pubmed.ncbi.nlm.nih.gov/17631320/)].
13. Suardi N, Strada E, Colombo R, Freschi M, Salonia A, Lania C, et al. Leydig cell tumour of the testis: presentation, therapy, long-term follow-up and the role of organ-sparing surgery in a single-institution experience. *BJU Int.* 2009;**103**(2):197-200. doi: [10.1111/j.1464-410X.2008.08016.x](https://doi.org/10.1111/j.1464-410X.2008.08016.x). [PubMed: [18990169](https://pubmed.ncbi.nlm.nih.gov/18990169/)].