



Evaluation of TP53 and HER-2/neu Genes Expression Levels in Gestational Trophoblastic Diseases Cases and Determining Their Predictive Value in Diagnosis of Malignancy and Disease Progression

Fatemeh Hadi^{1,*}, Neda Kazemi¹, Maryam Sadat Hosseini¹ and Abdolali Ebrahimi²

¹Department of Gynecology and Obstetrics, Imam Hossein Hospital, Shahid Beheshti University of Medical Sciences, Tehran, Iran

²Department of Pathology, Imam Hossein Hospital, Shahid Beheshti University of Medical Sciences, Tehran, Iran

*Corresponding author: Department of Gynecology and Obstetrics, Imam Hossein Hospital, Shahid Beheshti University of Medical Sciences, Tehran, Iran. Email: dr.hadi398@gmail.com

Received 2021 September 03; Revised 2022 August 03; Accepted 2022 August 09.

Abstract

Background: Gestational trophoblastic disease (GTD) is a general term that includes several types of pathologically different diseases, which range from hydatidiform mole to choriocarcinoma. Early differentiation of these types is important to determine treatment strategy and prognosis.

Objectives: Genetic markers such as TP53 and HER-2/neu expression are recently shown to have diagnostic and prognostic values. The aim of this study was to evaluate its significance.

Methods: We enrolled 62 patients diagnosed with GTD referred to Imam Hossein Hospital in Tehran, Iran between 2012 and 2017. Endometrial pathologic specimens were stained, using the immunohistochemistry (IHC) method for the expression of TP53 and HER-2/neu genes. Expression levels determined by IHC were compared between final pathologic diagnoses, using one-way ANOVA test (analysis of variances), which detects significant differences between the means of 3 or more independent groups.

Results: Out of 62 participants, 32 and 24 cases were diagnosed as partial and complete hydatidiform mole, respectively. Four cases had invasive hydatidiform mole and only 2 cases were diagnosed as choriocarcinoma. Analysis using ANOVA demonstrated that expression levels of both TP53 and HER-2/neu genes are significantly higher among patients with invasive form and choriocarcinoma compared with non-invasive hydatidiform mole ($P < 0.05$ for both genes). The receiver operating characteristic (ROC) curve for each gene showed that more than 55% positive staining for the TP53 gene can differentiate non-invasive hydatidiform mole from invasive form and choriocarcinoma with 100% sensitivity, and 92.9% specificity.

Conclusions: TP53 expression might serve as a potential diagnostic aid to differentiate benign and malignant GTDs and a future target for adjusting treatment based on the expression levels.

Keywords: Gestational Trophoblastic Disease, Trophoblastic Neoplasms, Choriocarcinoma, Disease Progression

1. Background

Gestational trophoblastic diseases (GTD) are referred to as the group of heterogeneous neoplastic disorders with high blood HCG levels. The severity of various types of GTDs are different and they have different potential regarding local invasion and metastasis (1, 2). The incidence rate of GTDs is rare in western countries and, according to global statistics, it is around 0.57 to 1.2 per 1000 pregnancies; whereas, in the southeast of Asia, the annual incidence of the disease is 7 to 10 times higher than the reported values in European countries and the USA (1-3).

The clinical prognosis of the disease is strongly associated with early diagnosis and the received clinical care. Gestational trophoblastic diseases (GTD) is curable in pres-

ence of early diagnosis and appropriate treatment. However, it could lead to death and a high mortality rate in metastatic cases (4, 5). In most developed countries, GTD is regarded as a curable health circumstance as almost all patients will be recovered from the disease. However, when cancer spreads outside of the uterus, the survival rate is decreased by 20% to 30% (6). Several attempts have already been developed for early diagnosis and differentiation of GTD different pathologies and the result is promising regarding immunohistochemical methods. According to previous studies, several biomarkers like P53, P57, P63, C-erbB-2 (7-10), and maspin (11) have been investigated for such purposes and it has been shown that there was a strong association between P53 and C-erbB-2 expression and tro-

phoblastic neoplasia (8). It was also illustrated that these two biomarkers together had high negative predictive values regarding the management of molar pregnancies (8). The efficacy of immunohistochemical assessment might be an area of controversy that should be considered (12).

2. Objectives

In the current study, we aimed at investigating the association between overexpression of TP53 and HER-2/neu genes and GTD determining their predictive values in this regard. We also aimed at assessing the usage of TP53 and HER-2/neu genes as a predictor of disease progression and detecting malignant cases of GTD.

3. Methods

We performed a cross-sectional study on all 62 patients, who were referred to Imam Hossein Hospital in Tehran, Iran, and diagnosed with GTD for 5 years between 2012 and 2017. GTD was diagnosed through pathologic investigation on samples that were taken from the placenta. We also retrieved demographic and clinical information regarding age, gestational age, number of pregnancies, previous miscarriage, hypertension in pregnancy, vaginal bleeding, and history of molar pregnancy. The expression level of P53 and HER2 was assessed, using immunohistochemical approaches. The participants were categorized into 4 groups, including partial mole, complete mole, invasive mole, and choriocarcinoma according to clinical diagnosis and pathologic information.

3.1. Statistical Analysis

We described continuous variables, using mean and standard deviation, while for categorical variables, frequency number of proportion was provided. The chi-square was used to assess the association between dichotomous variables. The one-way ANOVA test was applied to find significant differences between the means of 3 or more independent groups. We also draw a receiver operating characteristic curve (ROC) to determine the best cut-point of P53 to classify invasive and non-invasive mole groups. Sensitivity, specificity, positive predictive value (PPV), negative predictive value (NPV), area under curve (AUC), and the associated CI were also calculated. All statistical analysis was performed, using SPSS ver. 21.0. All P-values < 0.05 were considered significant.

3.2. Ethics Approval

This study is approved under the ethical approval code of IR.SBMU.MSP.REC.1398.065. The reference webpage for the ethics code number is addressed as: ethics.research.ac.ir/EthicsProposalView.php?id=60957. All participants were informed about the research objectives and completed informed consent.

4. Results

The study was performed on 62 patients with confirmed GTD, who have been referred to Imam Hossein Hospital in Tehran, Iran between 2012 and 2017. The participants were investigated in 4 groups based on their GTD status. The most frequent type of GTD was partial mole (51.6%), followed by complete mole (38.7%), and invasive mole (6.4%). On the other, the least prevalent type of GTD was choriocarcinoma (3.2%) (Figure 1). The mean (SD) of age in a partial, complete, invasive molar, and choriocarcinoma was 27.7 (6.3), 30.2 (10.9), 32.7 (11.9), and 37.2 (2.8), respectively. Overall, the proportion of abortion history was 24.1% and 4.8% of patients had a history of molar pregnancy and positive HCG in the first year was pretty low and observed in 3.2% of all study participants (Table 1).

Table 1. Participants' Baseline Characteristics^a

Characteristics	Values
Primary diagnosis	
Partial mole	32 (51.6)
Complete mole	24 (38.7)
Invasive mole	4 (6.4)
Choriocarcinoma	2 (3.2)
Age (Mean ± SD)	29.6 ± 8.5
Abortion	15 (24.1)
Positive HCG	3 (4.8)
History of molar pregnancy	2 (3.2)

^a Values are expressed as No. (%) unless otherwise indicated.

In the current research, we performed a cross-sectional analysis to investigate the association between mutation of P53 and Her-2/neu and invasion level of hydatidiform mole. We also assessed predictive values of P53 and Her-2/neu as biomarkers for diagnosis of invasive molar pregnancy. We compared the mean of TP53 over the investigated groups. According to our data, the average TP53 in partial and complete molar groups was 22.0 (18.0) and 34.7 (18.2), while it was 65.7 (2.9) in the invasive group and 74.0

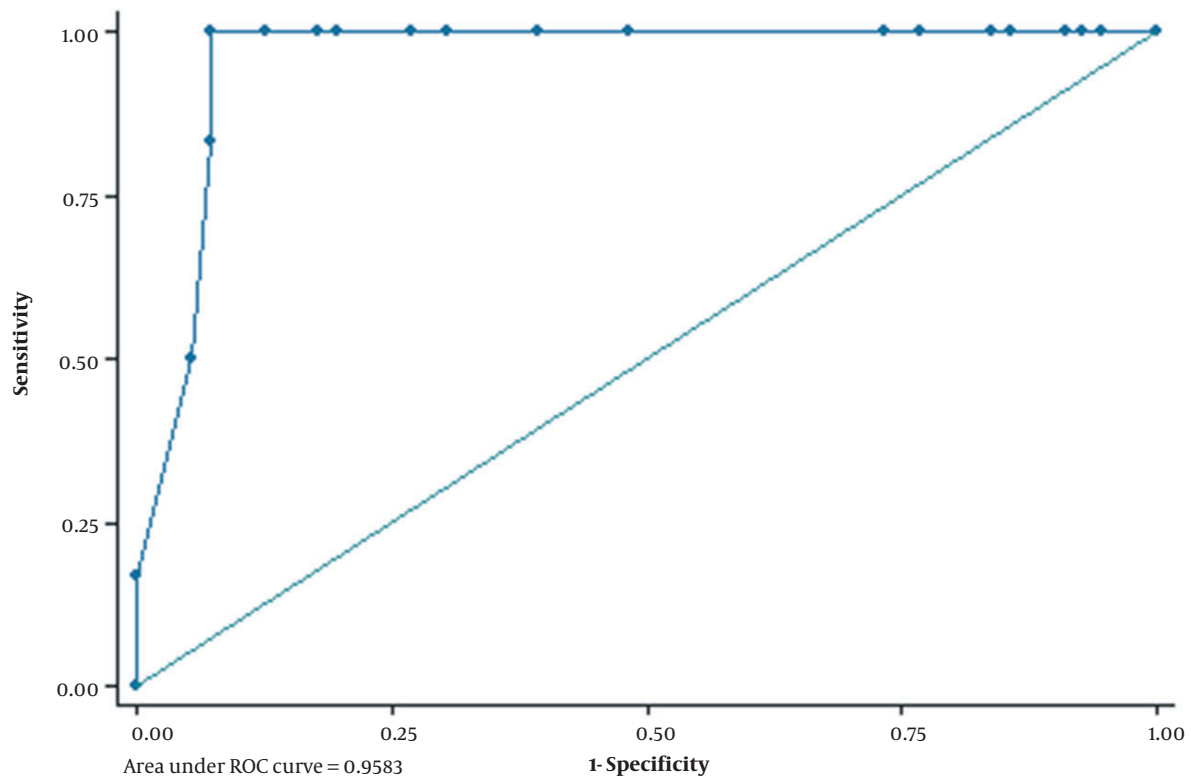


Figure 1. ROC curve to determine the best cut-off point of P53 for diagnosis of invasive GTDs

(5.6) in choriocarcinoma patients. One-way ANOVA illustrated a statistically significant difference among the compared groups regarding the average expression of TP53 (Table 2). We also compared HER2 between the group and observed higher values in invasive molar (1.5 ± 1.2) and choriocarcinoma (2.5 ± 0.7) in comparison to partial (0.8 ± 0.8) and complete molar (1.0 ± 0.8) groups and the observed difference was statistically significant ($P = 0.053$) (Table 2). We draw a ROC curve to estimate the best cut point for P53 to differentiate between partial/complete molar from invasive molar/choriocarcinoma. According to our analysis, the best cut point of P53 was 61.0. AUC in this cut point was 0.958 (95% CI = 0.93, 0.99) (Figure 1). Sensitivity and specificity was 100.0% (54.1%, 100%) and 92.9% (82.7%, 98%), respectively. We also estimated positive and negative predictive values that were 58.1% and 100%. Sensitivity, specificity, PPV, and NPV for Her-2/neu was 66.7%, 69.6%, 17.8%, and 95.5%, respectively (Table 3).

5. Discussion

The GTD spectrum is generally accompanied by a good prognosis. However, invasive behavior of the tissues may

lead to malignant transformation and metastasis. Early detection is associated with less economic burden on the health system, and higher rates of favorable pregnancy outcomes in women with limited fertility windows. Moreover, timely diagnosis may facilitate the appropriate recommendation of prophylactic chemotherapy in the high-risk group of GTN (13). Therefore, addressing a predictive marker for diagnosis of the disease progression has great importance. Several attempts have been performed to introduce a precise predictor for its development and a couple of biomarkers have shown interesting and promising results (7, 8, 11). We found that P53 was associated with a significant tendency to invasion and metastatic behaviors. The average expression of P53 was considerably higher in choriocarcinoma and invasive molar cases compared with the other forms. These malignant and invasive subtypes were more likely to have extremely high values of P53. P53 is a tumor suppressor gene that has a critical role in cell normal growth. Mutation of P53 has been shown as a risk factor in the pathogenesis of many human neoplasms and cancers (14, 15). Several studies have highlighted the over-expression of P53 in GTDs (8, 9, 11, 12). Although the results

Table 2. Average Expression of P53 and Her-2/neu by GTD Status^a

Gene	Partial Mole	Complete Mole	Invasive Mole	Choriocarcinoma	P-Value
P53	22.0 ± 18.0	34.7 ± 18.2	65.7 ± 2.9	74.0 ± 5.6	< 0.001
Her-2/neu	0.8 ± 0.8	1.0 ± 0.8	1.5 ± 1.3	2.5 ± 0.7	0.053

^a Values are expressed as mean ± SD.

Table 3. Sensitivity, Specificity, Positive, and Negative Predictive Values of P53 and Her-2/neu in the Diagnosis of Invasive GTDs

Gene	Sensitivity	Specificity	PPV	NPV
P53	100 (54.1, 100)	92.9 (82.7, 98.0)	58.1 (36.3, 77.1)	100 (100, 100)
Her-2/neu	66.7 (22.3, 95.7)	69.6 (55.9, 81.2)	17.8 (8.3, 34.1)	95.5 (90.3, 97.9)

of previous research are supporting immunohistochemical methods for diagnosis and differentiation of GTD, there are some controversial findings. For instance, Ali et al. indicated that overexpression of C-erbB-2 and P53 is not informative enough regarding chemotherapy administration in patients with molar pregnancy and it seems more further studies are required (12). We reported high positive and negative predictive values for P53 regarding diagnosis of malignant progression of molar pregnancy. Such findings have also been found by Hasanzadeh et al. that reported a positive predictive value of 90% and negative predictive value of 92% for p53-positive cytotrophoblasts (8). Our findings were also concordant with Chen et al., demonstrating that expression of P53 may serve as an effective diagnostic instrument in the prediction of metastatic molar pregnancy (9). Fayed et al. have also shown higher expression of P53 in the invasive molar pregnancy group compared with the non-invasive molar group, which is in line with the results of the current study (10). Such a positive correlation between the expression of P53 and GTNs has also been reported by Sun et al. (11).

In the present study, the proportion of positive Her-2/neu was 33.8% observed in 21 patients. The frequency of Her-2/neu positive phenotype in the invasive group was 66.6%, while it was 30.3% in the non-invasive group. We did not observe any significant association, which might reflect our small sample size and modestly insufficient statistical power. The sensitivity of Her-2/neu for diagnosis of invasive cases was pretty low, while we reported high specificity. Our results are supported by Menczer et al. that indicated the same findings for Her-2/neu overexpression in the prediction of GTN (13). According to their findings, the sensitivity of Her-2/neu expression for predication of GTN was 22.2%, while specificity was 83.3%, which is consistent with our values (13). They also showed a relatively good negative predictive value (74.1%), despite a very low positive predictive value of 33.3% (13). Another study depicted that expression of Her-2/neu was significantly higher in chori-

ocarcinoma cases compared with partial mole and complete mole groups (16). These findings could not be compared with our data as we had a limited number of choriocarcinoma cases and it was impossible to address the statistically significant difference. However, the average expression of Her-2/neu in 2 cases of choriocarcinoma in our study was partially higher than in other groups, which warrants further studies in this regard.

The current study is one of the limited attempts to address the correlation between Her-2/neu expression and hydatidiform moles. We also applied one of the most precise immunostaining approaches. However, our findings must be interpreted in the context of our limitations. Lack of statistical power due to the small sample size particularly in invasive molar and choriocarcinoma was the main limitation of the current study that could affect our findings. Hence, further studies with larger sample sizes might be required.

5.1. Conclusions

To sum up, overexpression of P53 might be considered a potential biomarker to predict the progression of GTD toward malignancy. However, replication of these results in subsequent studies is required to confirm the clinical benefits. On the contrary, due to the low sensitivity and positive predictive value of Her-2/neu, the utility in differentiation between invasive and non-invasive GTDs is uncertain.

Footnotes

Authors' Contribution: F.H., conceived and designed the evaluation and drafted the manuscript; N.K., participated in designing the evaluation, performed parts of the statistical analysis and helped to draft the manuscript; F.H., re-evaluated the clinical data, revised the manuscript and performed the statistical analysis and revised the manuscript;

M.H., collected the clinical data, interpreted them and revised the manuscript; M.H. and A.E.B., re-analyzed the clinical and statistical data and revised the manuscript. All authors read and approved the final manuscript. S.G. made a critical revision of the manuscript.

Conflict of Interests: All authors declare that they had no conflict of interests.

Ethical Approval: IR.SBMU.MSP.REC.1398.065 (available at the following webpage: ethics.research.ac.ir/EthicsProposalView.php?id=60957).

Funding/Support: The current study was performed as part of the first author thesis and received no funds.

Informed Consent: All participants were informed about the research objectives and completed informed consent.

References

- Ngan HYS, Seckl MJ, Berkowitz RS, Xiang Y, Golfier F, Sekharan PK, et al. Update on the diagnosis and management of gestational trophoblastic disease. *Int J Gynaecol Obstet*. 2018;**143**:79–85. doi: [10.1002/ijgo.12615](https://doi.org/10.1002/ijgo.12615). [PubMed: [30306586](https://pubmed.ncbi.nlm.nih.gov/30306586/)].
- Clement PB, Young RH. Trophoblastic lesions, miscellaneous primary uterine neoplasms, hematopoietic neoplasms, and metastatic neoplasms to the uterus. *Atlas of Gynecologic Surgical Pathology*. 2nd ed. Netherlands: Elsevier; 2008.
- Atrash HK, Hogue CJ, Grimes DA. Epidemiology of hydatidiform mole during early gestation. *Am J Obstet Gynecol*. 1986;**154**(4):906–9. doi: [10.5555/uri:pii:0002937886904825](https://doi.org/10.5555/uri:pii:0002937886904825).
- Berkowitz RS, Goldstein DP. Current management of gestational trophoblastic diseases. *Gynecol Oncol*. 2009;**112**(3):654–62. doi: [10.1016/j.ygyno.2008.09.005](https://doi.org/10.1016/j.ygyno.2008.09.005). [PubMed: [18851873](https://pubmed.ncbi.nlm.nih.gov/18851873/)].
- Lorigan PC, Sharma S, Bright N, Coleman RE, Hancock BW. Characteristics of women with recurrent molar pregnancies. *Gynecol Oncol*. 2000;**78**(3 Pt 1):288–92. doi: [10.1006/gyyno.2000.5871](https://doi.org/10.1006/gyyno.2000.5871). [PubMed: [10985882](https://pubmed.ncbi.nlm.nih.gov/10985882/)].
- Agarwal R, Alifrangis C, Everard J, Savage PM, Short D, Tidy J, et al. Management and survival of patients with FIGO high-risk gestational trophoblastic neoplasia: the U.K. experience, 1995-2010. *J Reprod Med*. 2014;**59**(1-2):7–12. [PubMed: [24597279](https://pubmed.ncbi.nlm.nih.gov/24597279/)].
- Missaooui N, Landolsi H, Mestiri S, Essakly A, Abdessayed N, Hmissa S, et al. Immunohistochemical analysis of c-erbB-2, Bcl-2, p53, p21(WAF1/Cip1), p63 and Ki-67 expression in hydatidiform moles. *Pathol Res Pract*. 2019;**215**(3):446–52. doi: [10.1016/j.prp.2018.12.015](https://doi.org/10.1016/j.prp.2018.12.015). [PubMed: [30558966](https://pubmed.ncbi.nlm.nih.gov/30558966/)].
- Hasanzadeh M, Sharifi N, Farazestanian M, Nazemian SS, Madani Sani F. Immunohistochemistry Study of P53 and C-erbB-2 Expression in Trophoblastic Tissue and Their Predictive Values in Diagnosing Malignant Progression of Simple Molar Pregnancy. *Iran J Cancer Prev*. 2016;**9**(3). e4115. doi: [10.17795/ijcp-4115](https://doi.org/10.17795/ijcp-4115). [PubMed: [27703642](https://pubmed.ncbi.nlm.nih.gov/27703642/)]. [PubMed Central: [PMC5038832](https://pubmed.ncbi.nlm.nih.gov/PMC5038832/)].
- Chen YX, Shen DH, Gu YQ, Zhong PP, Xie JL, Song QJ, et al. [Immunohistochemistry of p57 and p53 protein in differential diagnosis of hydropic abortion, partial and complete hydatidiform mole]. *Zhonghua Bing Li Xue Za Zhi*. 2011;**40**(10):694–7. Chinese. [PubMed: [22321550](https://pubmed.ncbi.nlm.nih.gov/22321550/)].
- Fayed ST, Naguib AH, Hemeda H, Ahmad NS, Elsheikh A, Dakrony M. The Predictive Value of C-erbB-2 and p53 Overexpression in the management of molar pregnancy. *Egypt J Pathol*. 2012;**32**(1):129–35. doi: [10.1097/01.XEJ.0000415933.54088.b3](https://doi.org/10.1097/01.XEJ.0000415933.54088.b3).
- Sun P, Wu Q, Ruan G, Zheng X, Song Y, Zhun J, et al. Expression patterns of maspin and mutant p53 are associated with the development of gestational trophoblastic neoplasia. *Oncol Lett*. 2016;**12**(5):3135–42. doi: [10.3892/ol.2016.5074](https://doi.org/10.3892/ol.2016.5074). [PubMed: [27899973](https://pubmed.ncbi.nlm.nih.gov/27899973/)]. [PubMed Central: [PMC5103910](https://pubmed.ncbi.nlm.nih.gov/PMC5103910/)].
- Ali SM, Ahmedi NY, Abdulhameed TT, Shalal TM. Immunorexpression of P53 protein in trophoblastic diseases. *Zanco J Med Sci*. 2017;**21**(1):1629–35. doi: [10.15218/zjms.2017.013](https://doi.org/10.15218/zjms.2017.013).
- Menczer J, Schreiber L, Berger E, Golan A, Levy T. Assessment of Her-2/neu expression in hydatidiform moles for prediction of subsequent gestational trophoblastic neoplasia. *Gynecol Oncol*. 2007;**104**(3):675–9. doi: [10.1016/j.ygyno.2006.10.012](https://doi.org/10.1016/j.ygyno.2006.10.012). [PubMed: [17126893](https://pubmed.ncbi.nlm.nih.gov/17126893/)].
- Hollstein M, Sidransky D, Vogelstein B, Harris CC. p53 mutations in human cancers. *Science*. 1991;**253**(5015):49–53. doi: [10.1126/science.1905840](https://doi.org/10.1126/science.1905840). [PubMed: [1905840](https://pubmed.ncbi.nlm.nih.gov/1905840/)].
- Efeyan A, Serrano M. p53: guardian of the genome and policeman of the oncogenes. *Cell Cycle*. 2007;**6**(9):1006–10. doi: [10.4161/cc.6.9.4211](https://doi.org/10.4161/cc.6.9.4211). [PubMed: [17457049](https://pubmed.ncbi.nlm.nih.gov/17457049/)].
- Makovitzky J, Vogel M, Miessner R, Mylonas I, Vogt-Weber B, Richter DU. Diagnostic aspects of hydatidiform mole with persistence of polymorphic trophoblastic hyperplasia. *Anticancer Res*. 2003;**23**(2A):1069–73. [PubMed: [12820349](https://pubmed.ncbi.nlm.nih.gov/12820349/)].