

Cerebellar Neuroblastoma in 2.5 Years Old Child

Mohammad Pedram¹, Majid Vafaie¹, Kiavash Fekri¹, Sabahat Haghi¹, Iran Rashidi², Chia Pirooti³

Abstract

Neuroblastoma is the third most common malignancy of childhood, after leukemia and brain tumors. Only 2% of all neuroblastoma occur in the brain. Primary cerebellar neuroblastoma is an specific subset of Primitive Neuroectodermal Tumors (PNET). Medulloblastoma is a relatively common and well-established entity, consisting of primitive and multipotential cells that may exhibit some evidence of neuroblastic or gliad differentiation. But cerebellar neuroblastoma with ultrastructural evidence of significant neuroblastic differentiation is extremely rare. We report a rare case of neuroblastoma in the cerebellum. A 2.5-year-old Iranian boy presented with vomiting and nausea in the morning and ataxia. CT scan showed a tumor mass in the cerebellum and the report of radiologist was medulloblastoma. Light microscopic assay showed a small cell neoplasm with lobules of densely packed cells (lobulated pattern) and better differentiated cells. Neuron-Specific Enolase was positive. Pathologic diagnosis confirmed the existence of cerebellar neuroblastoma. Chemotherapy followed surgical removal. No relapse occurred 12 months after surgery.

Keywords: Neuroblastoma; Cerebellum; Chemotherapy

Please cite this article as: Pedram M, Vafaie M, Fekri K, Haghi S, Rashidi I, Pirooti Ch. Cerebellar Neuroblastoma in 2.5 Years Old Child. Iran J Cancer Prev. 2013;6(3):174-6.

1. Thalassemia and Hemoglobinopathy Research Center, Ahvaz Jondishapur University of Medical Sciences, Ahvaz, Iran

2. Dept. of Pathology, Shafa Hospital , Ahvaz Jondishapur University of Medical Sciences, Ahvaz, Iran

3. Dept. of Neurosurgery, Golestan Hospital, Ahvaz Jondishapur University of Medical Sciences, Ahvaz, Iran

Corresponding Author:

Mohammad Pedram, MD;
Professor of Pediatrics Hematology-
Oncology

Tel: (+98) 611 374 32 85

Email: m_pedram_2007@yahoo.com

Received: 2 Jan. 2012

Accepted: 18 Feb. 2012

Iran J Cancer Prev 2013;3:174-6

Introduction

Neuroblastoma is the most common extracranial solid tumor in children, accounting for 8% to 10% of all childhood cancers [1-4].

A tumor mass can occur anywhere along the sympathetic nerve crest pathway [2].

Therefore, a wide variety of tumor locations and clinical presentations have been described [5] but only 2% of all neuroblastoma arise in the brain [6]. The most common malignant brain tumor of childhood is Medulloblastoma [1, 2]. Medulloblastoma, medullopithelioma, and neuroblastoma are designated in the WHO classification as embryonic and cytologically pluripotent tumors. Microscopically, medulloblastomas exhibit highly variable histological features, most frequently appearing as an infiltrative, extremely undifferentiated, cellular neoplasm [3, 5]. The cells have carrot - shaped or ovoid nuclei with coarse dark chromatin and scant or no visible cytoplasm. Mitoses and necrosis are highly variable. Homer – wright rosettes, the core of which is formed or tenuous fibrillated processes, may be present. Exceptionally, neurons in various stages of maturation are observed. When matured cells are present at the site of cerebellum, the tumor maybe classified as cerebellar ganglioneuroblastoma.

When they form a lobulated pattern with cells streaming in a fine fibrillated background, they are

designated cerebellar neuroblastoma [1, 7, 8]. Review of epidemiologic studies and case reports revealed that there is not a reported case of cerebellar neuroblastoma as a primary CNS tumor in Iran [9-11]. Here, we describe a rare case with cerebellar mass, which pathological diagnosis was cerebellar neuroblastoma.

Case Report

We report a patient with primary cerebellar neuroblastoma. A 2.5-year-old boy was admitted to our hospital because of nausea and vomiting in the morning, headache, ataxia, poor balance and torticollis. The preoperative routine complete blood count , clotting profiles , electrolytes , sequential multiple analysis for chemistry , and the urine analysis findings were all within the normal limits . A brain CT scan revealed a well defined hyperdense mass in cerebellar vermis compressing forth ventricle with obstructive hydrocephaly, compatible with medulloblastoma (Figure 2). A microscopic suboccipital craniectomy was performed and after complete resection of the tumor, a ventriculoperitoneal shunt was inserted.

The pathologist reported a lesion composed of small, dense and round cells with hyperchromatic nucleus and scanty cytoplasm. The lesion arranged in sheets and prevascular accumulation numerous foci of small cells with few mitotic figures. There were necrosis and

hemorrhagia. Also lobulated tumor cells were arranged in groups (islands separated by few fibrous stroma). Parallel patterns were seen in some foci of tumor cells. Also cells with vesicular nuclei were seen (Figure 2). These findings established the diagnosis of neuroblastoma. Immuno-Histo-Chemistry (IHC) showed a strong positivity for Neuron-Specific Enolase (NSE).

During this hospital admission, postoperative systemic examination which included bone survey, bone marrow aspiration, abdomino-pelvic CT scan and MRI of the neuroaxis revealed no other evidence of

tumor. Also cytological examination of cerebrospinal fluid was normal. After surgery we began chemotherapy with a combination of Cisplatin, Ara-c, Vincristine, Hydroxyurea, Lamustin, Procarbazine, Cyclophosphamide and Methyl prednisolon (8 at 1 protocol) every four weeks for 12 courses. Follow up examination revealed a profound delay in mental development but brain MRI performed 12 months after surgery revealed no evidence of tumor recurrence. The patient is presently 3.5 years old and his chemotherapy is finished and he is stable with no sign of relapse.

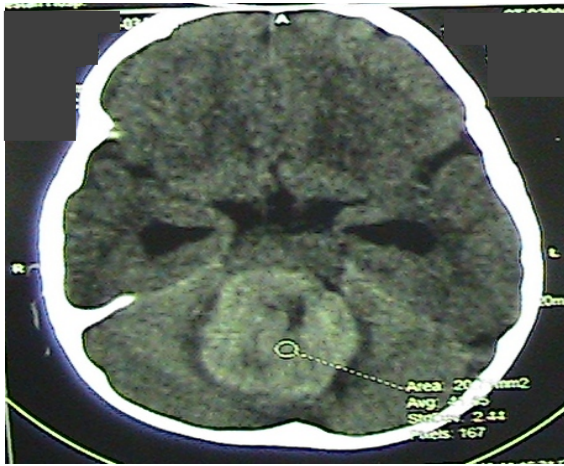

Figure 1. This figure shows brain CT scan at the time of diagnosis.

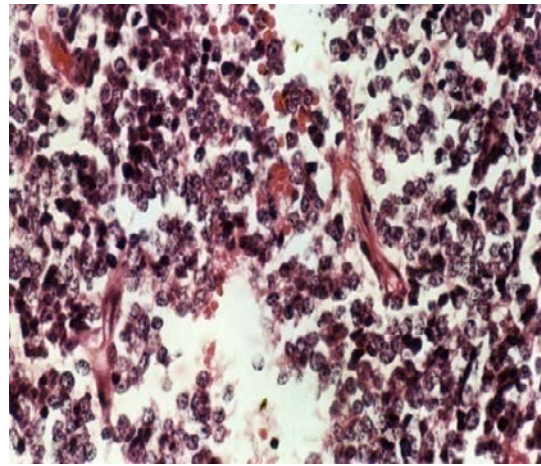


Figure 2. This figure shows pathological slide of tumor (H&E staining).

Discussion

Neuroblastoma is an enigmatic tumor in its clinical and biologic behavior [1]. Embryonal tumors or Primitive Neuroectodermal Tumors (PNET) are the most common groups of malignant CNS tumors of childhood, accounting for 20 – 25 % of pediatric CNS tumors [3]. Primitive neuroepithelial tumors of the CNS, with few or absent foci of cellular differentiation, are called primary cerebral neuroblastoma or medulloblastoma depending on a supra–or infratentorial location of the mass, respectively [1]. A wide variety of tumors are known to occur in the cerebellum and many of these are referred to as medulloblastoma [12]. Medulloblastoma, accounting for 90% of embryonal tumors, is a cerebellar tumor [4]. Their cells are primitive or poorly differentiated and are considered to be of embryonic origin [13]. Its differentiating capacity is one of disputes. Many researchers have not observed the ultrastructural characteristics of neuronal differentiation in medulloblastoma [13]. Yagishita et al. examined a series of medulloblastomas by histological and

immunohistochemical techniques and proposed the hypothesis that medulloblastoma was a stem–cell lines, astrocytic, ependymall, neuronal and oligodendroglial although "cerebellar neuroblastoma" could arise from differentiation of a medulloblastoma along neuroblastic lines [14,15]. Cerebellar "neuroblastomas" are extremely rare [15]. There are a few reports of cerebellar neuroblastoma in the papers. Shuji Nishio et al. (2000) reported a case of cerebellar neuroblastoma in an infant separately. This tumor displays a better prognosis than those with classical or desmoplastic medulloblastoma. The optimal treatment for patients with this tumor, however, remains uncertain. This tumor tends to occur in young children particularly in infants, and this further makes the treatment problematic [16]. Our patient was treated by total removal of the tumor followed by chemotherapy. He was survived one year after operation without recurrence.

Acknowledgment

We appreciate all staff in oncology ward of Shafa Hospital, neurosurgery ward in Golestan Hospital, Dr. Iran Rashidi in pathological laboratory of Shafa Hospital and Dr. Kaveh jaseb in Shafa oncology ward.

Conflict of Interest

There is no conflict of interest in this study.

Authors' Contribution

Majid Vafaei wrote the case report. Kiavash Fekri and Sabahat Haghi contributed to the literature review, discussion and patient follow up. Iran Rashidi contributed to the pathological findings. Chia Pirooti drafted the neurosurgical findings of the case. Mohammad Pedram performed supervision and final edit of the paper.

References

- Garrett MB, John MM. Neuroblastoma :Pizzo PA , Poplack DG , Principles and practice of pediatric oncology , 5th edition . Philadelphia: Lippincot – Raven ; 2006 .933-62.
- Lanzkowsky P. Nerublastoma: Manual of pediatric hematology and oncology. 5th ed. 2004;530-47.
- Muralium. Chintagumpala. Malignant brain tumors. Oski's pediatrics. Principles and practice . 4 th edition. Lippincott Williams and Wilkins. 2006;1771- 5.
- Johnn LA. Neuroblastoma. Kliengman , Behrman , Jenson , stanton, Nelson text book of pediatrics , 18 th edition ,Saunders Elsevier company. 2007; 2137-40.
- Tatis N, Tavuz M, Reis A. primary cerebral neuroblastoma: a case Treated with adjuvant chemotherapy and radiotherapy . The Turkish Journal of pediatrics. 2004;46:182-5.
- Polat P, Kuntarci M, Eren S, Suma S. Primary cerebral neuroblastoma. JBR-BTR. 2005;66: 148- 9.
- Powers JM, Horoupian D. Disease of the nervous system and sensory organs : Anderson's pathology. Ten th edition. Mosby. 1996;26: 93-2831.
- Brandis A, Heyer R, Hori A, Walter GF. cerebellar neuroblastoma :An important differential diagnosis from cerebellar neuroblastoma and medulloblastoma. Neuropediatrics 1997;28(4):235-8.
- Alimohamadi SM, Ghodsi SM, Ketabchi SE. Epidemiologic patterns of primary brain tumors in Iran. Asian Pac J Cancer Prev. 2008;9(2):361-2.
- Mehrazin M, Rahmati H,Yavari P. Epidemiology of primary intracranial tumors in Iran, 1978-2003. Asian Pac J Cancer Prev. 2006;7(2):283-8.
- Miabi Z, Midia M, Midia R. EVALUATION OF PEDIATRIC INTRACRANIAL NEOPLASM IN TABRIZ, IRAN. Acta Medica Iranica. 2007;45(6):458-65.
- Yungshin W, Laufer H, Lee YC , Aftalion B, Hirano A, Zimmerman HM. Fine structure of a cerebellar neuroblastoma. Acta neuropath (Berl).1978;42:11-13.
- Yagishita S, Itoh Y, Chiba Y, Yamashita T, Nakazima F, Kuwabara T. Cerebellar neuroblastoma. Alight and ultrastructural study. Acta neuropath. 1980;50(2):139-142.
- Yagishita S, Itoh Y, Chiba Y, Kuwana N. Morphological investigations on cerebellar "neuroblastoma" group. Acta neuropath. 1982;56(1):22-8.
- Pearl GS, Tuke Y. cerebellar "neuroblastoma" nosology as it relates to medulloblastoma. Cancer.1981;47:772-9.
- Nishio Sh, Inamura T, Morioka T. cerebellar neuroblastoma in an infant . Clinical neurology and neurosurgery. 2000;102(1):52-7.