

# Lymph Node Metastasis in Gastrointestinal Stromal Tumor (GIST): to Report a Case

Amin Shafizad<sup>1</sup>, Mohammad Mohammadianpanah<sup>2</sup>, Hamid Nasrolahi<sup>2</sup>, Maral Mokhtari<sup>3</sup>, Seyed Abdollah Mousavi<sup>4</sup>

## Abstract

The Gastrointestinal Stromal Tumor (GIST) is a rare mesenchymal tumor of gastrointestinal (GI) tract. This tumor has tendency to liver metastasis and peritoneal recurrence, however; the primarily lymph node involvement or metastasis is rare. Here we reported a 17-years-old girl with multifocal gastric GIST and multiple lymph node involvement at presentation and recurrence in celiac lymph nodes. We also review some case reports on lymph node metastasis in GIST.

**Keywords:** Gastrointestinal Stromal Tumors; Lymph Nodes; Neoplasm Metastasis

**Please cite this article as:** Shafizad A, Mohammadianpanah M, Nasrolahi H, Mokhtari M, Mousavi SA. Lymph Node Metastasis in Gastrointestinal Stromal Tumor (GIST): to Report a Case. *Iran J Cancer Prev.* 2014; 7(3):171-4.

## Introduction

The Gastrointestinal Stromal Tumor (GIST) which mostly arises from the stomach is the most common mesenchymal tumor in alimentary tract. The origin of this tumor is the Interstitial Cells of Cajal (ICC) [1]. This neoplasm is uncommon and its incidence is about 10-20 patients per million and most occurs in patients aged more than 50 years, although even in newborns and childhood has been reported [2, 3]. Surgery with optimal tumor resection is the mainstay of curative treatment. Due to the rarity of nodal metastasis, Lymph Node (LN) dissection is not routinely performed [4]. We describe here a young girl who presented primarily with lymph node metastases of a gastric GIST.

## Case Report

A 17-years-old girl presented with a 2 months history of abdominal pain, early satiety, anemia and two episodes of hematemesis before referring to the gastroenterologist. An upper gastrointestinal endoscopy showed multiple umbilicated polypoid lesions in antrum, the body and cardia. An Endoscopic Ultrasound (EUS) subsequently revealed an 8 cm extraluminal mass with invasion to the gastric wall (Figure 1). In addition, multiple perigastric and lymphadenopathies were seen (Figure 2). A fine needle aspiration from the lesion

1. Dept. of Radiation oncology, Hormozgan University of Medical Sciences, Bandar Abbas, Iran

2. Dept. of Radiation oncology, Shiraz University of Medical Sciences, Shiraz, Iran

3. Dept. of Pathology, Shiraz University of Medical Sciences, Shiraz, Iran

4. Dept. of Pathology, Hormozgan University of Medical Sciences, Bandar Abbas, Iran

### Corresponding Author:

Hamid Nasrolahi, MD;

Tel: (+98) 711 6474320

Email: nasrolahi.hamid@gmail.com

Received: 7 June 2014

Accepted: 15 Sep. 2014

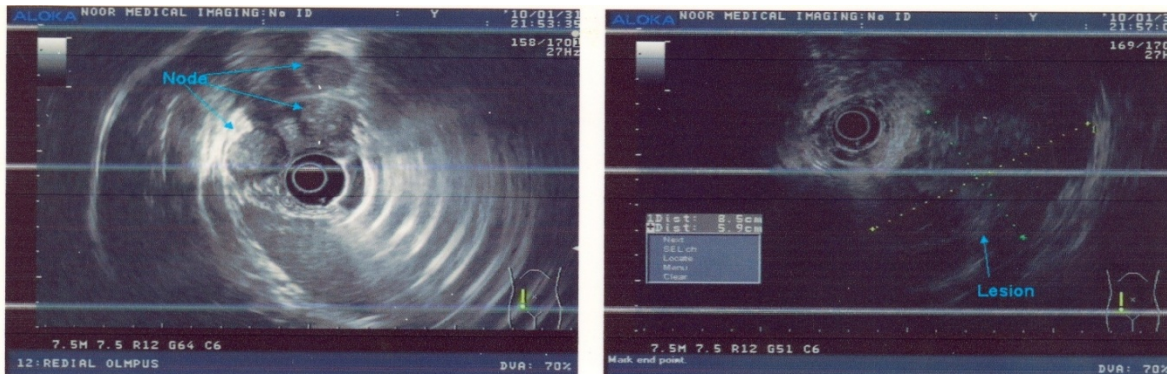
**Iran J Cancer Prev. 2014; 3:171-4**

disclosed malignancy. The patient subsequently underwent total gastrectomy and omentectomy. The pathologic examination revealed multifocal high-grade GIST with involvement of 3 perigastric lymph node (Figure 3). Immunohistochemical staining for CD117 (c-KIT) and CD34 confirmed the diagnosis of lymph node metastasis (Figures 4 and 5). At present, she is well and receiving Imatinib for her regional recurrent disease.

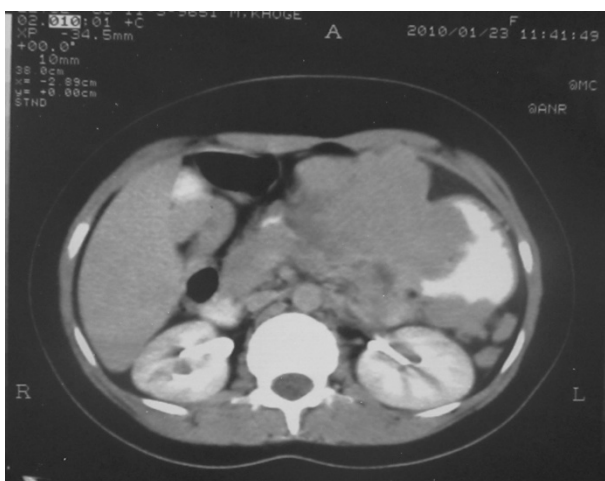## Discussion

GISTs are uncommon tumors of the gastrointestinal tract. This neoplasm is more common in the 6<sup>th</sup> and 7<sup>th</sup> decades of life and mostly located at stomach [5]. Pain, abdominal discomfort and GI bleeding are the most reported complaints [4]. Our patient presented with pain and bloody vomiting.

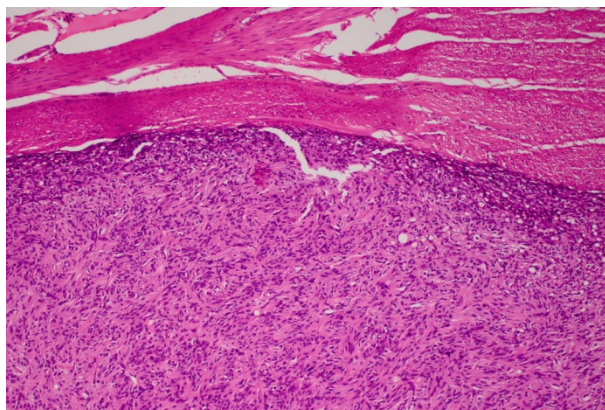
The main treatment is surgical tumor removal [1]. The completeness of surgical resection is a major prognostic factor [6]. But some authors suggested size of the tumor is more important than completeness of surgery [7]. After complete tumor removal, recurrence is not so rare, peritoneal surface and liver parenchymas are common metastasis sites. In large studies on GIST survival, no plateau was seen that indicating no cure is achievable. Although the recurrence risk is not so small, neither



**Figure 1.** A large extraluminal inhomogeneous mass lesion adjacent to the stomach which invades the gastric wall. Multiple large perigastric and celiac lymph nodes are also seen.



**Figure 2.** Axial contrast-enhanced CT scan of the upper abdomen shows a large gastric mass associated with regional lymph node involvement.



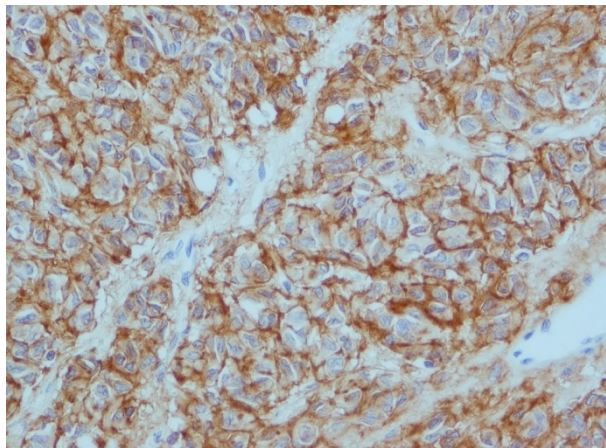
**Figure 3.** GIST penetrating the muscularis propria of the stomach wall, hematoxylin and eosin, x100.

chemotherapy alone nor radiotherapy alone are effective in tumor control and survival prolongation [4, 6].

Most of the patients with GIST have an activating mutation in stem cell receptor KIT. This mutation is a target for the first receptor tyrosine kinase inhibitors. Imatinib and sunitinib are two tyrosine kinase inhibitors that have been approved for the treatment of advanced GIST [5]. Complete surgical resection and tumor grade are the most important prognostic factors. Mitotic count per 10 high power field (HPF) is the limit. One mitoses per 10 HPF is limit. Above and below this cut-off level is called high or low grade tumor [4]. Tumor size is also an important prognostic factor and patients with tumor size  $\leq 5$ cm, 5-10 cm and  $>10$  cm are considered as low, intermediate and high risk groups [2].

Due to low risk of initially nodal involvement and recurrence, there is no indication for routine lymphadenectomy. This procedure should be performed when they are suspicious to be affected by tumor cells. Naguib et al. in a report on 19 patients with gastric GIST had performed lymph node dissection for 5 cases. The reason for dissection was gross lymph node enlargement and none of nodes were involved [1, 7].

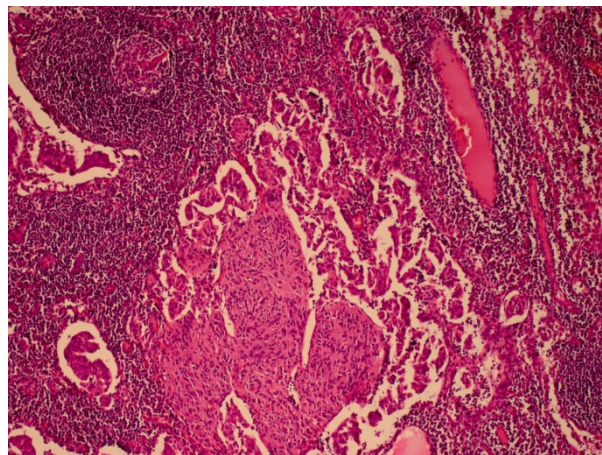
Agaimy and Wunsch in 2009 found 2 cases of lymph node involvement among 210 patients. One of them had Carney syndrome. They performed a review on 699 patients and showed some attractive conclusions. The rate of lymph node involvement was 1%. Those with lymph node involvement were about 20 years younger than others without lymph node metastasis and male-to-female ratio was 1 to 3. In addition, those patients with lymph node metastasis had lower rate of mutation in



**Figure 4.** Membranous Immunoreactivity of C-kit (CD 117) in GIST, x400.

KIT/PDGFR. Tumors that were located in distal of stomach and with epithelioid histology also had higher rate for lymph node spread [8].

There is some evidence that lymph node metastasis in soft tissue sarcoma harbor a poor prognosis [9]. Although GIST like sarcoma is a mesenchymal tumor, lymph node metastasis is not related to poor prognosis. Valadao et al. in a small study on 29 patients, 3 cases had lymph node metastasis that no negative affect on prognosis [10]. They concluded only size and grade were prognostic factors. However, Agaimy and Wünsch argue this idea and believe more studies are needed to draw a conclusion [8].



**Figure 5.** Lymph node shows metastatic involvement by GIST, Hematoxylin and eosin, x100.

Prakash *et al.* in a review on 15 cases aged less than 30 years old with GIST found in patients who were less than 18 years; there were 3 cases with lymph node metastasis. In one case, lymph node metastasis was primarily and in 2 cases lymph node involvement was with recurrence. All cases with lymph node metastasis were female. They concluded that the GIST in patients who are <18 years old has different clinical and genetic aspects. Although it is believed that a similar clinical course in adults and pediatric patients, some authors concluded GIST is more indolent in pediatric population. In addition, between 18 to 30 years old the results were not so conclusive [3, 11].

Table 1. Some other reports on GIST with lymph node metastasis

Authors	Age/ Gender	Location	Tumor size	Lymph node (LN) Metastasis	Site of distant metastasis
Sato [12]	78/F	Stomach	4 cm	1 +ve LN	Liver
Sato [12]	40/F	Stomach	2.5 cm	3+ve LN from 5 LN	Liver
Aras Emr canda [1]	32/F	Stomach	8cm	7 +ve LN of 12 LN	-
Qin Zhang [13]	60/M	Stomach	4cm	Perigastric and Inguinal LN metastasis	Liver
Dina El Demellway [14]	79/F	Small bowel	8.5 cm	Data not available	Data not available
Vassos [15]	76/M	Ileum	20 cm	Inguinal Lymph Node Metastasis	No
Vassos [15]	35/M	Stomach	15 cm	celiac trunk and in the splenic hilum	Axillary and other Organs
This report	17/F	Stomach	8 cm	3 perigastric lymph node	Local recurrence

In the literature review we found the rarity of lymph node metastasis in patients with GIST. Table 1 showed the data of 5 case reports describing lymph node metastasis in patients with GIST.

## Conclusion

Due to low incidence of GIST and infrequent tendency to lymph node metastasis, more studies are needed to disclose the clinical significance of lymph node metastasis in this neoplasm. It may be logical to be concerned to lymph node involvement in younger patients.

## Acknowledgment

We would like to thank Miss Vale Mesbah and Mr Mohammad Reza Zare for preparing this manuscript.

## Conflict of Interest

The authors have no conflict of interest in this study.

## Authors' Contribution

Amin Shafizad, Mohammad MohammadianPanah, Maral Mokhtari, Seyed Abdollah Mousavi and Hamid Nasrolahi designed and wrote this article. All authors read and approved the final manuscript.

## References

1. Canda AE, Ozsoy Y, Nalbant OA, Sagol O. Gastrointestinal stromal tumor of the stomach with lymph node metastasis. *World J Surg Oncol*. 2008; 6:97.
2. Miettinen M, Lasota J. Gastrointestinal stromal tumors: pathology and prognosis at different sites. *Semin Diagn Pathol*. 2006; 23(2):70-83.
3. Benesch M, Wardelmann E, Ferrari A, Brennan B, Verschuur A. Gastrointestinal stromal tumors (GIST) in children and adolescents: A comprehensive review of the current literature. *Pediatr Blood Cancer*. 2009; 53(7):1171-9.
4. Pierie JP, Choudry U, Muzikansky A, Yeap BY, Souba WW, Ott MJ. The effect of surgery and grade on outcome of gastrointestinal stromal tumors. *Arch Surg*. 2001; 136(4):383-9.
5. Blay JY. Pharmacological management of gastrointestinal stromal tumours: an update on the role of sunitinib. *Ann Oncol*. 2010; 21(2):208-15.
6. DeMatteo RP, Lewis JJ, Leung D, Mudan SS, Woodruff JM, Brennan MF. Two hundred gastrointestinal stromal tumors: recurrence patterns and prognostic factors for survival. *Ann Surg*. 2000; 231(1):51-8.
7. Naguib SF, Zaghloul AS, El Marakby H. Gastrointestinal stromal tumors (GIST) of the stomach: retrospective experience with surgical resection at the National Cancer Institute. *J Egypt Natl Canc Inst*. 2008; 20(1):80-9.
8. Agaimy A, Wünsch PH. Lymph node metastasis in gastrointestinal stromal tumours (GIST) occurs preferentially in young patients < or = 40 years: an overview based on our case material and the literature. *Langenbecks Arch Surg*. 2009; 394(2):375-81.
9. Fong Y, Coit DG, Woodruff JM, Brennan MF. Lymph node metastasis from soft tissue sarcoma in adults. Analysis of data from a prospective database of 1772 sarcoma patients. *Ann Surg* 1993; 217(1):72-7.
10. Valadão M, de Mello EL, Lourenço L, Vilhena B, Romano S, Castro Ldos S. What is the prognostic significance of metastatic lymph nodes in GIST? *Hepatogastroenterology*. 2008; 55(82-83):471-4.
11. Prakash S, Sarran L, Socci N, DeMatteo RP, Eisenstat J, Greco AM, et al. Gastrointestinal stromal tumors in children and young adults: a clinicopathologic, molecular, and genomic study of 15 cases and review of the literature. *J Pediatr Hematol Oncol*. 2005; 27(4):179-87.
12. Sato T, Kanda T, Nishikura K, Hirota S, Hashimoto K, Nahagawa S, et al. Two cases of gastrointestinal stromal tumor of the stomach with lymph node metastasis. *Hepatogastroenterology*. 2007; 54(76):1057-60.
13. Zhang Q, Yu JW, Yang WL, Liu XS, Yu JR. Gastrointestinal stromal tumor of stomach with inguinal lymph nodes metastasis: a case report. *World J Gastroenterol*. 2010; 16(14):1808-10.
14. El Demellawy D, Shokry P, Ing A, Khalifa M. Polypoid gastrointestinal stromal tumor of small bowel metastasizing to mesenteric lymph nodes: a case report. *Pathol Res Pract*. 2008; 204(3):197-201.
15. Vassos N, Agaimy A, Hohenberger W, Croner RS. Extraabdominal lymph node metastasis in gastrointestinal stromal tumors (GIST). *J Gastrointest Surg*. 2011; 15(7):1232-6.