

Inflammatory Myofibroblastic Tumor of Salpinx: a Very Rare Case Treated with a Less Aggressive Method

Fatemeh Homaei-Shandiz¹, Reza Jafarzadeh-Esfehani², Nasrin Moazzen³, Amir Amirabadi⁴

Abstract

Inflammatory pseudotumour describes as a wide range of neoplastic and reactive lesions. One of the rare presentations of these tumors is found in the salpinx. This case report characterizes a thirty six year old woman with a history of left sided abdominal pain for a few months. Further examinations revealed that she had a complex cyst in her left salpinx. The patient had normal levels of tumor markers such as CA125, Alfa Fetoprotein (AFP), and Human Chorionic Gonadotropin (hCG), while other paraclinical test were in normal values. Additionally The patient underwent left salpingectomy by a gynecologist. The pathological diagnosis of the lesion was inflammatory myofibroblastic tumor (IMT). In immunohistochemistry the tumor stains was moderately positive in anaplastic lymphoma kinase (ALK) and also actin positive. Total resection of tumor was performed with no complications and remained disease free during follow up for 40 months. Although Inflammatory Myofibroblastic Tumor (IMT) is benign in nature, but in order to improve the prognosis, this tumor requires low intensity surgical treatment.

Keywords: Inflammatory myofibroblastic Pseudo tumor; Salpinx

Please cite this article as: Homaei-Shandiz F, Jafarzadeh-Esfehani R, Moazzen N, Amirabadi A. Inflammatory Myofibroblastic Tumor of Salpinx: a very rare case treated with a less aggressive method. *Iran J Cancer Prev.* 2014;7(4):244-7.

Introduction

Inflammatory pseudotumors describe as a wide range of neoplastic and reactive lesions such as inflammatory myofibroblastic tumor (IMT) and inflammatory pseudotumors of spleen, lymph node and orbit [1]. Inflammatory myofibroblastic tumors arise in a variety of locations such as brain, bone, larynx, stomach, large intestine, small intestine, lung, liver, mediastinum, retroperitoneum and omentum which are mainly diagnosed in the first two decades of life [1-4].

In this case report, a very rare case of IMT arised from the salpinx was identified interestingly we could treat this tumor by a less aggressive method.

Case Report

The patient was a thirty six years old woman with a history of left sided abdominal pain for a few months before treatments. In her abdominal ultrasound examination she had a complex cyst with the diameter of 60×55×40 millimeters in left salpinx.

1. Associated Professor of Radiation Oncology, Solid tumors Research Center, Mashhad University of Medical Sciences, Mashhad, Iran
 2. Medical Student, Sabzevar University of Medical Sciences, Sabzevar, Iran
 3. Fellow of Allergy and Clinical Immunology, Mashhad University of Medical Sciences, Mashhad, Iran
 4. Radiation Oncologist, Solid tumors Research Center, Mashhad University of Medical Sciences, Mashhad, Iran

Corresponding Author:

Amir Amirabadi, MD;
 Radiation Oncologist
 Tel: (+98) 5115224472
 Email: Amirabadia871@mums.ac.ir
 Received: 25 Apr. 2014
 Accepted: 22 Jun. 2014
Iran J Cancer Prev. 2014; 4:244-7

The patient had normal levels of CA125, AFP and HCG and Para-clinical test. The patient underwent left salpingectomy by a gynecologist before referral to our center.

The pathological diagnosis of the lesion was inflammatory myofibroblastic tumor. In immunohistochemistry (Figure 1) the tumor stains was moderately positive with anaplastic lymphoma kinase (ALK) and actin positive with. Based on the pathologic findings and according to related reports, we decided completing surgical treatment of the patient as a complete resection of the left adnexa. We recommend only a unilateral resection of left adnexa because of low malignant potential of this special tumor. Fortunately in second look surgery no residual tumor was detected in left adnexa. In post operation CT scan there was no finding of disease in other sites of body. The patient was recommended to have a close follow up after such surgery. A simple cyst of 40 millimeters in the greatest dimension was detected in the ultrasonography of her right ovary after eight months. Since that cyst was asymptomatic and simple, oral contraceptive was

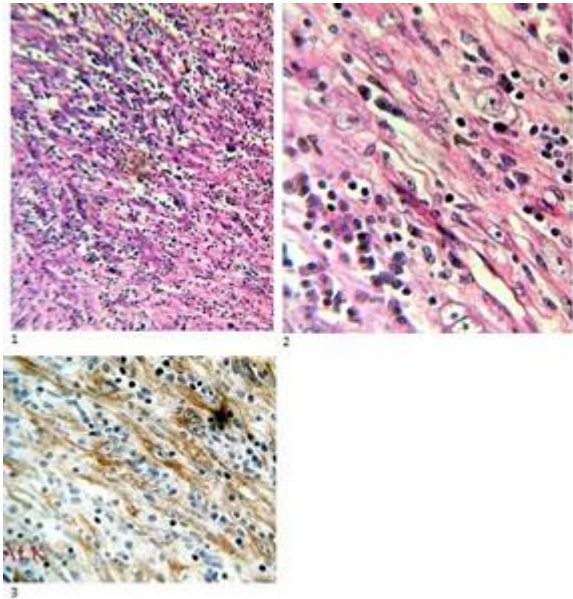


Figure 1. Patients tumor samples and immunohistochemistry staining. 3rd image is taken from an ALK stained specimen.

prescribed and the patient was also recommended to continue close follow up every 2 months. The lesion was dwindled and fortunately she was disease free in last visit. The time interval between the beginnings of follow up is 58 months till writing this report.

Discussion

Inflammatory myofibroblastic tumor (in past also called inflammatory pseudotumor) arises from multiple locations. These tumors suggest a chronic inflammatory condition [5]. In 1939 First tumor was observed in lung and named as IMT by Umiker et al. [6] IMT is microscopically characterized by variable combinations of proliferating fibroblasts or myofibroblasts ,inflammatory cells and eosinophils which rarely metastasizes [3, 6-8]. Although it doesn't show a malignant behavior with its low proliferation rate but is able to grow by infiltration [8]. As half of IMT tumors express anaplastic lymphoma kinase (ALK1) protein, Immunohistochemistry can be helpful in making a correct diagnosis [3, 7]. Several benign fibroblastic lesions such as nodular fasciitis, leiomyoma, desmoid tumor and myofibroblastosis are in differential diagnosis with IMT. ALK expression made distinguish of IMT from these conditions easier [7, 9]. Various pathogenic backgrounds such as infections, neoplastic and autoimmune processes have been reported as initiating factors of IMT but

the exact ethology is still unknown [6]. Infection, biliary obstruction, abscesses, primary sclerosing cholangitis, primary biliary cirrhosis, LgG4-related disease, chron diseases, traumatic origin and allergies are suggested as possible causes [5, 10, 11]. Morphologic appearance of IMT is consisting of spindle cells in a myxoid background with the immunoprofile of both epithelial and smooth muscle markers [12]. These tumors are classified as tumors of intermediate biological potential by world health organization classification because of tendency for a small risk of metastases and local recurrence [13]. Rearrangements of the ALK locus on chromosome 2p23 in 50% of IMTs support the neoplastic nature of these lesions [1, 14]. Although ALK presentation in IMT is more common in younger people but it's not restricted to this population. Tumor size and mitotic activity seems not to have correlation with outcomes [1]. Grossly the maximum tumor size is up to 12 cm in diameter. Tumor cut surface is tan or white and often mucoid. IMT may arise in premenopausal women and children [15]. In patient with extensive disease and oncogenic ALK activation, in case of difficult local control, therapeutic ALK inhibition can be helpful [16]. As other studies mentioned, IMT of uterus is very rare occasion [12, 14, 17-19, 20-23].

The previous similar case was a 48 year old woman presented with lower abdominal pain and hydroureteronephrosis reported by Gucer et al. (2005). Rectovaginal examination revealed no uterus and adnexal masses. CT scan revealed 5×4cm mass in cervix which had envaded both parametria. Exploratory laparotomy revealed absence of uteri and adnexa. The patient underwent right salpingo-oophorectomy and subtotal abdominal hysterectomy with complete dissection of pelvic lymph nodes as well as left nephrectomy [24]. Both parametria and Whole cervix were infiltrated by tumor. Tumor characterized by proliferation of fibroblastic-like spindle cells and defuses infiltration of lymphocysts and plasma cells. Immunohistochemical staining showed polyclonal infiltration [24]. There was no sign of recurrent disease in 8 months follow up [24]. In another study Masayuki Shintaku and Akiko Fukushima (2006) reported a 63 year old woman with complaint of lower abdominal distension [14]. Ultrasound and MRI showed a very high intensity on T2-weighted image with a few thin septa showing a low anterior intensity filling the uterus cavity. These septas were enhanced by gadolinium. Needle biopsy showed several small tissue

fragments occupied by atypical spindle on myxoid background. As the suggested pathological diagnosis was myxoid leiomyosarcoma, total abdominal hysterectomy and bilateral salpingo-oophorectomy were done [14]. The patient was free from recurrence for 8 months. The tumor was approximately 11*6*6cm and was protruded from posterior wall into the uterine cavity. More than half of this yellowish white tumor showed granular or diffuse cytoplasmic immunoreactivity for ALK. Tumor cell were arranged in haphazard fashion and lace-like or reticular arrangement occasionally [14].

Conclusion

Although MIT is one of the rarest tumor, because of its nature is very conclusive. Despite of controversial treatments methods such as radiation therapy or chemotherapy, complete resection is also an effective method. Currently this tumor is believed to be a low grade tumor in spite of a benign lesion that requires low intensity and acceptable prognosis. We wish that our experience would be beneficial for treatment of such patients.

Acknowledgment

None declared.

Conflict of Interest

There is no conflict of interest.

Authors' Contribution

Fatemeh Homaei-Shandiz wrote the study. Amir Amirabadi, Reza Jafarzadeh-Esfehani and Nasrin Moazeen contributed in literature review and writing-up process. All authors read and approved the final manuscript.

References

1. Gleason BC, Hornick JL. Inflammatory myofibroblastic tumors: where are we now? *J Clin Pathol.* 2008; 61(4):428-37.
2. Hayat M. Tumors of the Central Nervous system: Brain Tumors (Part 1). 1st ed. London: Springer; 2011. Vol.3 P.65.
3. Alberto S. Pappo, editor. Pediatric Bone and Soft Tissue Sarcomas. 1st ed. Germany: Pediatric Oncology; 2005. P.144.
4. Kim EY, Lee IK, Lee YS, Yang N, Chung DJ, Yim KI, et al. Inflammatory myofibroblastic tumor in colon. *J Korean Surg Soc.* 2012 Jan; 82(1): 45-9.

5. Berman. Neoplasms: Principles of Development and Diversity. 1st ed. United States of America: Jones and Bartlett Publishers; 2008. P. 55.
6. Palaskar S, Koshti S, Maralingannavar M, Bartake A. Inflammatory myofibroblastic tumor. *Contemp Clin Dent.* 2011; 2(4): 274-7.
7. Ribeiro MC, Lopes LR, de Souza Neto JC, Meirelles LR, de Carvalho RB, Andreollo NA. Rare gastric inflammatory myofibroblastic tumor in an adult woman: a case report with review of the literature. *Case Report Med.* 2012; 2012: 374070.
8. Mizukami H, Yajima N, Wada R, Matsumoto K, Kojima M, Klöppel G, et al. Pancreatic malignant fibrous histiocytoma, inflammatory myofibroblastic tumor, and inflammatory pseudotumor related to autoimmune pancreatitis: characterization and differential diagnosis. *Virchows Arch.* 2006;448(5):552-60.
9. Dani S. Zander, Helmut Popper, Jaishree Jagirdar, Abida Haque, Roberto Barrios, Philip T. Cagle, editors. *Molecular Pathology of Lung Diseases (Molecular Pathology Library)*. 1st ed. New York: Springer; 2007. P.362
10. Binmadi NO, Packman H, Papadimitriou JC, Scheper M. Oral inflammatory myofibroblastic tumor: case report and review of literature. *Open Dent J.* 2011;5:66-70.
11. A Suriawinata, S Thung. *Liver Pathology: An Atlas and Concise Guide*. 1st ed. United States of America: Demos Medical publishing; 2011. P. 168.
12. Fuehrer NE, Keeney GL, Ketterling RP, Knudson RA, Bell DA. ALK-1 Protein Expression and ALK Gene Rearrangements Aid in the Diagnosis of Inflammatory Myofibroblastic Tumors of the Female Genital Tract. *Arch Pathol Lab Med.* 2012;136(6):623-6.
13. Coffin CM, Fletcher JA. Inflammatory myofibroblastic tumour. In: Fletcher CD, Unni KK, Mertens F, editors. *World Health Organization classification of tumours Pathology and genetics of tumours of soft tissue and bone*. Lyon: IARC Press; 2002. P. 91-3.
14. Shintaku M, Fukushima A. Inflammatory myofibroblastic tumor of the uterus with prominent myxoid change. *Pathol Int.* 2006;56(10):625-8.
15. Robert J. Blaustein's *Pathology of the Female Genital Tract*. 5th ed. New York: Springer; 2002. P. 601.
16. Verweij J, Pinedo HM. *Targeting Treatment of Soft Tissue Sarcomas (Cancer Treatment and Research)*. United States of America: Kluwer Academic Publishers 1st ed. P.108
17. Gilks CB, Taylor GP, Clement PB. Inflammatory pseudotumor of the uterus. *Int J Gynecol Pathol.* 1987;6(3):275-86.
18. Kargi HA, Özer E, Gökden N. Inflammatory pseudotumor of the uterus. A case report. *Tumori.* 1995;81(6):454-6.

19. Azuno Y, Yaga K, Suehiro Y, Ariyama S, Oga A. Inflammatory myoblastic tumor of the uterus and interleukin-6. *Am J Obstet Gynecol.* 2003;189(3):890-1.
20. Rabban JT, Zaloudek CJ, Shekitka KM, Tavassoli FA. Inflammatory myofibroblastic tumor of the uterus: a clinicopathologic study of 6 cases emphasizing distinction from aggressive mesenchymal tumors. *Am J Surg Pathol.* 2005;29(10):1348-55.
21. Olgan S, Saatli B, Okyay RE, Koyuncuoglu M, Dogan E. Hysteroscopic excision of inflammatory myofibroblastic tumor of the uterus: a case report and brief review. *Eur J Obstet Gynecol Reprod Biol.* 2011;157(2):234-6.
22. Gupta N, Mittal S, Misra R. Inflammatory pseudotumor of uterus: an unusual pelvic mass. *Eur J Obstet Gynecol Reprod Biol.* 2011 May; 156(1):118-9.
23. Olgan S, Saatli B, Okyay RE, Koyuncuoglu M, Dogan E. Hysteroscopic excision of inflammatory myofibroblastic tumor of the uterus: a case report and brief review. *Eur J Obstet Gynecol Reprod Biol.* 2011;157(2): 234-6.
24. Gücer F, Altaner S, Mülayim N, Yapicier O. Invasive inflammatory pseudotumor of uterine cervix: a case report. *Gynecol Oncol.* 2005;98(2):325-8.