

Perioperative Pain Relief by Thoracic Paravertebral Block for Wide Excision of Chest Wall Mass

Ebrahimi Dehkordy M¹, Mosavi SR²

Abstract

Paravertebral block is an appropriate method for intraoperative and postoperative pain relief in hemithorax operations. Effectiveness of this type of pain management have already been shown in breast surgery. Its effect on controlling chest wall pain is clear and remarkable.

In our case despite of wide extension of lesion and penetration of ulcer to the deep part of thorax after excision, the patient had a very comfortable and painless recovery.

Keywords: Paravertebral block; Perioperative pain; Thoracic wall analgesia

Please cite this article as: Ebrahimi Dehkordy M, Mosavi SR. Perioperative Pain Relief by Thoracic Paravertebral Block for Wide Excision of Chest Wall Mass. Iran J Cancer Prev. 2011;4(3):148-50.

1. Department of Anaesthesia, Shahid Beheshti University of Medical Sciences, Tehran, Iran

2. Cancer Research Center, Shahid Beheshti University of Medical Sciences, Tehran, Iran

Corresponding Author:

Masih Ebrahimi Dehkordy, MD
Associate Professor of Anesthesia

Tel : (+98)21 22 71 8001

Email: masihed@sbsmu.ac.ir

Received: 6 Oct. 2010

Accepted: 20 Jun. 2011

Iran J Cancer Prev. 2011; 3:148-50

Case Report

A 45-year-old woman was admitted to the hospital with a very deep lesion on her left chest wall (figure 1-2). She was very cachectic and smelling pus from her ulcer made her very nervous and frightened.

The appearance of ulcer was purulent and necrotic but there was no evidence of cellulitis or redness around the ulcer.

In physical examination she had no finding except the ulcer mentioned above and severe weight loss which started a couple of years ago.

She had a past history of modified radical mastectomy on the left side 3 years ago and she was referred for postoperative chemo-radiotherapy which was refused by her as she denied her cancer diagnosis till recent year which this horrible ulcer appeared slowly on the previous operation scar on her left chest wall.

Her doctor ordered an MRI of her chest and abdomen and also a routine blood test.

MRI showed a deep penetration of chest wall mass to the pleural layers and extensive erosion of chest wall bone (Figure 3). CBC and blood values didn't show any remarkable changes. She seemed metastasis free. She was a candidate for wide excision of chest wall mass and affected layers.

In the operating room paravertebral block was performed on the left 3rd thoracic vertebral lamina with 15 cc Bupivacaine 0.5 % plus Adrenaline

1:200000 and then patient anesthetized with combination of Propofol 80 mg and Atracurium 20 mg. During anesthesia she took 50 mcg /kg /min Propofol and 2 mcg/kg/min Remifentanyl. Every 25 minutes she took 5 mg Atracurium for muscle relaxation.

Wide excision of the ulcer and affected chest wall was performed and the affected ribs and pleura was removed extensively (Figure 4). The defect was filled with Proline mesh tightly and the right breast was rotated as a graft to the left side and fixed over the site of excision (Figure 5).

She was quiet stable during the operation and then muscle relaxant was reversed at the end of the operation and hypnotic and analgesic infusion was stopped.

She became awake very soon without any pain or discomfort. Her vital signs remained unchanged and she was pain-free until 20 hours after operation. The day after surgery she was able to walk in her room and she had a tolerable postoperative pain with oral analgesic. Chest physiotherapy started with no pain on the second postoperative day. She discharged from the hospital on the 6th postoperative day.

Discussion

Paravertebral analgesia in breast surgery has been done successfully since 1970s. The most brilliant results have been achieved in different studies about

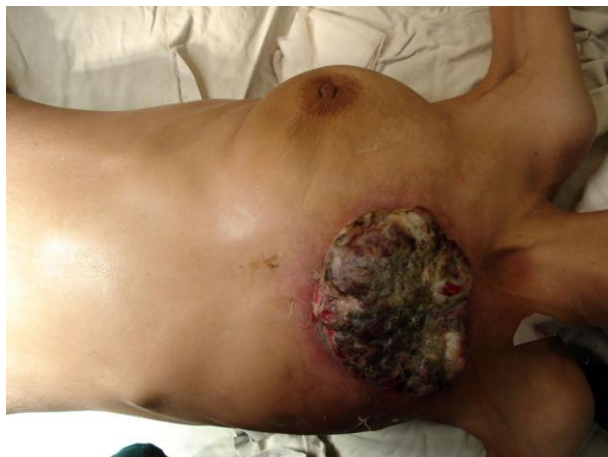

Figure 1. Pre operation ulcer

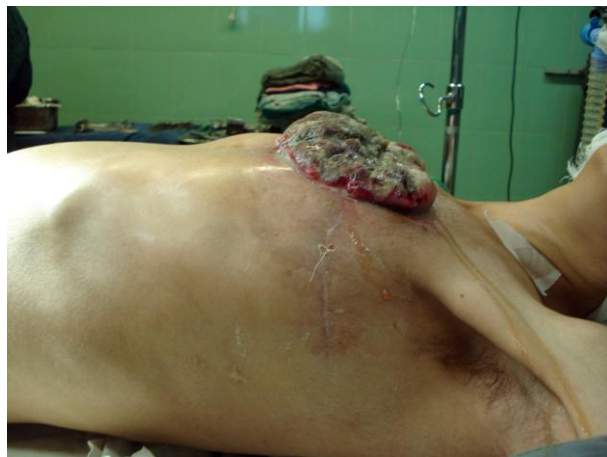

Figure 2. Pre operation ulcer

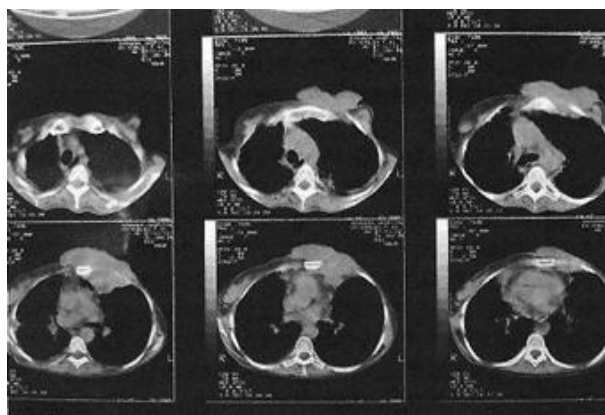


Figure 3. MRI: Deep penetration of ulcer to chest wall layers

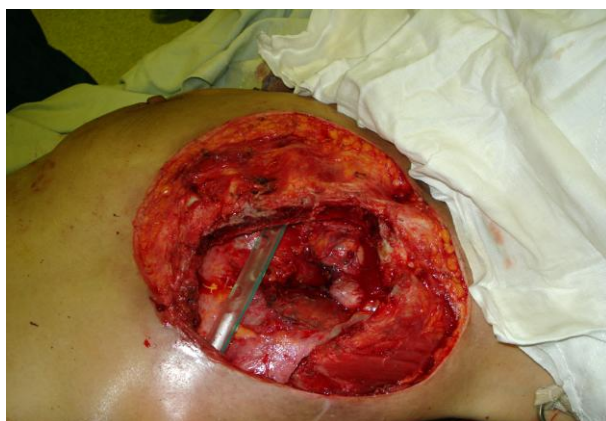

Figure 4. Wide excision of ulcer and chest wall

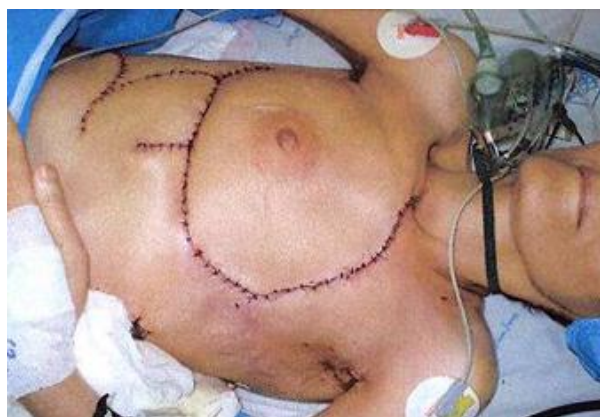

Figure 5. Patient's appearance after extubation

its efficacy on pain management and duration of analgesia [1-9].

This method of pain control can reduce the pain and additional analgesia rarely needs in this

procedure. When we use continuous paravertebral block by insertion of paravertebral catheter we can extend the duration of block until the drainage catheter removal.

In this case in spite of deep penetration of the ulcer and wide excisional surgery only with a single dose of local analgesic in the 3rd thoracic paravertebral space she was remarkably pain free and it was very helpful for her rehabilitation and physiotherapy. She was able to breathe deeply and expand her chest smoothly just after the operation.

Pain control with opioids can delay recovery and rehabilitation in these patients and reduce co-operation and also hospital stay may increase with respiratory complications of opioids. Painless postoperative period in such extensive chest wall operation in this patient reveals efficacy of the method for visceral pain management. This method has less complication but more benefits in hemi-thoracic procedures.

Conclusion

Paravertebral block not only is an appropriate anesthesia method which could decrease hospital stay, hospital costs and postoperative complications but also it is a simple and feasible method in the most cases and can provide a very suitable analgesia for biopsy and operation and postoperative analgesia in hemi-thoracic procedures [3-8].

Acknowledgement

The authors wish to thank Dr Ali Shahabedin for his kind cooperation for providing patient's photos and file information.

Conflict of Interest

Authors did not receive any financial aid or grant for this study.

Authors' Contribution

EDM designed the article and wrote the paper while MSR did the surgical performance.

References

1. Klein A, Steele SM, Georgiade GS, Greengrass RA. Thoracic paravertebral block for breast surgery. *Anesthesia Analgesia*. 2000;90:1402-5.
2. Greengrass R, Steele S. Paravertebral blocks for breast surgeries, *Tech Reg. Anesthesia and pain management*. 1998;2:8-12.
3. CohenAM, Scheaffer N, Chen ZY, Wood WC. Early discharge after modified mastectomy .*The American Journal of Surgery*. 1986;151(4):465-6.
4. Edward MJ, Broadwater JR, Ames FC, Balach CM. Economic impact of reducing hospitalization for mastectomy patients *Ann Surg*. 1988;208(3):330-6.
5. Ketcham AS, Robinson DS, Moffat FL, Tennalt ND. A safe way of diminishing hospital costs *Am Surgery*. 1987;53(3):161-3.
6. Richardson J, Sabanathan S. Thoracic paravertebral analgesia. *Acta anaesthesia Scandinavia*. 1995;39(8):1005-15.
7. Kirvela O, Antila H. Thoracic paravertebral block in chronic postoperative pain .*Reg Anesthesia*. 1992;17(6):348-50.
8. Weltz CR, Greengrass RA, Lyerly HK. Ambulatory Surgical management of breast carcinoma using paravertebral block .*Ann Surgery*. 1995;222(1):19-26.
9. Ebrahimi M, Moradi AR. Paravertebral block in breast surgeries. *Cancer Surgery*. 2009;2(1):67-71.