



Coronary Bifurcation Lesions: Manually Crimped Bifurcation Stent

Bhupesh R Shah ^{1,*}, Harshal Shah ², Darshil Shah ²

¹ Department of Cardiology, Smt. NHL Municipal Medical College Ahmedabad, Gujarat, India

² Smt. NHL Municipal Medical College Ahmedabad, Gujarat, India

*Corresponding author: Bhupesh R Shah, Department of Cardiology, Smt. NHL Municipal Medical College Ahmedabad, Gujarat, India. Tel.: +919825322373, E-mail: bhupesh1@icloud.com

DOI: 10.5812/intjcardiovascpract-131481

Submitted: 19-06-2020

Accepted: 17-07-2020

Keywords: Heart; Coronary Stenosis; Percutaneous Coronary Intervention

© 2018. International Journal of Cardiovascular Practice.

DESCRIPTIVE TEXT

Percutaneous coronary intervention (PCI) for coronary bifurcations has been imaginative, innovative and remains challenging for interventional cardiologists. Recently, the innovative technology is determining the good approach to improve long-term outcomes. This technique is complicated and associated with a risk of restenosis and stent thrombosis even with the current era of a drug-eluting stent. The method of provisional stenting in the patients is the gold standard for coronary bifurcation lesions using the jailed wire technique [1]. Previous study proved that the provisional stenting technique with one-stent has been superior to elective two-stent in terms of peri-procedural myocardial infarction which create it the gold standard approach for coronary bifurcation lesions [2]. Moreover, a protective guide wire is placed into the side branch (SB) before implantation to main vessel stenting because there may be a risk of SB occlusion either owing to plaque or carina shift after stent implantation. Furthermore, the different techniques with implantation of one or two stents have been developed for the treatment of patients with lesion subset [3]. The PCI of bifurcation lesions is still difficult from the main branch (MB) which may lead to acute impairment of coronary blood flow in the SB [4]. In India, many cardiologists are not doing bifurcation stenting, may be due to cost involved in the said

procedure or complexity. We have tried to create a manually crimped bifurcation stent on two balloons of the stents. After inflating MB stent at high pressure on the trolley it was removed from the balloon and threaded on percutaneous transluminal coronary angioplasty wire. The other wire SB was crossed through the strut, usually after 5-6 mm from proximal and hard end to a proximal end, as shown in Figure 1A. Another stent as per the desired size was passed on SB wire to create a culotte pattern and inflated to open the MB strut (3.5 /23 MB, 3.5 /18 SB). Now MB wire was withdrawn from the distal end of the MB stent and pushed towards a proximal end of the MB stent through the SB stent. Now those uninflated stent balloons were passed in the respective stent and simultaneously inflated to create bifurcation stent by the culotte method, as shown in Figure 1B. Stents are well inflated, and both balloons can be easily passed in MB and SB, as shown in Figures 1C-1D. Then stents were crimped to create a customised bifurcation stent. We need to check the feasibility of this manually crimped stent implantation in patients. We may need 7 or 8 French guide as it would be bulkier stent and we are planning to implant this in proximal bifurcation lesions or a large vessel like 3.5 or more.

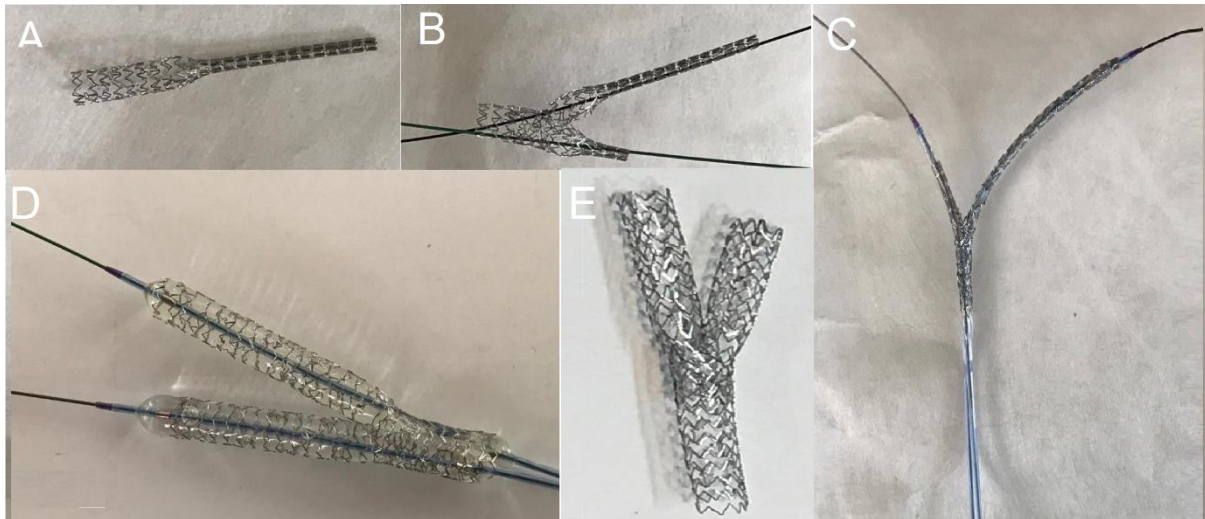


Figure 1. A: Main Branch **B:** Manually to be Crimped Bifurcation Stent on Two Balloons of the Stents **C:** Balloons in Main and Side Branch **D:** Inflated Balloons **E:** Well Expanded

We can prepare a bifurcation stent before the procedure in COVID era to minimise cath time. This can be tried in short left main with narrow angle bifurcation too. We can mount 4 mm stent on 3.5 mm balloon for left main to LAD stenting so as to have less distortion of stent in left main after POT with 4.5 mm balloon and one stent may be enough for cross over stenting.

The bottom line is that the manually crimped bifurcation stent would be a cost-effective alternative for the dedicated bifurcation stents to treat patients with bifurcation lesions. However, this manually crimped bifurcation stent still awaits the outcomes in the patients.

Conflicts of Interest

The authors have none to declare.

Acknowledgments

The author would like to thank Nadeem Sayyed and Priyanka J. Desai for their assistance in the preparation of this manuscript.

REFERENCES

1. Lassen JF, Burzotta F, Banning AP, Lefevre T, Darremont O, Hildick-Smith D, et al. Percutaneous coronary intervention for the left main stem and other bifurcation lesions: 12th consensus document from the European Bifurcation Club. *EuroIntervention*. 2018;13(13):1540-53. doi: 10.4244/EIJ-D-17-00622 pmid: 29061550
2. Nairooz R, Saad M, Elgendy IY, Mahmoud AN, Habash F, Sardar P, et al. Long-term outcomes of provisional stenting compared with a two-stent strategy for bifurcation lesions: a meta-analysis of randomised trials. *Heart*. 2017;103(18):1427-34. doi: 10.1136/heartjnl-2016-310929 pmid: 28314731
3. Sawaya FJ, Lefevre T, Chevalier B, Garot P, Hovasse T, Morice MC, et al. Contemporary approach to coronary bifurcation lesion treatment. *JACC Cardiovasc Interv*. 2016;9(18):1861-78. doi: 10.1016/j.jcin.2016.06.056 pmid: 27659563
4. Milasinovic D, Wijns W, Ntsekhe M, Hellig F, Mohamed A, Stankovic G. Step-by-step manual for planning and performing bifurcation PCI: a resource-tailored approach. *EuroIntervention*. 2018;13(15):e1804-e11. doi: 10.4244/EIJ-D-17-00580 pmid: 29175768