




# Rheumatic Complete Atrioventricular Block: A Case Report

Saousan Serbout <sup>1,\*</sup> , Hamza Choukrallah <sup>1</sup>, Leila Azzouzi <sup>1</sup>,  
Abdenasser Drighil <sup>1</sup>, Rachida Habbal <sup>1</sup>

<sup>1</sup> Department of Cardiology, Ibn Rochd University Hospital, Casablanca, Morocco

\* Corresponding author: Department of Cardiology, Ibn Rochd University Hospital, Casablanca, Morocco. E-mail saousan90@gmail.com

DOI: [10.5812/intjcardiovascpract-131486](https://doi.org/10.5812/intjcardiovascpract-131486)

**Submitted:** 30-01-2020

**Accepted:** 01-03-2020

**Keywords:**

Acute Rheumatic Fever  
Complete Atrioventricular  
Block  
24-hour Electrocardiography  
Salicylate

© 2020. International Journal  
of Cardiovascular Practice.

**Abstract**

Acute rheumatic fever is a well-known disease that is still widely observed in developing countries, including our country Morocco. It is known that the majority of patients diagnosed with acute rheumatic fever display abnormalities of the conduction system; However, there are only a few case reports that describe severe impairment in the electrical conduction system. We describe a 21-year-old man who was diagnosed with acute rheumatic fever with complete atrioventricular block. In our patient, the diagnosis of acute rheumatic fever was established. 24-hour electrocardiography showed a paroxysmic complete atrioventricular block. Penicillin prophylaxis was made, and salicylate treatment in an anti-inflammatory dose was initiated. The electrocardiographic abnormalities of the patient disappeared. Although rare, this diagnosis should be considered in patients with complete heart block, particularly when it is associated with other features of acute rheumatic fever. Conduction disorders associated with acute rheumatic fever often resolve following appropriate treatment without the need for permanent pacemaker placement.

## INTRODUCTION

Acute Rheumatic fever (ARF) is one of the most common cardiovascular diseases in children and young adults. It remains a significant public health problem in developing countries, including our country Morocco. It's caused by an autoimmune response to untreated *Streptococcus pyogenes*. Cardiac involvement during rheumatic fever can lead to chronic rheumatic heart disease, which can cause heart failure, morbidity, and premature mortality [1, 2]. It is especially rampant in the lowest levels of education and the highest poverty, with poor housing conditions, poor nutrition, and inadequate health services [3]. The diagnosis is based on the modified Jones criteria applied to the antecedents; these include arthritis, carditis, subcutaneous nodules, erythema marginatum, and chorea. [4] The first episode of rheumatic fever appears most often between five and 15 years, which is the peak age of streptococcal pharyngitis. Acute rheumatic fever is rare before three years of age, and after 21 years of age. An estimated 15.6 million people are affected worldwide, including 2.4 million children between the ages of 5 and 14 in developing countries. [5] The disease may cluster in families, and it can be seen at an older age

in some countries. It is known that the majority of patients diagnosed with acute rheumatic fever display abnormalities of the conduction system; however, there are only a few case reports that describe severe impairment in the electrical conduction system of the heart. Here we describe a young man who was diagnosed with acute rheumatic fever with complete atrioventricular (AV) block.

## CASE PRESENTATION

A 21-year-old man was admitted with weakness, fever, and polyarthritis. He had tonsillitis two weeks earlier. His vital signs were as follows: body temperature, 38.7°C; respiration rate, 18 breaths/min; pulse, 58 b.p.m; and systolic/diastolic blood pressure, 110/60 mmHg. Physical examination was regarded as a grade 2/6 systolic murmur at the left upper parasternal area, a diastolic murmur at the 3rd left intercostal space, and bradycardia. There are no signs of heart failure. The rest of the clinical examination was also reasonable. The laboratory findings of the patient were reported as follows: hemoglobin 14.4 g/dL; leukocyte count 12030 mm<sup>3</sup>; C - reactive protein (CRP): 219 mg/dL;

erythrocyte sedimentation rate (ESR) 86 mm/h; Anti-Streptolysin O (ASLO) titer was positive 716 U/mL; thyroid-stimulating hormone: 3 uIU/mL (0.27-4.2 uIU/mL). The chest X-ray was unremarkable. The electrocardiogram of the patient showed bradycardia with complete AV Block. Also, continuous

electrocardiography monitoring showed a regression of complete heart block. 24-hour electrocardiography showed a paroxysmic complete AV block (Fig 1). Transthoracic echocardiography of the patient showed a moderate mitral and aortic regurgitation and an ejection fraction of 66% (Figs 2 and 3).

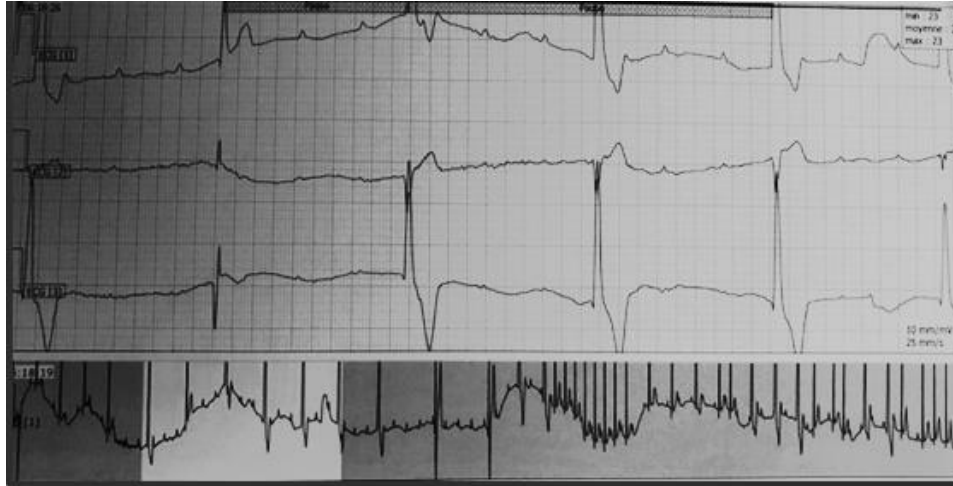

Figure 1. Complete atrioventricular block observed on 24-hour electrocardiography.

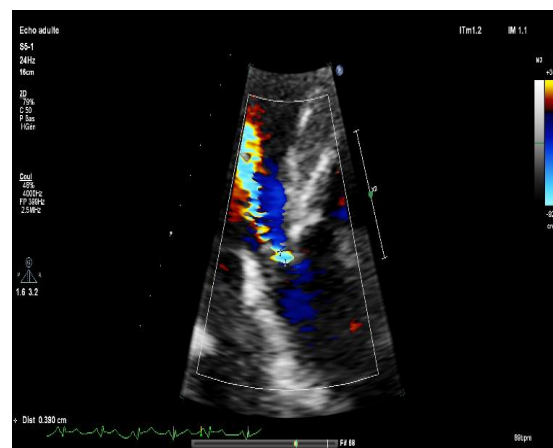


Figure 2. Transthoracic echocardiogram apical four-chamber and parasternal long-axis view showed a moderate aortic regurgitation

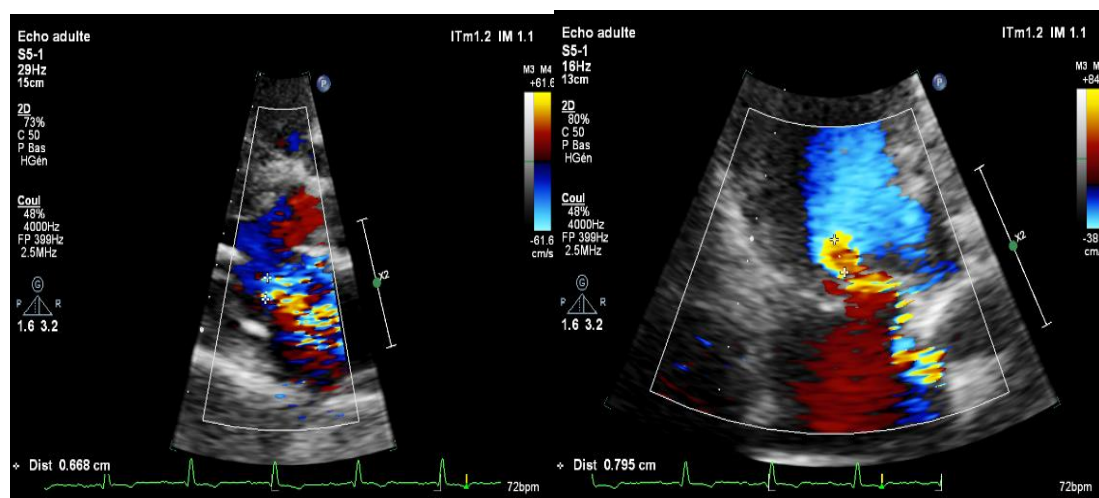


Figure 3. Transthoracic echocardiogram apical four-chamber and parasternal long-axis view showed a moderate mitral regurgitation

The patient had two major components (carditis and migratory arthritis) as well as multiple minor components (fever, elevated ESR, and CRP) of the Jones criteria. Thus, the diagnosis of ARF was established. Therefore, penicillin prophylaxis was made, and salicylate treatment in an anti-inflammatory dose was initiated. The electrocardiographic abnormalities of the patient disappeared.

## DISCUSSION

Heart damage occurs between the 1st and 2nd weeks after a streptococcal infection. The diagnosis of ARF is currently based on Jones' criteria. The presence of two major criteria or one major criterion and two minor criteria as well as positive evidence of a recent group A streptococcal infection is necessary to establish the diagnosis of rheumatic fever. Minor diagnostic criteria include first-degree heart block, which is quite common in the cardiac ARF but there are only a few reported cases of complete AV block in the setting of ARF in the literature. Cases with a complete AV block are rarely observed [6, 7]. The exact mechanism by which ARF drives complete AV block remains, however, unknown, but some studies suggest the possibility of vagal hyperactivity during the inflammatory syndrome induced by ARF [8]. Reflex vagal hypertonia has also been suggested as a mechanism for conduction disorder, but few studies have proven this theory. Another proposed hypothesis is the inflammation of the AV node and the His bundle, which can cause a complete AV block. AV blocks are more commonly observed in the elderly with a frequently degenerative origin. A complete AV block in a young patient must evoke an ARF [8].

Carano et al. presented a similar case of a 14-year-old boy whose clinical presentation was dominated by a complete AV block type conduction disorder with minimal aortic regurgitation on echocardiography [9] and first presented with acute rheumatic fever and carditis. This presentation suggests that damages in the case of ARF are not necessarily valvular, and features of carditis may only be pericarditis or the conduction system involvement. The diagnosis requires the other modified Jones criteria. Another case was reported by Lenox et al. of complete heart block in acute rheumatic carditis [10]. All ARF cases should receive: A single injection of intramuscular Benzathine Penicillin G, or Oral Penicillin for ten days (Erythromycin if allergy to penicillin) [11] and reduce inflammation with anti-inflammatory medications such as aspirin or corticosteroids. Systemic corticosteroids appear to be less effective in ARF compared to high dose aspirin monotherapy [12].

Corticotherapy was the primary treatment in the case reported by Carano, and his colleagues [9], the combination of penicillin and aspirin at an inflammatory dose was very beneficial in our young child with

complete regression of symptoms including the complete AV block. Long-term regular secondary prevention is necessary, including routine medical monitoring, dental control, and daily Penicillin treatment or monthly intramuscular injections should be used. For the duration of treatment, monthly doses of long-acting penicillin should be administered for ten years in patients with an attack of rheumatic fever. If there are signs of carditis, the duration of treatment can be up to 40 years. Several authors have proposed a lifelong prophylaxis if there is a history of severe carditis. [13]. Another important cornerstone in the treatment of rheumatic fever includes the prevention of recurrences with using low-dose antibiotics (such as penicillin, sulfadiazine, or erythromycin) [14].

## CONCLUSION

We describe a rare form of cardiac involvement in ARF with a complete AV block. Although rare, it can present with advanced conduction system involvement, which is reversible if treatment is initiated without the need for permanent pacemaker placement.

## Competing Interests

The authors declare no competing interest.

## Funding

We have no funding sources to declare

## REFERENCES

1. Pattyn N, Beulque R, Cornelissen V. Aerobic Interval vs. Continuous Training in Patients with Coronary Artery Disease or Heart Failure: An Updated Systematic Review and Meta-Analysis with a Focus on Secondary Outcomes. *Sports Med.* 2018;48(5):1189-205. doi: 10.1007/s40279-018-0885-5 pmid: 29502328
2. Sika-Paotonu D, Beaton A, Raghu A, Steer A, Carapetis J. Acute rheumatic fever and rheumatic heart disease. *Streptococcus pyogenes: Basic Biology to Clinical Manifestations* [Internet]: University of Oklahoma Health Sciences Center; 2017.
3. Bulletin Épidémiologique 2018 [cited 2018]. Available from: <https://bit.ly/2VjCS3B>.
4. Karthikeyan G, Guilhaume L. Acute rheumatic fever. *Lancet.* 2018;392(10142):161-74. doi: 10.1016/s0140-6736(18)30999-1
5. Zuhlke LJ, Beaton A, Engel ME, Hugo-Hamman CT, Karthikeyan G, Katzenellenbogen JM, et al. Group A Streptococcus, Acute Rheumatic Fever and Rheumatic Heart Disease: Epidemiology and Clinical Considerations. *Curr Treat Options Cardiovasc Med.* 2017;19(2):15. doi: 10.1007/s11936-017-0513-y pmid: 28285457
6. Reddy DV, Chun LT, Yamamoto LG. Acute rheumatic fever with advanced degree AV block. *Clin Pediatr (Phila).* 1989;28(7):326-8. doi: 10.1177/000992288902800706 pmid: 2736856
7. Mohindra R, Pannu H, Mohan B, Kumar N, Dhooria H, Sehgal A, et al. Syncope in a middle aged male due to acute rheumatic fever. *India Heart J.* 2004;56(6):668-9.
8. Keith J. Over-stimulation of the vagus nerve in rheumatic fever. *QJM Int J Med.* 1938;7(1):29-42.
9. Carano N, Bo I, Tchana B, Vecchione E, Fantoni S, Agnetti A. Adams-Stokes attack as the first symptom of acute rheumatic fever: report of an adolescent case and review of the literature.

- Ital J Pediatr. 2012;38:61. doi: 10.1186/1824-7288-38-61  
pmid: 23110777
10. Lenox CC, Zuberbuhler JR, Park SC, Neches WH, Mathews RA, Zoltun R. Arrhythmias and Stokes-Adams attacks in acute rheumatic fever. *Pediatr.* 1978;61(4):599-603.
11. Gerber MA, Baltimore RS, Eaton CB, Gewitz M, Rowley AH, Shulman ST, et al. Prevention of rheumatic fever and diagnosis and treatment of acute Streptococcal pharyngitis: a scientific statement from the American Heart Association Rheumatic Fever, Endocarditis, and Kawasaki Disease Committee of the Council on Cardiovascular Disease in the Young, the Interdisciplinary Council on Functional Genomics and Translational Biology, and the Interdisciplinary Council on Quality of Care and Outcomes Research: endorsed by the American Academy of Pediatrics. *Circulation.* 2009;119(11):1541-51. doi: 10.1161/CIRCULATIONAHA.109.191959  
pmid: 19246689
12. Cilliers A, Manyemba J, Adler AJ, Saloojee H, Cilliers A. Anti-inflammatory treatment for carditis in acute rheumatic fever. *Cochrane Database of Systematic Reviews* 2012.
13. Guidelines for the diagnosis of rheumatic fever. Jones Criteria, 1992 update. Special Writing Group of the Committee on Rheumatic Fever, Endocarditis, and Kawasaki Disease of the Council on Cardiovascular Disease in the Young of the American Heart Association. *JAMA.* 1992;268(15):2069-73. pmid: 1404745
14. Spinks A, Glasziou PP, Del Mar CB. Antibiotics for sore throat. *Cochrane Database of Systematic Reviews.* 2013;5(11). doi: 10.1002/14651858.CD000023.pub4