

A Patient With Graves' Disease in Whom Presenting Eye Signs Were Associated With Antibodies to the Thyrotropin Receptor and Later Eye Muscle Damage With Antibodies to G2s and Flavoprotein

Cheng-Hsien Chang^{a,b}, Junichi Tani^c, Audrey Wu Li^a, Jack R. Wall^{1c}.

^aThe Centre for Thyroid Research, Dalhousie University, Halifax, Nova Scotia, Canada;

^bDepartment of Ophthalmology, Kaohsiung Medical University, Kaohsiung, Taiwan; ^cUniversity of Sydney, Western Clinical School (Nepean Campus), 5th. Floor, South Block, Nepean Hospital, PO Box 63, Penrith, NSW 2751, Australia

We report a 14-year-old female patient with Graves' hyperthyroidism and mild eye signs in whom ophthalmopathy worsened after several months of treatment with Methimazole and thyroxin. Serum antibodies against the eye muscle antigens G2s, flavoprotein (Fp), succinate dehydrogenase (SDH) and flavine adenine Dinucleotide (FAD), and human TSH receptor, were measured retrospectively in serum taken from the patient over a 3 yr period. High levels of serum antibodies against the TSH receptor [TSH receptor antibody (TRAb)] were detected in the first sample, when mild proptosis, chemosis and diplopia on extreme gaze were noted. TRAb levels then declined and became negative after 15 months. Twelve months after the initial assessment she developed eye grittiness and excess tearing and, two wk later, antibodies against G2s became positive. Six months later she complained of severe upward-gaze double vision and increased proptosis was noted. At that time antibodies against Fp and SDH became positive. This is the first report correlating a patient's autoantibody

levels with clinical symptoms and signs of ophthalmopathy. Autoimmunity against the TSH receptor may be the initial event in the development of ophthalmopathy in patients with Graves' hyperthyroidism while antibodies against G2s and Fp are produced later, in association with worsening inflammatory changes and eye muscle damage. Despite the close relationship between eye muscle antibodies and clinical eye signs in this patient the antibodies are likely to be secondary to the eye muscle reaction, rather than its cause.

Key Words: G2s, Flavoprotein, Eye muscle antibodies, Graves' disease, Thyroid-associated ophthalmopathy, Enzyme-linked immunosorbent assay, Thyrotropin receptor

Introduction

Auto antibodies reactive against eye muscle and orbital connective tissue antigens have been identified in patients with thyroid-associated ophthalmopathy (TAO), although their significance is unclear.^{1,2} Antibodies against flavoprotein (Fp) and the novel eye muscle and thyroid shared protein G2s correlate closely with eye muscle damage³⁻⁵

Correspondence: J.R. Wall, University of Sydney, Western Clinical School (Nepean Campus), 5th. Floor, South Block, Nepean Hospital, PO Box 63, Penrith, NSW 2751, Australia

E-mail: jackw@med.usyd.edu.au

whereas, antibodies against a TSH receptor-like protein expressed in orbital preadipocyte may be the initial event leading to the development of orbital inflammation in patients with thyroid autoimmunity.^{6,7} The novel 55 kDa eye muscle membrane protein G2s, which is strongly expressed in eye muscles, thyroid and other skeletal muscle,⁸ is the best candidate of the several eye muscle antigens that have been identified in our laboratory. G2s is now identified as the terminal 141 amino acids of the FOX p1 protein, a winged-helix transcription factor that may be expressed in the eye muscle fiber membrane (human genome project). A shared autoantigen in the orbit and thyroid gland such as FOX p1 or the TSH receptor has been postulated to be the target(s) of the immune reactions in TAO.⁹⁻¹¹ This case report concerns a patient in whom antibodies against both the TSH receptor and eye muscle antigens have been measured. We show that serum antibodies against TSH receptor were associated with early eye symptoms, whereas those against G2s and Fp appeared later, when the patient had worsening eye signs and severe double vision.

Patients and Methods

Case report

A 14-year old girl with Graves' hyperthyroidism was first seen in April 1992. She was treated with Methimazole and thyroxine, which she took for 18 months and was followed for another 3 yr. Serum samples were collected throughout the study and stored at -20°C. A total of 25 serum samples were available for the study. At first presentation the patient had classical features of Graves' hyperthyroidism including; diffuse goitre, increased T4 and suppressed TSH and some mild eye signs including, mild diplopia at the far extreme of lateral gaze in both eyes, very mild chemosis and mild to moderate proptosis bilaterally (22, 20 mm). Following cessation of medication after 18 months the patient became euthyroid and remained in remission for the rest of the study. She devel-

oped gritty and watery eyes in April 1993 and, in November of 1993, increasing proptosis (> 20 mm) and severe upward-gaze double vision. Her attending endocrinologist identified the eye changes using standard clinical criteria and measurements. Proptosis was determined, as mm protrusion, using a Hertel exophthalmometer. The patient has since remained euthyroid and now has stable eye disease.

Enzyme-linked immunosorbent assay

This method has been described previously.^{12,13} Concentrations of antigens used were; SDH 0.25 g/ml, Fp 1.25 g/ml, FAD 0.25 g/ml and G2s 0.25 g/ml. SDH was prepared from beef heart mitochondria by Ackrell et al., as described previously.¹⁴ G2s was cloned into pFLAG-ATS and purified according to the manufacturer's procedure (Sigma, St. Louis)¹⁰ and FAD was purchased from Sigma Co. Serum dilution was 1: 25. Results were expressed as optical density at 405 nm. A positive test was taken as an OD > mean + 2 standard deviations for 6 normal sera, the upper limit of normal.

TSH receptor antibody (TRAb) assay

TRAb in the serum samples were detected using a TRAb ELISA kit (KRONUS, ID, USA) according to the manufacturer's instructions. Briefly, TSH receptor is coated onto ELISA plate wells and bound TRAb are detected by their ability to inhibit the binding of TSH (in the form of TSH-biotin) to the receptor-coated wells. The bound TSH is then quantified by addition of streptavidin peroxidase and the peroxidase substrate tetramethyl benzidine. TRAb levels are expressed as a percentage inhibition of TSH binding index, with a level >10% being taken as positive.

Results

Eye muscle antibodies and TRAb were measured, in single assays, in the 25 serial samples taken from this patient over a 3 yr period. Levels of serum antibodies against the TSH receptor are shown in Fig. 1 and of

anti-G2s, -Fp, -SDH and -FAD, in Fig. 2. The arrows indicate the times of appearance of eye symptoms and signs. TRAb was strongly positive in the first sample, when she was hyperthyroid with mild eye signs. Thereafter TRAb decreased, bearing no relationship to later eye signs. Indeed, by the time she complained of severe binocular diplopia and aggravated proptosis was noted, TRAb levels were borderline positive or negative.

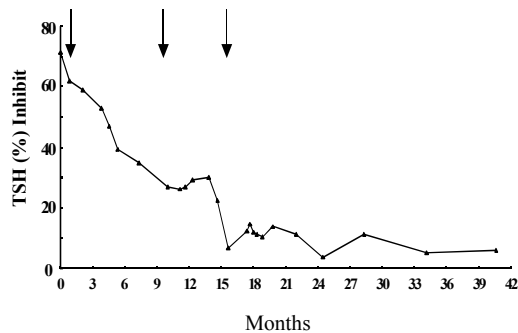


Fig.1. TSH receptor antibody (TRAb) levels in 25 serum samples from a patient with Graves' hyperthyroidism and ophthalmopathy. Results are expressed as percentage inhibition of TSH binding, a value of > 10% being taken as positive. The arrows indicate the times of onset of eye symptoms and signs namely, mild proptosis, chemosis and diplopia on extreme gaze dry eyes (Apr 1992), grittiness and excess tearing (Apr 93) and proptosis and worsening double vision (Oct 93)

Levels of antibodies against Fp and SDH were superimposable throughout the study period. Antibodies against G2s, Fp and SDH were not detected initially, when the patient first complained of eye symptoms, but levels were increasing when she began to complain of gritty and watery eyes, in April 1993, becoming positive in June 1993 [anti-G2s] and Sept. 1993 [anti-Fp, anti-SDH], respectively. Anti-G2s levels fluctuated, rising to a second peak in Oct. 1993, just before the patient complained of worsening double vision.

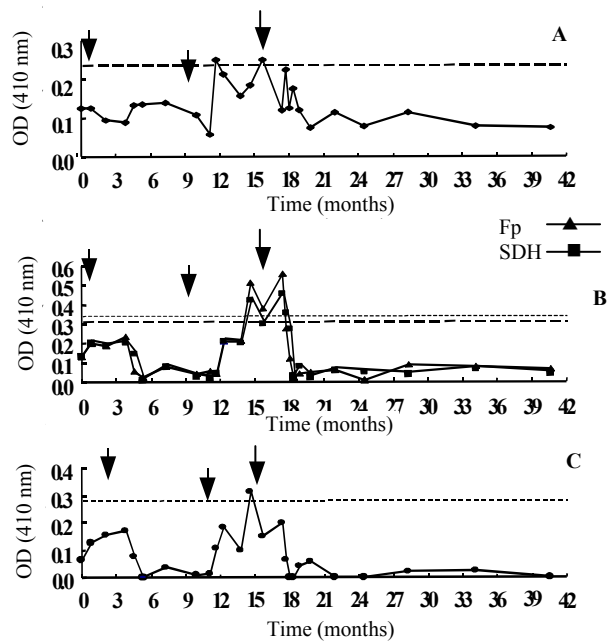


Fig.2. A 14-year old girl with Graves' hyperthyroidism and mild eye signs at diagnosis (first arrow) developed gritty and watery eyes in April 1993 (second arrow) then proptosis and severe upward-gaze double vision in Oct 1993 (third arrow). A series of 25 consecutive blood samples were collected over a three-year follow-up period and frozen. Antibodies against G2s (panel A), SDH (▲---▲) and Fp (■---■) (panel B) and FAD (panel C) were measured, in single assays, in enzyme-linked immunosorbent assay at the end of the study. Results are expressed as OD at 410 nm. A positive value is taken as an OD > the upper limit of normal (ULN), defined as the mean plus two standard deviations of values obtained from a panel of six normal subjects. The broken horizontal lines represent the upper limits of normal for each antibody

Peak levels of anti-Fp and anti-SDH antibodies coincided with the onset of worsening double vision and increased proptosis, then fell slowly, becoming negative in Dec. 1993. Levels of anti-FAD antibodies were generally

lower, but showed a similar pattern, becoming positive a few weeks before the patient complained of severe double vision.

Discussion

We observed a close temporal relationship between the detection of serum antibodies and eye symptoms in a patient with Graves' hyperthyroidism treated with MMI who had mild eye signs at diagnosis, then worsening signs and symptoms 12-18 months later. Because all serum samples were tested and compared in the same assay, changes in the levels of antibodies reflect true variations in antibody production in the context of the autoimmune reactions in the orbit. TRAb were first detected at the initial visit when she had hyperthyroidism and mild eye signs. It thereafter decreased, showing no correlation with later, more severe, eye changes. Antibodies against G2s were first detected soon after the patient complained of grittiness and excess tearing, peaking just before the onset of worsening double vision while anti-Fp and anti-SDH antibodies both became positive a few weeks later. Antibodies against FAD were generally lower, and did not correlate closely with those against Fp or SDH.

Whilst proptosis may reflect both eye muscle swelling and orbital connective tissue inflammation, double vision is a characteristic symptom of eye muscle dysfunction. Previously, we showed that antibodies against Fp were present in patients with the ocular myopathy subtype of TAO, but not in those with mainly congestive changes.³ The preparation of SDH that we used was isolated from beef heart mitochondria and comprises the Fp subunit, FAD cofactor, and iron/sulfur clusters, whereas the Fp preparation that we used was human recombinant, separated from iron/sulfur and FAD. We presume that reactivity against SDH in this patient reflected targeting of Fp, as the values were almost identical throughout the study. In other studies from our laboratory we have found some discrepancies in reactivity, suggesting that there may be an additional epitope in the

SDH preparation, which is different from Fp and FAD (Wall, Li et al. unpublished data). One other possible cause of increased anti-Fp and anti-G2s antibodies in this patient is a rebound following cessation of MMI, which has immunosuppressive activity,¹⁵ although this would not explain the subsequent fall in antibody levels. If anti thyroid drugs can be shown to have such an effect on anti-Fp and -G2s antibodies, these drugs could be recommended in order to prevent eye muscle damage in patients with Graves' hyperthyroidism.

This is the first observation of a close temporal relationship between eye muscle antibodies and eye signs in a patient with Graves' hyperthyroidism. The study also shows that anti-G2s antibodies, which are closely associated with parameters of eye muscle damage,^{16,17} are produced before those against Fp. We have found the same relationship in an experimental model for TAO.¹⁸ Antibody targeting of the FOX p1 protein, which has at least one putative transmembrane domain⁷ may be the cause of eye muscle damage in patients with thyroid autoimmunity,^{1,2,19,20} although it is more likely that the antibodies are secondary to some other reaction. Fp is localized to the inner mitochondrial membrane and antibodies to these proteins are unlikely to be able to penetrate the intact cell wall and mitochondrial membrane. Anti-Fp antibodies are thus also likely to be secondary to eye muscle damage and release of intracellular proteins in the context of an autoimmune reaction in the orbit.

The role of autoimmunity against the TSH receptor has been implicated in TAO.⁶ In our patient high levels of TRAb correlated with her presenting eye symptoms, suggesting that the antibodies may initiate the orbital reaction in patients with thyroid autoimmunity. Thereafter, levels did not correlate at all with worsening eye signs and eye muscle damage. In a recent study, Noh et al.²¹ showed a correlation between TSH receptor stimulating antibodies, but not TSH-binding inhibition antibodies, and ophthalmopathy. The measure-

ment of antibodies against G2s (or the full length FOX p1 protein) could be used as a screening test in patients with Graves' hyperthyroidism to identify the progressive stage of ophthalmopathy. If positive, patients could be treated with immunosuppressive drugs or prednisone to prevent eye muscle damage, which occurs later, as indicated by antibodies against Fp. In conclusion, in this report we document a close relationship between serum TSH receptor and eye muscle antibodies and clinical features of ophthalmopathy in a pa-

tient with Graves' hyperthyroidism studied serially which favors a two-phase pathogenesis of the eye disorder.

Acknowledgments

Dr. B.A.C. Ackrell (UCSF, USA) kindly provided flavoprotein and SDH. We thank Dr. S. Salisbury for information about the patient and Dr. R. Rittmaster for allowing access to the patient's serum samples.

References

1. Yamada M, Li AW, Wall JR. Thyroid-associated ophthalmopathy: clinical features, pathogenesis, and management. *Crit Rev Clin Lab Sci.* 2000; 37(6): 523-49
2. Kaspar M, Archibald C, De BA, Li AW, Yamada M, Chang CH, Kahaly G, Wall JR. Eye muscle antibodies and subtype of thyroid-associated ophthalmopathy. *Thyroid.* 2002 12(3):187-91
3. Gunji K, De Bellis A, Kubota S, Swanson J, Wengrowicz S, Cochran B, et al. Serum antibodies against the flavoprotein subunit of succinate dehydrogenase are sensitive markers of eye muscle autoimmunity in patients with Graves' hyperthyroidism. *J Clin Endocrinol Metab.* 1999; 84(4): 1255-62.
4. Wu YJ, Clarke EM, Shepherd P. Prevalence and significance of antibodies reactive with eye muscle membrane antigens in sera from patients with Graves' ophthalmopathy and other thyroid and nonthyroid diseases. *Thyroid.* 1998 8(2): 167-74
5. Chang TC, Chang TJ, Huang YS, Huang KM, Su RJ, Kao SC. Identification of autoantigen recognized by autoimmune ophthalmopathy sera with immunoblotting correlated with orbital computed tomography. *Clin Immunol Immunopathol.* 1992 65(2): 161-6.
6. Bahn RS. Understanding the immunology of Graves' ophthalmopathy. Is it an autoimmune disease? *Endocrinol Metab Clin North Am.* 2000; 29(2): 287-96 vi.
7. Ludgate M, Crisp M, Lane C, Costagliola S, Vassart G, Weetman A, Daunerie C, Many MC. The thyrotropin receptor in thyroid eye disease. *Thyroid.* 1998; 8(5): 411-3.
8. Gunji K, De Bellis A, Li AW, Yamada M, Kubota S, Ackrell B, et al. Cloning and characterization of the novel thyroid and eye muscle shared protein G2s: autoantibodies against G2s are closely associated with ophthalmopathy in patients with Graves' hyperthyroidism. *J Clin Endocrinol Metab.* 2000 85(4): 1641-7.
9. Wall JR, Salvi M, Bernard NF, Boucher A, Haegert D. Thyroid-associated ophthalmopathy--a model for the association of organ-specific autoimmune disorders. *Immunol Today.* 1991; 12(5): 150-3.
10. Weetman AP. Thyroid-associated eye disease: pathophysiology. *Lancet.* 1991 6; 338(8758): 258.
11. Kiljanski JI, Nebes V, Wall JR. The ocular muscle cell is a target of the immune system in endocrine ophthalmopathy. *Int Arch Allergy Immunol.* 1995 106(3): 204-12
12. Kubota S, Gunji K, Ackrell BA, Cochran B, Stolarski C, Wengrowicz S, et al. The 64-kilodalton eye muscle protein is the flavoprotein subunit of mitochondrial succinate dehydrogenase: the corresponding serum antibodies are good markers of an immune-mediated damage to the eye muscle in patients with Graves' hyperthyroidism. *J Clin Endocrinol Metab.* 1998; 88(2): 443-7.
13. Hosal BM, Swanson JK, Thompson CR, Kubota S, Gunji K, Kennerdell JS, et al. Significance of serum antibodies reactive with flavoprotein subunit of succinate dehydrogenase in thyroid associated orbitopathy. *Br J Ophthalmol.* 1999 83(5): 605-8
14. Ackrell BA, Armstrong FA, Cochran B, Sucheta A, Yu T. Classification of fumarate reductases and succinate dehydrogenases based upon their contrasting behaviour in the reduced benzylviologen/fumarate assay. *FEBS Lett.* 1993 12326(1-3): 924 .
15. Kubos KL, Moran TH, Saad KM, Robinson RG. Asymmetrical locomotor response to unilateral cortical injections of DSP-4. *Pharmacol Biochem Behav.* 1984; 21(1): 163-7.
16. de Bellis A, Perrino S, Coronella C, Sansone D, Ruocco G, Tirelli G, et al. Extraocular muscle an-

- tibodies and the occurrence of ophthalmopathy in Graves' disease. *Clin Endocrinol (Oxf)*. 2004; 60(6): 694-8
17. De Bellis A, Bizzarro A, Conte M, Coronella C, Solimeno S, Perrino S, Sansone D, Guaglione M, Wall JR, Bellastella A. Relationship between longitudinal behaviour of some markers of eye autoimmunity and changes in ocular findings in patients with Graves' ophthalmopathy receiving corticosteroid therapy. *Clin Endocrinol (Oxf)*. 2003; 59(3): 388-95
 18. Yamada M, Li AW, West KA, Chang CH, Wall JR. Experimental model for ophthalmopathy in BALB/c and outbred (CD-1) mice genetically immunized with G2s and the thyrotropin receptor. *Autoimmunity*. 2002; 35(6): 403-13.
 19. Wall JR, Bernard N, Boucher A, Salvi M, Zhang ZG, Kennerdell J, et al. Pathogenesis of thyroid-associated ophthalmopathy: an autoimmune disorder of the eye muscle associated with Graves' hyperthyroidism and Hashimoto's thyroiditis. *Clin Immunol Immunopathol*. 1993; 68(1): 1-8
 20. Wall JR. Graves' disease is a multi-system autoimmune disorder in which extra ocular muscle damage and connective tissue inflammation are variable features. *Thyroid*. 2002; 12(1):356
 21. Noh JY, Hamada N, Inoue Y, Abe Y, Ito K, Ito K. Thyroid-stimulating antibody is related to Graves' ophthalmopathy, but thyrotropin-binding inhibitor immunoglobulin is related to hyperthyroidism in patients with Graves' disease. *Thyroid*. 2000; 10(9): 809-13