

Pituitary Stone or Calcified Pituitary Tumor? Three Cases and Literature Review

Farida Chentli^{1,*}; Amel Safer-Tabi¹

¹Department of Endocrinology and Metabolic Diseases, Bab El Oued Teaching Hospital, Algiers, Algeria

*Corresponding author: Farida Chentli, Department of Endocrinology and Metabolic Diseases, Bab El Oued Teaching Hospital, Algiers, Algeria. Fax: +213-21960040, E-mail: chentli.f@gmail.com

Received: March 3, 2015; Revised: May 25, 2015; Accepted: May 28, 2015

Introduction: Pituitary stone or pituitary calculus is a scientific enigma characterized by a large calcification in the pituitary sella. It can be discovered incidentally or in a patient with endocrine and/or neurological problems. Its mechanism is not understood. In this article, we described three patients harboring a large pituitary calcification.

Case Presentation: The first case was observed in a 27-year-old woman who consulted for secondary amenorrhea. The second case concerned a woman who consulted for infertility, and the third one was observed in an 11-year and nine-month-old girl who was sent to our department for short stature. Clinical examination was normal in both adults. The pediatric case had dwarfism with lack of pubertal development. Hormonal assessment showed hyperprolactinemia in both women and thyrotroph and somatotroph deficits in the child. Radiologic exploration discovered pituitary calcifications measuring 10, 11, and 45 mm without any cystic or solid mass.

Conclusions: Radiological findings pleaded for a pituitary stone, but calcified adenomas in women, and calcified craniopharyngioma in the pediatric case could not be excluded, as our three patients were not operated on.

Keywords: Pituitary Gland; Heterotopic Ossification; Hyperprolactinemia; Hypopituitarism

1. Introduction

Pituitary calculus or pituitary stone, also named pituitary lithiasis, is a scientific enigma characterized by a large calcification in the sella turcica (1-10). This anomaly can be discovered accidentally (1) or in a person with endocrine and/or neurological abnormalities (2). The mechanism of the pituitary calcification remains totally obscure and controversial although many authors believe it results from a calcified pituitary tumor, an inflammatory or hemorrhagic process, and/or amyloid deposits (1, 3). The true pituitary stone may be idiopathic or “de novo”, but this situation remains exceptional (1-10).

In this article, we reported three persons harboring pituitary calcifications, which were likely to be calcified pituitary tumors, but a “de novo” pituitary stone could not be excluded.

2. Case Presentation

2.1. Case 1

A 27-year-old woman without any medical history was consulted for secondary amenorrhea. Menstrual problems lasted three years and were associated with headaches without visual complaints.

Findings of her clinical examination were normal. Her body mass index (BMI) was 23 kg/m². Except for menstrual disorders, she did not have any features of pituitary hypersecretion or hyposecretion. She did not complain from polyuria or polydipsia and her urinary specific gravity was within normal limits (1015).

Biochemical assessment was unremarkable, calcium and phosphorus values were normal. Hormonal exploration showed a moderate increase in serum prolactin, hyperprolactinemia (77 ng/ml). Corticotroph, somatotroph, and thyrotroph functions were normal (Table 1).

Ophthalmological examination was normal for visual acuity and fundus, but there were cortical and nuclear lens opacities suspected to be in relation with diabetes mellitus or a congenital origin. However, diabetes mellitus was rapidly excluded by oral glucose tolerance test (OGTT).

Skull radiography showed a large pituitary sella containing a round, compact, and uniform calcification. Brain computed tomography (CT) scan confirmed the compact calcified intrasellar mass measuring 10 mm in height. The sellar floor was intact (Figure 1 A). Magnetic resonance imaging (MRI) showed a hyposignal mass in the sella turcica with posterior and lateral displacement of the left pituitary gland (Figure 1 B).

Table 1. Hormonal Assessments of the Three Patients With Pituitary Calcification

Variables	Case 1	Case 2	Case 3	Normal Range
Cortisol (ng/mL)	153	146	182	50-250
Thyroid Stimulating Hormone (μ U/mL)	0.77	1.8	4.26	0.4-4.5
Free Triiodothyronine (ng/mL)	2.3	-	-	2.3-4.0
Free thyroxin (ng/dL)	-	0.7	0.53	0.6-2.0
Follicular Stimulating Hormone (mu/mL)	5.3	21	-	1.4-9.6
Luteinizing hormone (mu/mL)	2.7	7.8	-	0.8-12
Prolactin (ng/mL)	77	47.6 (22-80)	14	5-20
Growth Hormone (ng/mL)	0.5	0.3	0.34 \rightarrow 1.78 ^a	0.2-2.0

^a Under ITT (insulin tolerance test), glycaemia: 0.86 \rightarrow 0.29 g/L.

This patient had low dose bromocriptine (1.25 mg/day) that normalized prolactin and gonadal function. Four years later radiological examination did not show any modification of the calcification.

2.2. Case 2

A 44-year-old woman with a history of benign breast disease and fallopian tube obstruction was sent to our department for pituitary calcification. She reported regular menstrual cycles with premenstrual syndrome and two episodes of severe headaches. One of which had occurred six months before her hospitalization and was accompanied with vomiting, but without visual problems. Clinical examination revealed an overweight woman (BMI, 28 kg/m²) without any sign of pituitary hypersecretion or hyposecretion. Urinary specific gravity value was within normal limits. Results of biochemical assessment, including calcium and phosphate values, were normal. Hormonal assessment showed variable values of prolactin, but values of other hormones were within normal limits, except for increased follicular stimulating hormone (FSH) indicating ovarian insufficiency (Table 1).

Ophthalmological examination showed normal vision and insignificant findings in fundus. There was not any cataract.

Plain radiographies of the skull and brain CT showed a calcified intrasellar mass measuring 11 mm in the left part of the pituitary fossa (Figures 1C, 1D and 1E).

MRI showed a hypointense formation suggestive of a calcified adenoma or a carotid aneurysm (Figures 1F and 1G). Magnetic resonance angiography excluded the latter possibility.

2.3. Case 3

An 11-year and nine-month-old girl without any personal or family medical history was consulted for short stature and headaches. Clinical examination showed dwarfism (-4 SD/target stature) and lack of pubertal development. Urinary specific gravity value was normal. She did not have

any neurological manifestations. Results of ophthalmological examination were normal. Results of biochemical assessment, including calcium and phosphorous levels, were normal, but hormonal exploration showed thyrotroph and somatotroph deficits (Table 1). Her bone age was delayed (8 years). Skull radiography showed a large pituitary fossa with a large calcified process confirmed by brain CT, which demonstrated a homogenous intrasellar and suprasellar calcified mass measuring 45 mm in height and 11 mm in the transversal diameter (Figures 1H and 1I).

Although the vision and the posterior pituitary function were normal, the young age and the double pituitary deficits were suggestive of a calcified craniopharyngioma; however, a pituitary stone could not be excluded easily. As the neurosurgeons refused surgical treatment, both diagnoses remained possible.

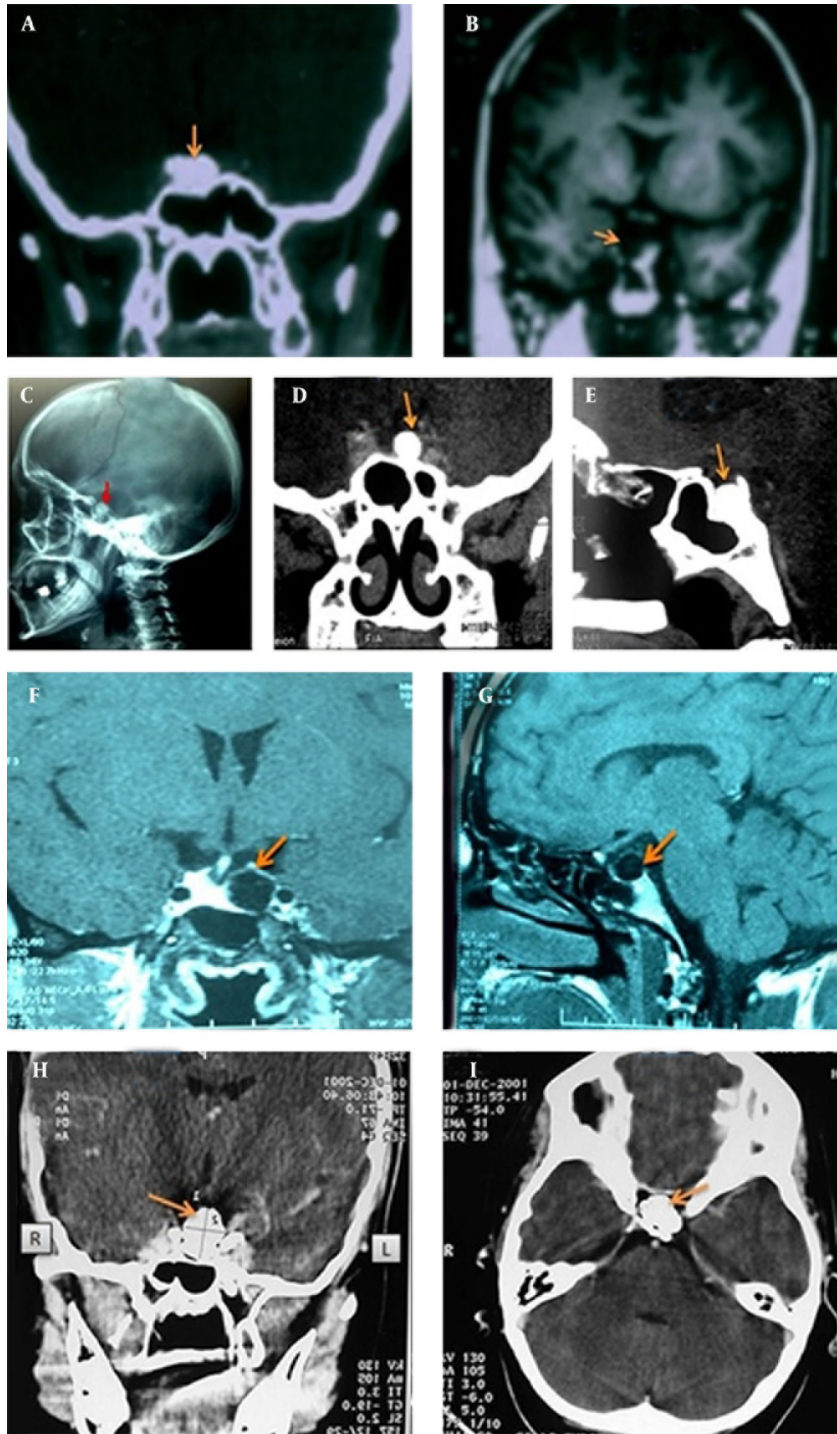
3. Discussion

Pituitary calcification, also named pituitary calculus, lithiasis, or stone, was described for the first time in the middle of the 19th century (2). Although its pathophysiology is still unclear, many authors believe it results from a pituitary inflammatory and/or bleeding process. In clinical practice, most common causes of pituitary calcifications are related to craniopharyngiomas. In other cases, it may be a Rathke's cleft cyst calcification (4) or a calcified pituitary adenoma (2, 3, 5-10). Nevertheless, calcified chordomas, meningiomas, and pituitary aneurysms should be considered too.

The prevalence of calcified pituitary adenomas varies from 0.2% to 14%. Lactotroph (3, 5, 8) and somatotroph adenomas (6) are the most concerned ones. Non-secreting and gonadotroph adenomas are seldom calcified (9).

A "do novo calcification" is a diagnosis of exclusion that may be due to various reasons such as metabolic troubles (calcium and/or amyloid deposits), toxic conditions, anoxic phenomenon, and vascular, infectious, and parasitic diseases, especially tuberculosis (5). Tuberculosis should be discussed in endemic areas, especially in developing countries.

Figure 1. Computed Tomographic Scan and Magnetic Resonance Imaging of Pituitary Gland



Case 1; A, Cerebral Computed tomographic (CT) scan showing the pituitary calcification (arrow) with intact sellar floor. B, Magnetic resonance imaging (MRI) showing a hypointense mass in the sella turcica; Case 2; Left pituitary calcified mass measuring 11 mm suggestive of a pituitary stone on CT scans (C, D, E) and MRI (F, G); Case 3; CT scan showing a completely calcified pituitary process (H, I).

Pituitary lithiasis may be asymptomatic and discovered accidentally with a normal pituitary function (2), or after exploration of an endocrine disorder such as gonadal abnormalities in adults and short stature in chil-

dren. Hyperprolactinemia may be another occasion of discovery (6). In other cases, the pituitary stone may be discovered after developing neurologic symptoms such as acute headaches and/or vomiting suggestive of pitu-

itary apoplexy (2) as in our second observation. Actually, a tumor or a pituitary hemorrhage can lead to fibrosis and then to pituitary calcification. Among pituitary adenomas, prolactinomas are most likely to have apoplexy episodes. Many authors have reported calcifications in prolactinomas. The calcifications are sometimes homogenous and compact looking like a true stone, and sometimes heterogeneous and punctuated (3) suggesting a secondary calcification. Some authors explain hyperprolactinemia by persistence of prolactin granules in the calcified adenomatous tissue. Other researchers confirmed this theory.

According to Brahim et al, somatotroph adenomas can also be calcified (6). Garg et al. reported a calcified non-secreting adenoma (2). Webster et al. have reported two pituitary calculus secondary to primary thyrotroph adenomas (10).

When the calcification is secondary to a pituitary adenoma, the pituitary fossa is generally enlarged. In our first case, it was probably a calcified prolactinoma and in the second case, it could be a non-secreting adenoma with moderate hyperprolactinemia due to pituitary stalk compression. In the third case, as pituitary adenomas are rare in children, we thought of craniopharyngioma or an embryonic tumor because of the young age, the large pituitary fossa, and the double pituitary deficit. However, a “de novo calcification” could not be ruled out easily. The true pituitary stone may also increase the size of the pituitary fossa and even be responsible for papilla edema as reported by some authors.

Hyperprolactinemia, observed in people with pituitary calcifications, can be explained by stalk compression secondary to the calcification. The latter leads to obstruction of pituitary vessels and lack of dopamine inhibition (6). Nonfunctioning pituitary tumors can also be calcified totally or partially and induce hyperprolactinemia; this is why they are called pseudoprolactinomas (2).

Nevertheless, independently of their mechanism, all calcifications are similar in their composition as they contain calcium and/or amyloid deposits. On the histopathological examination, pituitary calcifications are classified in three categories: calcification of an intratumor bleeding, degenerative changes within a pituitary adenoma, and psammoma bodies dispersed between adenoma cells. The last type seems to characterize prolactinomas.

Therefore, with a completely calcified pituitary sella, the first condition to discuss is a calcified craniopharyngioma as in our third observation; however, visual problems and diabetes insipidus were not present. Then prolactinomas and other adenomas should be considered, especially in adults. Although rare, other diseases such as calcified Rathke's cleft cyst, chordomas, chondromas, meningiomas, and pituitary aneurysms should be considered too. The last ones should be excluded by magnetic resonance angiography (1).

The mechanism of a “de novo calcification” is still un-

known although some authors have discussed cartilaginous metaplasia or congenital and/or degenerative amyloid and calcium deposits (1, 3).

Regarding treatment, as the curative one does not exist, the contemplative attitude seems to be the best, unless there are signs of ophthalmological compression and/or hydrocephalus (10).

In conclusion, pituitary stone is a very rare anomaly. It may be discovered incidentally, or after neurological or endocrine disorders such as gonadal failure with or without hyperprolactinemia in adults, and total or partial pituitary insufficiency in children. The positive diagnosis is usually made by the skull base standard X-rays, and then is confirmed by CT scan. Therefore, before retaining a de novo or idiopathic calcification, one should exclude a craniopharyngioma or a calcified pituitary adenoma and other lesions that can be calcified over time. The curative treatment does not exist; hence, expectative attitude remains the only approach, unless there is a compromised vision or intracranial hypertension needing a surgical decompression.

Acknowledgements

We would like to thank PR Lounas Medjek and Boudjema Mansouri for their help concerning radiological explorations.

Authors' Contributions

The first author did data acquisition for two patients, analyses, and interpretation of all data, drafting the manuscript, critical revision, and translation. The second author collected data of one patient and helped in drafting and references.

Financial Disclosure

We declare there is no conflict of interest that would prejudice the impartiality of this scientific work.

Funding/Support

This report did not receive any specific grant from any funding agency in the public or commercial sector.

References

1. Deramond H, Revert R, Dietemann JL, Hamza R, Remond A, Trinez G. Incidentally discovered intrasellar calcifications. *J Neuro-radiol.* 1983;10(3):231-41.
2. Garg MK, Singh G, Brar KS, Kharb S. Pituitary calcification masquerading as pituitary apoplexy. *Indian J Endocrinol Metab.* 2013;17(Suppl 3):S703-5.
3. Bakhtiar Y, Arita K, Hirano H, Habu M, Fujio S, Kitajima S, et al. Prolactin-Producing Pituitary Adenoma With Abundant Spherical Amyloid Deposition Masquerading as Extensive Calcification. *Neurologia medico-chirurgica.* 2010;50(11):1023-6.
4. Ogawa Y, Tominaga T. A partially ossified solid and cystic Rathke cleft cyst. *J Neurosurg.* 2010;112(6):1324-6.
5. Oliveira MDC, Cremonese R, Pizarro C. Hyperprolactinemia associated to calcification of the pituitary stalk: case report. *Arquivos*

- de Neuro-Psiquiatria*. 1998;**56**(2):289-91.
6. Ibrahim R, Kalhan A, Lammie A, Kotonya C, Nannapaneni R, Rees A. Dense calcification in a GH-secreting pituitary macroadenoma. *Endocrinol, Diabetes & Metabolism Case Reports*. 2014.
 7. Rasmussen C, Larsson SG, Bergh T. The occurrence of macroscopical pituitary calcifications in prolactinomas. *Neuroradiology*. 1990;**31**(6):507-11.
 8. Ke C, Deng Z, Lei T, Zhou S, Guo DS, Wan J, et al. Pituitary prolactin producing adenoma with ossification: a rare histological variant and review of literature. *Neuropathology*. 2010;**30**(2):165-9.
 9. Zahariadis G, Kontogeorgos G, Liberopoulos K, George S, Kovacs K. Ossifying Pituitary Gonadotroph Adenoma: A Case Report. *Acta Neurochirurgica*. 1999;**141**(9):1001-4.
 10. Webster J, Peters JR, John R, Smith J, Chan V, Hall R, et al. Pituitary stone: two cases of densely calcified thyrotrophin-secreting pituitary adenomas. *Clin Endocrinol*. 1994;**40**(1):137-43.