

'Watchful Waiting' May Be an Appropriate Treatment for ELBW Infant with Hepatic Mesenchymal Hamartoma

Özgül Salihoğlu, MD; Emrah Can*, MD; Sinem Can, MD;
Sami Hatipoğlu, MD

Department of Pediatrics, Bakırköy Dr. Sadi Konuk Training
and Research Hospital, Istanbul, Turkey

Received: May 31, 2012; Accepted: Nov 19, 2012,
Available Online: Dec 03, 2012

Hepatic mesenchymal hamartoma (HMH) is an uncommon benign tumor of childhood. Typically a patient will present with an enlarged, nontender abdominal mass. No specific panel of laboratory tests is characteristic of HMH. Laboratory studies often reveal normal liver function tests and various tumor markers, including human chorionic gonadotropin, alpha fetoprotein, and vanillylmandelic acid, are usually negative. Abdominal ultrasound can demonstrate either a multicystic or solid mass^[1]. Although not required for diagnosis, computed tomography and magnetic resonance imaging are useful for surgical planning. Surgery, consisting of either enucleation or lobectomy, traditionally has been the treatment of choice in the postpartum period; however, less invasive techniques, such as laparoscopic fenestration have also been used successfully^[2]. Because the natural course of this tumor is initially rapid increase and subsequently decrease in size,

some investigators have opted for "watchful waiting" in asymptomatic patients^[3].

At 29 weeks of gestation, a 960g male infant presented with distress and abdominal distention during the postnatal period. There was visible fullness in the right upper quadrant of the abdomen. The liver was palpable, 6 cm below the left subcostal margin in the mid-clavicular line. Serum bilirubin was 3.91 mg/dl, SGPT 56 U/L, SGOT 8U/L, blood urea 21 mg/dl, Hb 14g. Serum alpha-fetoprotein was in normal range. Bleeding, clotting, and prothrombin time, as well as platelet count and blood gas analysis were normal. X-ray of the chest showed elevated right dome of the diaphragm. US of the abdomen revealed a large, 8.8×7.0×4.7 cm sized anechoic cystic mass occupying almost the entire left lobe and superior segment of right lobe of the liver. There were multiple internal septations and multilobules within the mass. However, no solid component was visible. Other hepatic parenchymal echoes were homogeneous. The right lobe of the liver was enlarged. The portal vein showed normal flow. No portal or retroperitoneal lymphadenopathy was seen and there was minimal perihepatic ascites. On first MRI scan, the lesion was 4.7×5.3×5.6 cm, hyperintense on T2W image and hypo intense on T1W images confirming its cystic nature in the right lobe (Fig 1). Control ultrasound and MRI scan was repeated 3 months later. Anechoic cystic mass size was 10.8×6.4×5.6 cm. MRI scan did not show enlargement of the previously diagnosed cystic lesions but gave rise to multilocular

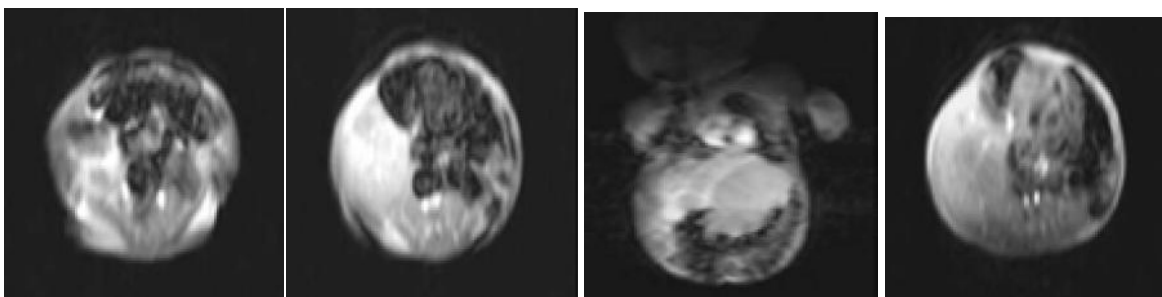


Fig. 1: MRI in the age of 1-month-old showing a large, dominantly cystic hepatic mesenchymal hamartoma

* Corresponding Author; Address: Department of Pediatrics,
Division of Neonatology, Bakırköy Dr. Sadi Konuk Training and
Research Hospital Istanbul, Turkey

E-mail: canemrahcan@yahoo.com

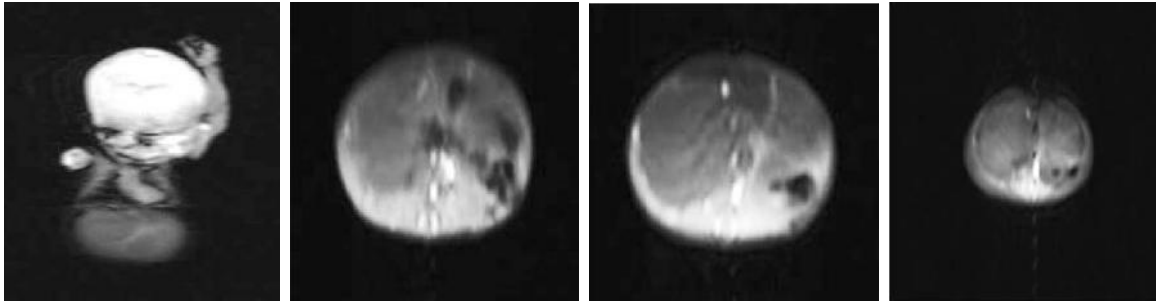


Fig. 2: Second MRI in the age of 3-months with dominantly cystic hepatic mesenchymal hamartoma

septations shown in the second MRI (Fig 2). The diagnosis was established by ultrasonography and MRI scan, and histologically confirmed. Supportive therapy, such as mechanical ventilation, fluid therapy and enteral nutrition was given to preterm infant admitted to neonatal intensive care. The case was not eligible for surgical operation of the liver mass. Follow up showed no complications and liver mass had not changed in size. Regarding the good condition, the patient was discharged from NICU.

The typical HMH presentation is one of asymptomatic, rapid abdominal distention with a palpable mass on physical examination^[4]. The tumor can cause respiratory distress or apnea^[5]. Our case presented with abdominal distention and respiratory distress in early postnatal period. Usually liver function tests are normal and alpha-fetoprotein is elevated, which is believed to be secreted by the proliferating hepatocytes within the tumor^[4]. In our case liver function tests and coagulation tests were normal. The radiological appearance is one of a large, uni- or multi-cystic, avascular mass occupying part of the liver^[4]. Ultrasound of the abdomen reveals a large, anechoic cystic mass of the liver. There are multiple internal septations and multilobules within the mass but no solid component is visible. MRI scan demonstrates the complex nature of the cystic mass. In our case ultrasound scan and MR scan showed multiple internal septations and multilobules within the mass at the first and 3rd month of life.

HMHs are best treated by complete excision. Excision may be by conventional hepatic resection or by non-anatomical excision with a small margin of normal liver. If the patient is in satisfactory clinical condition and if the lesion is

resectable, the prognosis is excellent. Neonates generally have a better outcome than fetuses. Pedunculated lesions are amenable to laparoscopic resection^[6]. In previously reported cases of mesenchymal hamartoma occupying part of the liver, the tumors were successfully treated by surgical resection, and the remaining liver tissue provided adequate liver function^[5,6]. This treatment was considered inadequate for our case due to prematurity of the infant.

Nonoperative management may be appropriate in selected cases (e.g., infants with a biopsy-proven HMH and a prominent vascular component). As far as we know, there were a few cases of spontaneous regression in preterm neonates reported in literature. Barnhart et al^[3] observed spontaneous regression of asymptomatic HMH, and suggest non-operative management for asymptomatic patients. In addition, nine patients in whom HMH showed a variable degree of spontaneous regression have been reported: four dominantly solid tumors were highly vascular, three of which became heavily calcified as the tumor regressed; this suggests that HMHs with a prominent angiomatous component are more likely to regress. None of the lesions disappeared completely, and in all but one the follow-up observation lasted less than 3 years^[3,7]. In our case, the HMH was characterized by angiomatosis in a preterm infant expected to have spontaneous remission.

As a conclusion, 'Watchful waiting' may be a treatment option with mesenchymal liver hamartoma in selected very low birth weight preterm infants.

Key words: Mesenchymal Hamartoma; Liver Tumor; Neonate; Prematurity

References

1. Yen JB, Kong MS, Lin JN. Hepatic mesenchymal hamartoma. *J Paediatr Child Health* 2003;39(8): 632-4.
2. Horiuchi A, Muraji T, Tsugawa C, et al. Laparoscopic fenestration of a neonatally detected hepatic mesenchymal hamartoma. *J Laparoendosc Adv Surg Tech A* 2005;15(4):432-4.
3. Barnhart DC, Hirschl RB, Garver KA, et al. Conservative management of mesenchymal hamartoma of the liver. *J Pediatr Surg* 1997; 32(10):1495-8.
4. Kwok WK, Spitz L, Brereton RJ, et al. Mesenchymal hamartoma of the liver. *Pediatr Surg Int* 1989; 4: 296-9.
5. Lennington WJ, Gray GF, Page DL. Mesenchymal hamartoma of liver: a regional ischemic lesion of a sequestered lobe. *Am J Dis Child* 1993; 147(2):193-6.
6. Tsao K, Hirose S, Sydorak R, et al. Fetal therapy for giant hepatic cysts. *J Pediatr Surg* 2002;37(10): E31.
7. Narasimhan KL, Radotra BD, Harish J, et al. Conservative management of giant hepatic mesenchymal hamartoma. *Indian J Gastroenterol* 2004;23(1):26.

Accidental Intra-arterial Injection of Adenosine in a Child with Supraventricular Tachycardia

Mandar B. Patil¹, MD; Sunita M. Patil², MD

1. DY Patil Deemed University and Medical College, Kolhapur, Maharashtra, India
2. Sangeeta Hospital for Children, Near Rankala, Kolhapur, Maharashtra, India

Received: Jan 05, 2012; Accepted: Feb 17, 2012;
First Online Available: May 24, 2013

Many case reports and incidences of accidental intra-arterial (IA) injection of medications have been published so far^[1,2]. The common medications reported are barbiturates and benzodiazepines, including the anesthetic agents. There is only one case report of accidental intra-arterial injection of adenosine^[3].

A 14 years old boy was referred from a peripheral hospital as a case of supraventricular tachycardia (SVT). He was complaining of palpitation and chest pain. His heart rate was 200/min and was hemodynamically stable (temperature 36.7°C, breath rate 25/min, blood

pressure 110/70 mmhg, capillary refill time of 2 seconds, pulse oximeter oxygen saturation of 97% without oxygen administration and a normal sensorium). The body weight was 50 Kg. The systemic examination revealed S3 gallop and tender hepatomegaly. The ECG confirmed SVT. The vagal maneuver (carotid massage) failed. Intravenous adenosine was ordered. 22-gauge intravenous cannula was inserted into a superficial vessel over the radial styloid process at the base of the anatomical snuff box of the right wrist. The intravenous cannula was fixed after flushing with 1 ml of water for injection without pain or difficulty. The adenosine injection 5 mg was administered as a fast bolus followed immediately by rapid push of 10 ml isotonic saline with the help of a 3-way stop-cock. This immediately resulted in intense pain and flushing and hyperemia of the skin of the right hand. He complained of blurring of vision and dizziness. These symptoms completely disappeared spontaneously within 5 minutes. The cannula was not removed immediately. It was noticed that the back flow of blood was bright red in color. There was pulsatile movement of blood in the intravenous tubing with back flow of blood in the tubing when the saline bottle was attached to the cannula. Blood gas analysis from the cannula revealed pH_a 7.44, PaCO₂ of 34 mmHg, and a PaO₂ of 100 mmHg while the patient was not administered oxygen, confirming an inadvertent arterial cannulation. The cannula was removed and newly placed in the left cubital vein and a repeat dose of adenosine was administered uneventfully. The SVT converted to normal rhythm. The subsequent examination of the right hand revealed no abnormality.

The incidence of accidental intra-arterial cannulation and drug administration is reported to be as rare as 1 in 56,000 to as common as 1 in 3440^[1,2]. Adenosine is the drug of choice in acute management of SVT in a hemodynamically stable patient^[4]. It is a metabolite of adenosine triphosphate and has a very short half-life (1.5 s)^[5]. The case reported by ter Schure et al^[3] with accidental intra-arterial adenosine injection

* Corresponding Author; Address: Plot No 23, Anita Vandan Saharivas colony, Nagala Park, Kolhapur -416001, Maharashtra, India
E-mail: drmandarpatil@hotmail.com