

## Long-term Results of Balloon Pulmonary Valvuloplasty in Children with Congenital Pulmonary Valve Stenosis

Maostafa Behjati-Ardakani<sup>\*1</sup>, MD; Seyed-Hossien Moshtaghion<sup>2</sup>, MD; Shahrokh Rajaei<sup>3</sup>, MD

1. Yazd Cardiovascular Research Center, Shahid Sadoughi University of Medical Sciences, Yazd, Iran
2. Department of Anesthesiology, Shahid Sadoughi University of Medical Sciences, Yazd, Iran
3. Department of Pediatrics, Hormozgan University of Medical Sciences, Bandar Abbas, Iran

Received: Jun 21, 2012; Accepted: Sep 29, 2012; First Online Available: Dec 25, 2012

### Abstract

**Objective:** Immediate, short and midterm outcome of balloon pulmonary valvuloplasty are well known, but there is limited information on long term results. We report long term results of 2–13.5 years follow up of balloon pulmonary valvuloplasty in children.

**Methods:** From June 1998 to January 2012 sixty consecutive patients (33 females, 27 males) with moderate to severe valvar pulmonary stenosis (right ventricular to pulmonary artery pressure gradient greater than 50 mmHg) were considered for balloon valvuloplasty. The gradient was measured pre and immediately post-valvuloplasty at catheterization, and then by echocardiography at follow up. Follow up studies were performed 2–13.5 years (mean±SD; 7.1±2.5 years, median: 5.5 years) after procedure, by Doppler echocardiography in all patients and catheterization and angiography in two patients.

**Findings:** Balloon pulmonary valvuloplasty BPV was successful in 53 of 60 (88.3%) patients whereas surgical valvotomy was necessary in 6 to 60 (10%). There was one immediate death due to perforation of the right ventricular outflow tract. Pulmonary valve systolic pressure gradient decreased from 83.3±32.1 to 19.3±14.2 mmHg immediately after BPV and to 12.3±6.6 mmHg at late follow up ( $P<0.001$ ). Pulmonary insufficiency was noted in 20 (38%) patient at short-term, but it was demonstrated in 17 (32%) at late follow up. A second valvuloplasty was performed in two (3.8%) patients presenting with re-stenosis.

**Conclusion:** The short, intermediate and long-term outcomes of pulmonary balloon valvuloplasty in children are excellent. Therefore it can be considered as the treatment of choice for children with pulmonary valve stenosis.

*Iranian Journal of Pediatrics, Volume 23 (Number 1), February 2013, Pages: 32-36*

**Key Words:** Pulmonary Valve Stenosis; Balloon Valvuloplasty; Children

### Introduction

Surgical valvotomy was the traditional method of treatment of congenital pulmonary valve stenosis (PVS) until 1982.

The technique of balloon pulmonary valvuloplasty was introduced initially by Kan et al<sup>[1]</sup> in 1982. Since then, many other workers have reported successful application of this technique

to treat patients with moderate to severe pulmonary valve stenosis<sup>[2,3]</sup>. Immediate, short and mid-term results of BPV have been well documented<sup>[4-7]</sup>. However, there are limited data on long term outcomes<sup>[7-10]</sup>.

The purpose of this report is to evaluate the results of long term follow up of balloon pulmonary valvuloplasty in 60 children.

\* Corresponding Author;

Address: Yazd Cardiovascular Research Center, Afshar Hospital, Jomhuri Boulevard, Yazd, Iran

E-mail: dr\_behjati@yahoo.com

© 2013 by Pediatrics Center of Excellence, Children's Medical Center, Tehran University of Medical Sciences, All rights reserved.

## Subjects and Methods

From June 1998 to January 2012, 60 patients with moderate to severe pulmonary valve stenosis were considered for balloon pulmonary valvuloplasty. A child of 2.2 years died during the procedure due to infundibular rupture. Six patients were excluded because of dysplastic pulmonary valve in 4 cases and infundibular spasm and failure to cross the pulmonary valve with balloon catheter in 2 cases.

Therefore 53 patients (28 females, 25 males) of  $\text{mean} \pm \text{SD}$  age  $3.2 \pm 2.2$  years (range 0.4–8 years) underwent balloon pulmonary valvuloplasty with Tyshak balloon catheter.

The gradient was measured pre and immediately post valvuloplasty. Follow up at 24 hours, 3 months, 1 year and yearly ( $\text{mean} \pm \text{SD}$   $7.1 \pm 2.5$  years, median: 5.5 years) thereafter included physical examination and Doppler echocardiography. Doppler echocardiography assessed the maximum peak instantaneous gradient across the pulmonary valve and pulmonary regurgitation.

**The procedure:** Informed consent was obtained from the parent of patients. All procedure was performed under general anesthesia. A 6-French pigtail catheter was inserted with Seldinger technique, through the right or left femoral venous sheath into the right size of the heart for right ventriculography. Right ventriculography was done in anteroposterior and left lateral views (Fig. 1).

The diameter of the orifice and annulus of pulmonary valve was measured from hinge point to hinge point during systole from lateral view of

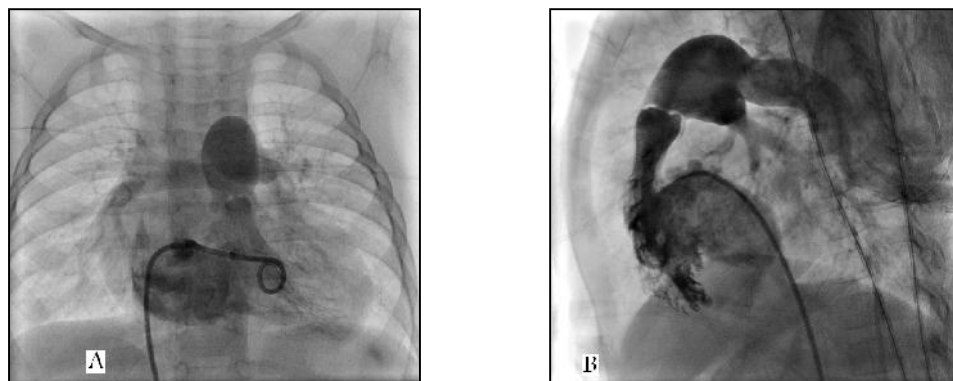
the right ventricular angiogram. The maximal diameter of the Tyshak balloon was chosen in accordance with the diameter of pulmonary valve annulus. The diameter of the balloon catheter was 10-20% larger than that of the pulmonary valve annulus. A no. 4 to no. 6 French multipurpose A2 (Cordis) catheter was introduced into the femoral venous sheath and advanced across the pulmonary valve and the tip of the catheter positioned in the distal left or right pulmonary artery branch and then multipurpose catheter was replaced with a Tyshak balloon catheter.

When the exchange wire was stabilized, balloon catheter was pulled back until the middle portion of the balloon was positioned just across the pulmonary valve. The balloon was fully inflated within few seconds and then quickly deflated. Inflations were repeated until a satisfactory reduction in the gradient was detected (Fig. 2).

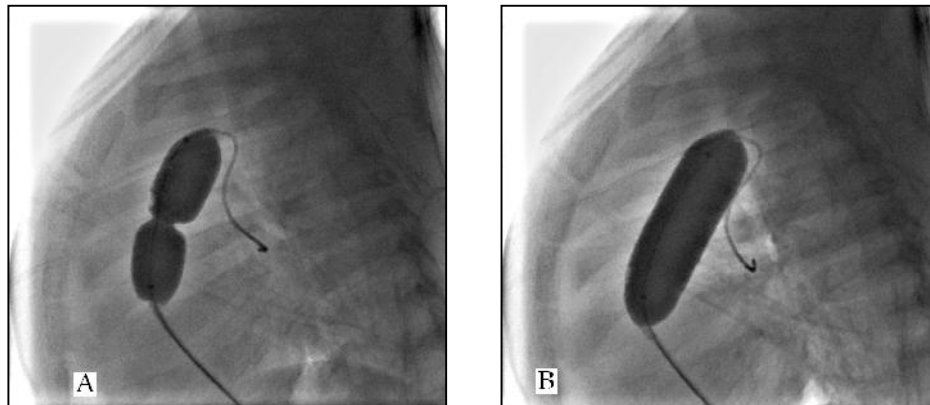
**Statistical analysis:** Normally distributed continuous variables were expressed as mean  $\pm$  standard deviation (SD). Pressure gradients before and immediately after balloon valvuloplasty and at long-term follow-up were compared by two tailed or paired *t*-tests. A *P*-value  $< 0.05$  was considered statistically significant.

## Findings

Fifty four of sixty patients with an age range of 0.4–8 years ( $\text{mean} \pm \text{SD}$   $3.2 \pm 2.2$  years) underwent pulmonary balloon valvuloplasty. The mean (SD) weight was  $12.2 \pm 4.7$  Kg (range: 6.3–24 Kg).



**Fig. 1:** Right ventriculogram in anteroposterior (A) and left lateral (B) views showing severe pulmonary valve stenosis, thickened domed pulmonary valve and post stenotic dilatation of main pulmonary artery



**Fig. 2:** A: left lateral view of a partially inflated balloon catheter positioned across the pulmonary valve. As the balloon is inflated a waist appears at the site of pulmonary valve. B: the balloon waist completely disappeared on the left lateral view, suggesting valvuloplasty had been effective

Ten cases were infants, and remaining 44 cases were between 1 and 8 years old. There were associated cardiac defects in six patients. The associated defects included: ASD in two, patent ductus arteriosus in 3 and left pulmonary artery branch stenosis in one. Transcatheter closure of ASD's and PDA's was performed with Amplatzer device. Demographic data of the patients are shown in Table 1.

Immediate, short, mid-term and long-term follow up: The peak-to-peak systolic pressure gradient across the pulmonary valve was more than 50 mmHg in all patients before procedure. It reduced from  $83.28 \pm 32$  (range: 55–170 mmHg) before BPV to  $19.3 \pm 14.2$  (range: 0–75 mmHg) immediately after BPV ( $P < 0.005$ ), to  $15.1 \pm 9.5$  mmHg (range: 0–48 mmHg) at short term follow up (defined as three months or less) ( $P < 0.001$ ).

The maximum peak instantaneous Doppler pressure gradient also declined from  $15.1 \pm 9.5$  at short term to  $13.02 \pm 7.03$  (range 0–36 mmHg at intermediate-term (as defined 3 months to 1

year) ( $P < 0.001$ ) and to  $12.3 \pm 6.6$  mmHg (range: 0–32) at long-term follow up ( $P = 0.02$ ). Two (3.8%) of 53 patients had re-stenosis (defined as a pressure gradient 50 mmHg or more) at intermediate-term follow up. One of these patients underwent repeat balloon valvuloplasty at an interval of 3 months and one other at 3 years after initial balloon dilatation: peak to peak gradient was reduced from 75 to 42 mmHg and also in other one the peak instantaneous Doppler gradient declined from 60 mmHg at midterm to 32 mmHg at long term follow up. There was one immediate death because of cardiac tamponade following rupture of right ventricular outflow tract. Two to 12.5 years follow up (median 5.5 years) was available in 53 patients. All patients remained asymptomatic at follow up.

The maximum peak instantaneous pressure gradient across pulmonary valve was  $12.3 \pm 6.6$  mmHg at long-term follow up. It is significantly lower than the gradient seen before balloon dilatation, at short-term ( $P < 0.001$ ) and at

**Table 1:** Demographic and catheterization data of patients

| Parameter                 | Mean (SD)    | Median | Range   |
|---------------------------|--------------|--------|---------|
| Age (yrs)                 | 3.2 (2.2)    | 2      | 0.4-8   |
| Weight (kg)               | 12.2 (4.7)   | 11     | 6.3-24  |
| Pulmonary annulus (mm)    | 14.23 (2.71) | 14.00  | 10-19   |
| Balloon size (mm)         | 16.02 (3.00) | 16.00  | 12-22   |
| PG across PV, mmHg (BBV)  | 83 (32)      | -      | 55-170  |
| PG across PV, mmHg (IABV) | 19.3 (14.2)  | -      | 0-75    |
| PG across PV, mmHg (LFU)  | 12.3 (6.6)   | -      | 0-32    |
| Balloon/ annulus ratio    | 1.13 (0.11)  | 1.16   | 1.1-1.2 |

SD: standard deviation; PG: pressure gradient; PV: pulmonary valve; BBV: before balloon valvuloplasty; IABV: immediate after balloon valvuloplasty; LFU: late follow up

intermediate-term ( $P=0.02$ ) follow up.

Pulmonary regurgitation was absent in 33 (62.2%) cases, mild in 18 (34%) and moderate in 2 (3.8%) at short-term follow up. Incidence of pulmonary regurgitation by Doppler echocardiography was lower ( $P<0.001$ ) at follow up, 20 (38%) cases at short-term versus 17 (32%) cases at long-term). On the basis of absence of right ventricular dilatation and the lack of paradoxical septal motion, none of the patients had significant pulmonary regurgitation. Surgical or transcatheter pulmonary valve replacement for treatment of pulmonary regurgitation was not required.

## Discussion

This study demonstrates that balloon pulmonary valvuloplasty provides long-term relief of stenosis of the pulmonary valve in the majority of patients with moderate to severe pulmonary valve stenosis. A re-stenosis with gradient  $>30$  mmHg was observed only in 4 (7.5%) patients at short term and in 2 (3.8%) patients at intermediate and long-term follow up. Actuarial re-intervention free rates were 98% and 96% at intermediate and long-term follow up respectively.

Therefore in current study incidence of persistent stenosis was low which can be related to the use of large balloon (10%-20% excess of annulus diameter). While the initial recommendations were to use balloons that are 20-40% larger than the pulmonary valve annulus, recent reports of pulmonary insufficiency at late follow up, raised concern regarding balloon size<sup>[11]</sup>. Nowadays it is recommended that pediatric cardiologist strives for a balloon/annulus ratio of 1.1-1.2 instead of previously recommended 1.2-1.4 ratio.

Use of balloon 1.1-1.2 times larger than pulmonary valve annulus may produce optimal result while at the same time may help prevent significant pulmonary insufficiency at late follow up.

In our study incidence of pulmonary valve dysplasia was 6.7% that is lower than in the study (8% ) by Jarrar et al<sup>[12]</sup>. We observed a further reduction in the total pressure gradient across

pulmonary valve at short, intermediate and long term follow up, a finding comparable to other studies that report follow up data<sup>[8-10,13-15]</sup>.

In our study incidence of pulmonary regurgitation was low (38%) at short term and (32%) at long-term follow up. This result is comparable to study of Jarrar et al<sup>[12]</sup>.

Incidence of pulmonary regurgitation was higher in most studies. It was 45% in the report by O'Connor et al<sup>[16]</sup>, 80% in the Rao et al study<sup>[17]</sup> and 85% in the McCrindle, et al<sup>[18]</sup> and 95% in the Hatem et al<sup>[8]</sup> studies.

Perforation of right ventricular outflow tract was the major complication in one patient with fatal event. This complication is rare and it usually occurs in neonates or infants with critical pulmonary stenosis and hypoplastic pulmonary valve<sup>[19-21]</sup>. In our study the patient was an infant with hypoplastic pulmonary valve.

In current study rate of major complication (perforation of RVOT) was 1.9%<sup>[19,22]</sup>, while in some studies it was higher (7.3%-16.6%) than in our study, but it was lower in most studies<sup>[8,12,18,23]</sup>.

## Conclusion

Our study shows balloon valvuloplasty is a safe and effective treatment of moderate and severe pulmonary valve stenosis. The short, intermediate and long-term results in children are excellent. Therefore PBV can be considered as the treatment of choice for children with valvar pulmonary stenosis. However, longer-term (15-20 years) follow up results are unknown. Also longer-term follow up to evaluate the pulmonary regurgitation is necessary.

## Acknowledgment

This study was supported in part by a grant from the Yazd cardiovascular research center. The study was approved by the medical ethics committee of Shahid Sadoughi University of Medical Sciences. We thank Mr MH Fallahzadeh for assistance with collecting data and statistical analysis.

**Conflict of Interest:** None

## References

1. Kan JS, White RI Jr, Mitchell SE, Gardner TJ. Percutaneous balloon valvuloplasty: a new method for treating congenital pulmonary valve stenosis. *N Engl J Med* 1982;307(9):540-2.
2. Schmaltz AA, Bein G, Grävinghoff L, et al. Balloon valvuloplasty of pulmonary stenosis in infants and children: co-operative study of the German Society of Pediatric Cardiology. *Eur Heart J* 1989;10(11):967-71.
3. Stanger P, Cassidy SC, Girod DA, et al. Balloon pulmonary valvuloplasty: results of the valvuloplasty and angioplasty of congenital anomalies registry. *Am J Cardiol* 1990;65(11):775-83.
4. Akçurur G, Kahramanyol O, Atakan C. Intermediate-term follow-up results of pulmonary balloon valvuloplasty in children. *Turk J Pediatr* 2000;42(2):126-31.
5. Luo F, Xu WZ, Xia CS, et al. Percutaneous balloon pulmonary valvuloplasty for critical pulmonary stenosis in infants under 6 months of age and short and medium term follow-up. *Zhonghua Er Ke Za Zhi* 2011;49(1):17-20.
6. Cheragh H, ul Hassan M, Hafizullah M, Gul AM. Outcome of balloon pulmonic valvuloplasty with 18 months follow up. *J Ayub Med Coll Abbottabad* 2009;21(3):95-9.
7. Hernández Cobeño MA, Bermúdez-Cañete R, Herraiz I, et al. Percutaneous balloon pulmonary valvuloplasty: the medium-term results in a series of 100 consecutive pediatric patients. *An Esp Pediatr* 1998;49(3):264-72.
8. Hatem DM, Castro I, Haertel JC, Rossi RI, et al. Short- and long-term results of percutaneous balloon valvuloplasty in pulmonary valve stenosis. *Arq Bras Cardiol* 2004;82(3):221-7.
9. Juárez Rodríguez M, Alva Espinosa C, Ledesma Velasco M, et al. Balloon pulmonary valvuloplasty, 15-year experience at the Siglo XXI IMSS National Medical Center. *Arch Cardiol Mex* 2003;73(3):190-6.
10. Lázaro Castillo JL, Munayer Calderón J, Aldana Pérez T, et al. Pulmonary valvuloplasty. Long term results at the Centro Medico la Raza. *Arch Inst Cardiol Mex* 1999;69(4):338-43.
11. Rao PS. Percutaneous balloon pulmonary valvuloplasty: state of the art. *Catheter Cardiovasc Interv* 2007;69(5):747-63.
12. Jarrar M, Betbout F, Farhat MB, et al. Long-term invasive and noninvasive results of percutaneous balloon pulmonary valvuloplasty in children, adolescents, and adults. *Am Heart J* 1999;138(5 Pt 1):950-4.
13. Mahnert B, Paul T, Luhmer I, Kallfelz HC. Intermediate and long-term outcome after percutaneous balloon dilatation of valvular pulmonary stenoses in childhood. *Z Kardiol* 1996;85(7):482-8.
14. Yu ZX, Ma YT, Yang YN, et al. Outcome of percutaneous balloon pulmonary valvuloplasty for patients with pulmonary valve stenosis. *Zhonghua Xin Xue Guan Bing Za Zhi* 2009;37(11):1006-9.
15. Weryński P, Rudziński A, Król-Jawień W, Kuźma J. Percutaneous balloon valvuloplasty for the treatment of pulmonary valve stenosis in children - a single centre experience. *Kardiol Pol* 2009;67(4):369-75.
16. O'Connor BK, Beekman RH, Lindauer A, Rocchini A. Intermediate-term outcome after pulmonary balloon valvuloplasty: comparison with a matched surgical control group. *J Am Coll Cardiol* 1992;20(1):169-73.
17. Rao PS, Fawzy ME, Solymar L, Mardini MK. Long-term results of balloon pulmonary valvuloplasty of valvar pulmonic stenosis. *Am Heart J* 1988;115(6):1291-6.
18. McCrindle BW, Kan JS. Long-term results after balloon pulmonary valvuloplasty. *Circulation* 1991;83(6):1915-22.
19. Gildein HP, Kleinert S, Goh TH, Wilkinson JL. Treatment of critical pulmonary valve stenosis by balloon dilatation in the neonate. *Am Heart J* 1996;131(5):1007-11.
20. Wang JK, Wu MH, Lee WL, et al. Balloon dilatation for critical pulmonary stenosis. *Int J Cardiol* 1999;69(1):27-32.
21. Luo F, Xu WZ, Xia CS, et al. Percutaneous balloon pulmonary valvuloplasty for critical pulmonary stenosis in infants under 6 months of age and short and medium term follow-up. *Zhonghua Er Ke Za Zhi* 2011;49(1):17-20.
22. Buheitel G, Böhm B, Koch A, et al. Balloon dilatation of the pulmonary valve. Short-, middle- and long. *Z Kardiol* 2001;90(7):503-9.
23. Fawzy ME, Hassan W, Fadel BM, et al. Long-term results (up to 17 years) of pulmonary balloon valvuloplasty in adults and its effects on concomitant severe infundibular stenosis and tricuspid regurgitation. *Am Heart J* 2007;153(3):433-8.