

## Airway Management in a Toddler with a Giant Hemangioma of the Tongue

Asghar Hajipour<sup>1\*</sup>, MD; Mihan J. Javid<sup>1</sup>, MD, and Babak Saedi<sup>2</sup>, MD

1. Department of Anesthesiology, Tehran University of Medical Sciences, Tehran, Iran,
2. Department of Otolaryngology, Tehran University of Medical Sciences, Tehran, Iran

Received: Mar 08, 2011; Final Revision: Feb 22, 2012; Accepted: Mar 15, 2012

### Abstract

**Background:** Induction of general anesthesia in a patient with compromised airway has always caused dilemma to anesthesiologist, especially for toddler this is paramounted.

**Case Presentation:** An 18 month old boy had a huge sized lingual mass which not only filled entire oral cavity but protruded outside the mouth up to about 5 cm. Having in mind the diagnosis of hemangioma, prior to induction it was attempted to reduce the mass but could be reduced only minimally by manual decompression. While the tongue, still outside the mouth, with full preparedness for anesthesia was induced maintaining the spontaneous ventilation. During laryngoscopy and intubation the tongue was pulled out of the oral cavity to ease the passage of the endotracheal tube. The mass was excised successfully and patient had an uneventful postoperative course.

**Conclusion:** Maintenance of spontaneous ventilation is the crucial safety element during induction.

*Iranian Journal of Pediatrics, Volume 22 (Number 4), Dec 2012, Pages: 551-554*

**Key Words:** Hemangioma; Vascular malformation; Tongue

### Introduction

Vascular abnormalities are relatively uncommon lesions, but head and neck is a common region of vascular malformation, which is classified as a benign tumor<sup>[1,2]</sup>. Huge lingual vascular malformation may cause peculiar problems, such as susceptibility to trauma and bleeding (due to biting), obstructive symptoms (difficulties with breathing, chewing, swallowing, speech), delay in linguistic development and compromised airway<sup>[3,4]</sup>. Although observation is the mainstay treatment, patients continue to seek treatment in order to relieve their symptoms<sup>[4]</sup>. The recommended treatment of hemangioma in special situation is steroids or surgical removal<sup>[1,3]</sup>.

When the plan becomes a surgical resection, then the role of anesthesiologist is very critical. With huge sized tongue and small child, the management of airway becomes a vital issue in anesthetic plan.

In this article, authors report a rare presentation of vascular malformation in the tongue<sup>[5]</sup> and the anesthesia plan for airway management.

### Case Presentation

An 18 month old toddler was brought to ENT outpatient clinic with a huge vascular mass of the

\* Corresponding Author;

Address: Anesthesiology Department, Imam Khomeini Medical Center, Keshavarz Blvd, Tehran, Iran

E-mail: dr.ahajipour@yahoo.com

© 2012 by Pediatrics Center of Excellence, Children's Medical Center, Tehran University of Medical Sciences, All rights reserved.

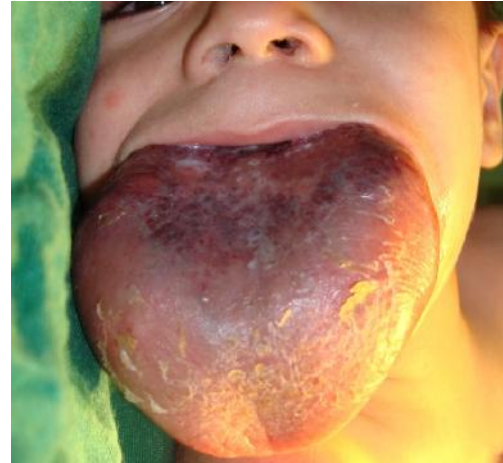tongue. This swelling began at 2 months of age with a rapid growth during the first year of life which was refractory to high doses of corticosteroid (prednisolone 4mg/kg for 4 weeks). The mass was so large that not only occupied entire oral cavity, but protruded from mouth and was hanging outside, to about the size of an adult fist (Fig 1).

Overgrowth of tongue had caused delayed linguistic development, swallowing difficulties repeated ulceration of the base of tongue, recurrent oral thrush, sleep apnea and snoring.

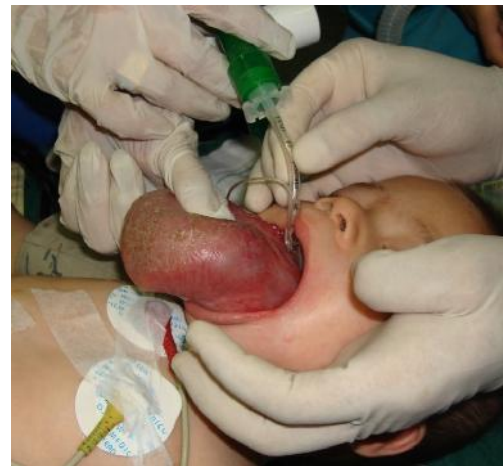Due to difficulties of delivery of anesthesia in imaging department, MRI could not be done for further diagnosis. The results of routine laboratory were normal.

On the operation table we palpated the whole mass and observed that it was extended almost up to the base of tongue. With attendance of two anesthesiologists and surgeon, and readiness of all equipment necessary for tracheostomy, we tried to squeeze the mass with wet gauze. It was decompressed up to 10%-15% of volume. With this minor decompression we were hardly able to place the hanging part of the tongue inside a no. 6 adult facial mask in supine position of the awake patient. After preliminary testing of airway patency, general anesthesia was induced slowly and smoothly with halothane and atropine as premedication. After 15-20 minutes surgical stage of anesthesia was reached. The tongue was pulled forward further with wet gauze helping the posterior and base of the tongue to be separated from palate and passage of laryngoscope was eased. A cuffed no. 3.5 endotracheal tube was passed through vocal cord successfully (Fig 2), then only sufentanyl and midazolam were administered. Anesthesia was maintained with isoflurane.

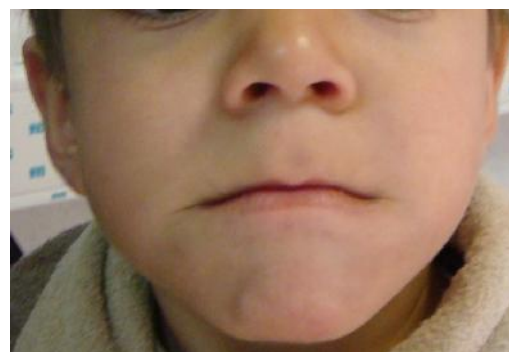
During surgery 130 cc packed cells was transfused. He was transferred to PICU where extubation was performed 48 hrs later without airway or respiratory difficulties. He was discharged from hospital 1 week later. Pathological diagnosis was cavernous hemangioma with focal thrombosis. One and half years later he was able to close the mouth, eat, and speak properly.



**Fig. 1:** Hemangioma of tongue with difficulty in feeding and speech



**Fig. 2:** Intubation eased by pulling the tongue out



**Fig. 3:** Patient one and half years after surgery

## Discussion

Although the vascular abnormalities per se are relatively uncommon lesions, hemangiomas are the most common soft tissue tumors of childhood [1,3,6]. Head and neck area, are the most common (about 60%) sites of hemangioma development<sup>[3]</sup>. In contrast to vascular malformations, hemangiomas usually regress spontaneously, therefore many clinicians recommend clinical observation alone<sup>[3]</sup>. However, therapeutic intervention may be indicated in children with compromised airway, bleeding or ulceration<sup>[3]</sup>. Therapeutic modalities may include steroid, cryotherapy, embolization, sclerotherapy, surgery and laser therapy<sup>[3,7]</sup>.

The hemangioma mass in this patient not only did not regress with steroid therapy, even increased in size and affected various aspects of his life and caused several complications. The huge size of the mass confronted us with great challenges, especially by selection of appropriate approach to airway management and anesthesia. The size of tongue and severe airway compromise, precluded a straight forward intravenous induction of anesthesia because of the high possibility of encountering a non ventilation scenario.

Intubation in awake patient also was precluded due to very large size of the tongue, possibility of further engorgement of this vascular tumor that could be caused by straining during intubation and noncooperation of the toddler. The third approach that we had on the desk was an elective tracheostomy under local anesthesia. Again for this procedure under local anesthesia at this age a calm child was required which was not possible without sedatives or anesthetics which was making us to return to the first step of selection of approach to anesthesia. On the other hand, we had in mind the higher rate of complications and mortality of the tracheostomy in children relative to adults<sup>[8,9]</sup>. For example the incidence of pneumothorax may be as high as 17%<sup>[10]</sup> or intrathoracic complication reported to be nearly 70% by Rabuzzi<sup>[10]</sup>, again obstruction and decannulation are the most serious early complications in children<sup>[11]</sup>. All these made us not

to select this approach as the first line. The last option that could be thought of was fiber optic intubation, though this technique also requires some kind of sedation in a toddler, we must confess that we neither had pediatric fiber optic equipment nor had expertise of performing it. Therefore this option was not feasible.

Anis Baraka reported a 5 year old boy with giant lingual hemangioma that had been successfully decompressed and induction of anesthesia was done by sevoflurane after insertion of an oral airway<sup>[12]</sup>. Decompression allowed room for passage of an oral airway which indicates a major reduction in the size of the tumor. Final approach left for us was induction of anesthesia with inhalation of halothane and 100% oxygen. However, we took all precaution and safety measurements mentioned in the previous section. In contrast to Baraka's report in our case decompression reduced the mass only minimally and after decompression, a huge mass was still hanging outside the mouth, and decompression only helped us to lodge the mass in an adult facial number 6 mask.

The other technique that helped us was pulling out the tongue as much as possible. This maneuver made a room to be available for laryngoscope to be passed behind the tongue, helping visualization of glottis aperture. At laryngoscopy and during intubation only a small BURP manual was required, and patient was intubated and surgery proceeded successfully. In conclusion with selection of this approach we avoided tracheostomy in a child less than 2 years of age and its attendant aftermath.

## Conclusion

Maintenance of spontaneous ventilation during induction of general anesthesia is the key factor in maintaining the compromised airway intact. This issue is of paramount importance in a toddler, since other approaches may entail use of some kind of sedation which may cause loss of some degree of airway.

## References

1. Eivazi B, Ardelan M, Baumler W, et al. Update on hemangiomas and vascular malformations of the head and neck: *Eur Arch Oto-Rhino-Laryngol* 2009;266(2):187-97.
2. Donald PJ. Vascular anomalies of the head and neck: *Facial Plastic Surgery Clin North Am* 2001; 9(1):77-92.
3. Werner JA, Dunne AA, Folz BJ, et al. Current concepts in the classification, diagnosis and treatment of hemangiomas and vascular malformations of the head and neck. *Eur Arch Otorhinolaryngol* 2001;258(3):141-9.
4. Chang CJ, Fisher DM, Chen YR. Intralesional photocoagulation of vascular anomalies of the tongue. 1999;52(3):178-81.
5. Richter GT, Suen J, North P, et al. Arteriovenous malformations of the tongue: A spectrum of disease. *Laryngoscope* 2007;117(2):328-35.
6. Kutluhan ABK, Ugras S. The treatment of tongue haemangioma by plasma knife surgery. *Singapore Med J* 2008; 49(11):312.
7. Waner M, Suen JY. Treatment of hemangiomas of the head and neck: *Laryngoscope* 1992; 102(10):1123-32.
8. Gianoli GJ, Miller RH, Guarisco JL. Tracheostomy in the first year of life. *Ann Oto-rhino-laryngol* 1990;99(11): 896-901.
9. Gilmore BB, Mickelson SA. Pediatric tracheostomy: controversies in management. *Otolaryngol Clin North Am* 1986;19(1):141-51.
10. Rabbuzi DD, Reed GF. Intrathoracic complications following tracheostomy in children. *Laryngoscope* 1971;81(6):939-46.
11. Swift AC, Rogers JH. The outcome of tracheostomy in children. *J Laryngol Otol* 1987; 101(9):936-9.
12. Baraka A. A simple approach to airway management in a child with a giant tongue hemangioma. *MEJ Anesth* 2007;19(2):469-70.