

Simultaneous Transcatheter Closure of Ventricular Septal Defect and Pulmonary Valvuloplasty

Mostafa Behjati Ardakani*¹, MD; Mahdi Haddadzadeh¹, MD; Shahrokh Rajaei², MD

1. Yazd Cardiovascular Research Center, Shahid Sadoughi University of Medical Sciences, Yazd, Iran
2. Department of Pediatrics, Hormozgan University of Medical Science, Bandar Abbas, Iran

Received: Jun 18, 2011; Final Revision: May 05, 2012; Accepted: May 27, 2012

Abstract

Background: Transcatheter balloon valvuloplasty has been the accepted first line treatment for congenital pulmonic stenosis (PS) in children. Transcatheter closure of perimembranous ventricular septal defect (VSD) with Amplatzer VSD occluder is an alternative to surgical repair.

Case Presentation: A 12 year old boy presented with history of exertional dyspnea and atypical chest pain. Physical findings were suggestive of severe pulmonic stenosis. Transthoracic echocardiography, right and left ventricular angiography showed medium to large sized perimembranous VSD and severe valvar pulmonary stenosis. Transcatheter closure of VSD was done first so as to avoid large left to right shunt across VSD after balloon pulmonary valvuloplasty.

Conclusion: We demonstrated the feasibility and success in treating combined ventricular septal defect and severe pulmonary valve stenosis with transcatheter interventional procedure in the same session.

Iranian Journal of Pediatrics, Volume 22 (Number 4), December 2012, Pages: 555-558

Key Words: Balloon Valvuloplasty; Simultaneous Transcatheter; VSD; Pulmonary Stenosis; Balloon Catheterization

Introduction

Congenital pulmonary valve stenosis (PVS) and perimembranous ventricular septal defect (PMVSD) are relatively common forms of congenital heart anomaly. Since the first report of balloon dilation of pulmonary valve stenosis in 1982^[1], it has been the treatment of choice for isolated moderate and severe pulmonary valvular stenosis in children^[2,3]. Transcatheter closure of perimembranous ventricular septal defect (VSD) is an interesting alternative to surgical repair^[4]. However, there are a few case reports where valvular pulmonic stenosis (PS) and PMVSD were

addressed simultaneously by transcatheter procedures. We report the successful concurrent percutaneous balloon dilatation of severe pulmonary valve stenosis and Amplatzer VSD occlusion of a large perimembranous VSD in a 12-year-old Iranian boy.

Case Presentation

A 12-year old boy presented with history of exertional dyspnea and atypical chest pain. Physical findings were suggestive of severe valvar

* Corresponding Author;

Address: Cardiovascular Research Center, Afshar Hospital Jomhoury Boulevard, Yazd, Islamic Republic of Iran

E-mail: dr_behjati@yahoo.com

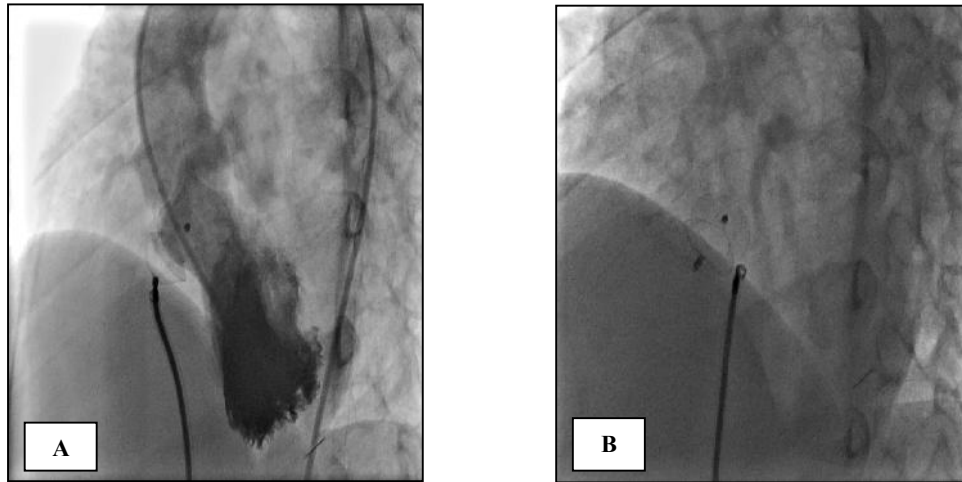


Fig. 1: (A) Left ventricular angiogram in left anterior oblique view before release of Amplatzer VSD occlude **(B)** Left anterior oblique view after release of Amplatzer VSD occluder

pulmonic stenosis. Electrocardiogram showed right axis deviation with right ventricular hypertrophy. Chest X Ray revealed normal sized heart with hypovascularity of lung fields. Echocardiography revealed medium sized perimembranous VSD and severe pulmonary stenosis with a peak systolic gradient of 85 mmHg across the pulmonary valve.

At cardiac catheterization, the right ventricular pressure was systemic (RV pressure = 115 mmHg) and the gradient across the pulmonary valve was 91 mmHg. There was a trivial net left to right shunt with calculated QP/QS of only 1.1. Right ventricular angiogram showed right ventricular hypertrophy with evidence of severe pulmonary stenosis. Main pulmonary artery, left and right pulmonary branches were dilated. A medium to large sized perimembranous VSD was appreciated by both right and left ventricular angiogram. Since both anomalies appeared amenable to percutaneous treatment, concurrent transcatheter therapy was planned after taking a written informed consent from the parents. The patient was started on heparin (100 IU/Kg) after obtaining venous and arterial access. The procedure was performed under local anesthesia and moderate sedation with pethidine and promethazine.

A decision was taken to close the VSD first, followed by dilation of pulmonary valve. The procedure was tried with Amplatzer VSD occluder No. 10 mm and 12 mm and could not be closed

due to large defect size. Therefore devices were retrieved. Then a 14 mm Amplatzer VSD occluder was implanted across the VSD and its position verified by left ventriculography and transthoracic echocardiography (Fig. 1A, 1B).

After VSD closure, there was no change in RV pressure and transpulmonic systolic pressure gradient. Therefore we decided to perform balloon pulmonary valvuloplasty.

Pulmonary valvuloplasty was performed with 25 mm pulmonary balloon catheter (25×40 mm, TYSHAK II, NUMED Canada inc.) (pulmonary valve annulus measured 23) (Fig. 2A, 2B). Immediately after balloon pulmonary valvuloplasty, right ventricular systolic pressure decreased from 115 to 45 mmHg, which resulted in a decrease in transvalvular gradient to 22 mmHg.

Echocardiography 24 h after procedure showed mild residual Ps (PG = 25mmHg) and no residual shunt. Follow up echocardiography at 1, 6 and 12 months showed mild residual Ps (PG = 20 mmHg) and no residual shunt.

Discussion

Since 1982^[1] balloon dilatation of the pulmonary valve has become an established treatment of choice in the management of isolated pulmonary valve stenosis in children^[2] as well as in

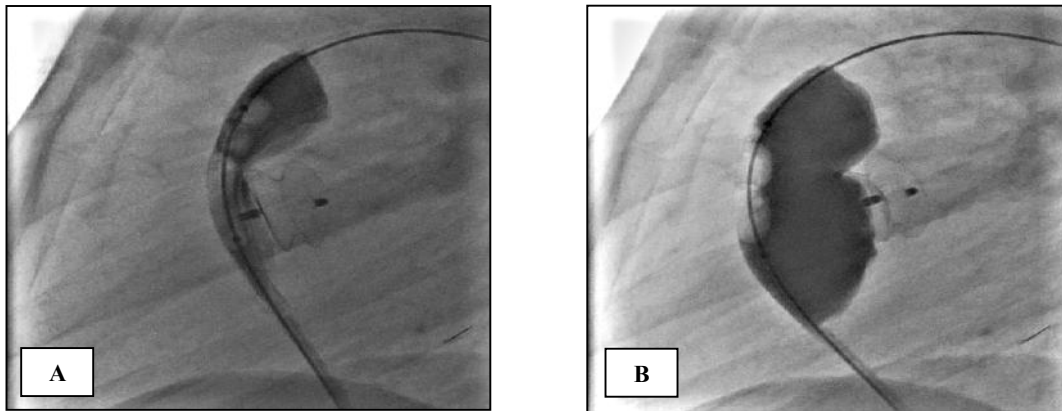


Fig. 2: (A) Lateral cinangiogram reveals an inflated 25 mm balloon with waist (arrow) across the stenosis (B) The balloon waist disappeared in the lateral view suggesting valvuloplasty has been successful

adolescents and adults^[5]. Both short and long term results of pulmonary balloon valvuloplasty in children and adults are excellent^[6,7]. Transcatheter closure of isolated perimembranous VSD is safe and effective^[8,9]. The major complication of PMVSD device closure is the development of complete heart block^[8,10].

Advances in transcatheter interventional therapy, have changed the therapeutic strategy for many patients with congenital heart anomaly. Many congenital heart diseases, such as VSD, atrial septal defect, patent ductus artriosus, PS, aortic stenosis, mitral stenosis and coarctation of the aorta now can be treated by transcatheter interventional technology^[11-14].

In a patient with ventricular septal defect and valvular pulmonary stenosis, treating one defect may lead to adverse hemodynamic effect on the other. There is a few case reports wherein transcatheter closure of VSD and pulmonary valvuloplasty were performed simultaneously^[11-12,15].

The decision to simultaneously attempt VSD device closure and valvuloplasty depends upon various factors: 1) the degree of pulmonary valve stenosis, 2) anatomy of the pulmonary valve, 3) size of VSD, 4) sufficient aortic margin of VSD, and 5) no aortic valve prolapse. Patient with moderate or severe pulmonary valve stenosis and associated medium or large VSD should be subjected to simultaneous closure of the VSD and balloon pulmonary valvuloplasty in the same catheter session.

In our patient ventricular septal defect was

done before pulmonary valvuloplasty. Certain technical consideration made us attempt the device VSD closure first. There was a fear of acute congestive heart failure and pulmonary edema as a result of increased pulmonary blood flow into previously protected pulmonary artery circulation. In addition, closure of VSD is technically more difficult and could take long time so the device was implanted before attempting balloon pulmonary dilation.

However, the advantage of simultaneous closure of VSD and pulmonary dilation is obvious, obviating of the need for thoracotomy, and open heart surgery, thus avoiding subsequent surgical scar and post operative pain. The only disadvantage of such a combined transcatheter therapy especially in a country like Iran is higher cost compared to open cardiac surgery^[16].

Conclusion

Transcatheter interventional therapy for compound VSD and valvar PS at the same time is feasible and effective without much added risk.

References

1. Kan JS, White RI Jr, Mitchell SE, Gardner TJ. Percutaneous balloon valvuloplasty: a new method for treating congenital pulmonary valve stenosis. *N Engl J Med* 1982;307(9):540-2.

2. Yip WGL, Tay JSH, Chan KY, et al. Percutaneous transluminal balloon valvuloplasty: the treatment of choice for congenital valvar pulmonary stenosis. *Ann Acad Med Singapor* 1990;19(1):58-63.
3. Ghannam R, Aouad A, Alami M, et al. Percutaneous transluminal valvuloplasty in congenital pulmonary stenosis in adult. A Propos of 34 cases. *Arch Mal Coeur Vaiss.* 1998;91(10): 1249-54.
4. Szkutnik M, Kusa J, Bialkowski J. Percutaneous closure of perimembranous ventricular septal defects with Amplatzer occluder- a single centre experience. *Kardiol Pol* 2008;66(9):941-9.
5. Chen CR, Cheng TO, Huang T, et al. Percutaneous balloon valvuplasty for pulmonic stenosis in adolescents and adults. *N Engl Med* 1996; 335(1):21-5.
6. Hatem DM, Castro I, Haertel JC, et al. Short and long term results of percutaneous balloon valvuloplasty in pulmonary stenosis. *Arq Bras Cardiol* 2004;82(3):221-7.
7. Fawzy ME, Hassan W, Fadel BM, et al. Long term results (up to 17 years) of pulmonary balloon valvuloplasty in adults and its effects on concomitant severe infundibular stenosis and tricuspid regurgitation. *Am Heart J* 2007;153(3): 433-8.
8. Yang R, Sheng Y, Cao K, et al. Transcatheter closure of perimembranous ventricular septal defect in children: safety and efficiency with symmetric and asymmetric occluders. *Catheter Cardiovac Interv* 2011;77(1):84-90.
9. Yang J, Yang L, Zuo J, et al. Transcatheter device closure of perimembranous ventricular septal defects: mid-term outcomes. *Eur Heart J* 2010; 31(8):2238-45.
10. Zuo J, Xie J, Yi W, et al. Results of transcatheter closure of perimembranous ventricular septal defect. *Am J Cardiol* 2010;106(7):1034-7.
11. Atiq M, Khan SA, Tipu FA, Amin Z. Combined treatment for multiple cardiac defects with interventional techniques. *Pediatr Cardiol* 2008; 29(5):890-83.
12. Song ZY, Shu MQ, HU HY, et al. Clinical efficiency and safety analysis of transcatheter interventional therapy for compound congenital cardiovascular abnormalities. *Clin Cardiol* 2007; 30(10):518-21.
13. Behjati M, Mirhosseini S, Hosseini S, et al. Transcatheter closure of atrial septal defect with amplatzer device in children and adolescents: short and midterm results; an iranian experience. *Iran J Pediatr* 2011;21(2):166-72.
14. Zanjani KS, Zeinaloo A, Malekan-Rad E, et al. Transcatheter atrial septal defect closure under transthoracic echocardiography in children. *Iran J Pediatr* 2011;21(4):473-8.
15. Cupta M, Juneja R, Saxena A. Simultaneous device closure of muscular ventricular septal defect and pulmonary valve balloon dilatation. *Catheter Cardiovasc Interv* 2003;58(4):545-7.
16. Zeinaloo AA, Meraji SM, Sayadpoor-Zanjani K, Miraghayan MR. Device occlusion versus surgery of closure of congenital heart defects, cost issues in Iran. *J Univ Heart Ctr* 2008;3(3):141-4.