

Congenital Insensitivity to Pain and Anhidrosis (CIPA) Syndrome; A Report of 4 Cases

Khadije Daneshjou, MD; Hanieh Jafarieh, MD*, and Seyed-Reza Raaeskarami, MD

Department of Pediatrics, Imam Komoini Hospital, Tehran University of Medical Sciences, Tehran, Iran

Received: Dec 03, 2010; Final Revision: Sep 27, 2011; Accepted: Nov 20, 2011

Abstract

Background: Background: Congenital insensitivity to pain with anhidrosis (CIPA) is characterized by recurrent episodes of infections and unexplained fever, anhidrosis (inability to sweat), and absence of reaction to noxious stimuli, self-mutilating behavior, mental retardation and damages to oral structures.

Case Presentation: In this article, we have demonstrated the signs and symptoms of 4 children that refer to the pediatrics department of the Imam Khomeini hospital and assay about their complications with this disease. They mostly presented by recurrent osteomyelitis in their feet that severely controlled by antibiotic therapy and even surgery. They had no pain sensation in spite of deep sore and infection.

Conclusion: This syndrome can be diagnosed by clinical and paraclinical tests together but it would be better to confirm by genetic test. The diagnosis of this syndrome helps us to try for the better quality of life for the patients and avoid unnecessary amputations.

Iranian Journal of Pediatrics, Volume 22 (Number 3), September 2012, Pages: 412-416

Key Words: CIPA Syndrome; Congenital Pain Insensitivity; Congenital Analgesia; Osteomyelitis

Introduction

Pain alters the quality of life more than any other health-related problem, and it is one of the implements of body protection. It interferes with sleep, mobility, nutrition, thought, sexual activity, emotional well-being, creativity, and self-actualization. Congenital insensitivity to pain is a rare disorder, first described in 1932 by Dearborn as Congenital pure analgesia. Congenital insensitivity to pain and anhidrosis (CIPA) is a very rare and extremely dangerous condition. People with CIPA cannot feel pain [1].

Pain-sensing nerves in these patients are not

properly connected in parts of brain that receive the pain messages. CIPA is extremely dangerous, and in most cases the patient doesn't live over age of 25. Although some of them can live a fairly normal life, they must constantly check for cuts, bruises, self-mutilations, and other possible unfelt injuries. Self-mutilation is an almost invariable feature of this disorder, most often involving the teeth, lips, tongue, ears, eyes, nose, and fingers [2-4].

The odds of being born with this condition are about 1 in 125 million. People with CIPA also cannot feel extreme temperatures, or sweat, both creating even more necessary care [5-7]. However, in a patient with CIPA, the gene encoding the

* Corresponding Author;

Address: Pediatrics Division, Imam Khomini Hospital, Keshavarz Blvd, Tehran, Iran

E-mail: hanieh_j@yahoo.com

Neurotrophic Tyrosine-Kinase receptor (NTRK1 gene), is mutated in a way that interferes and halts the autophosphorylation process, therefore stopping signals of pain and temperature from being sent to the brain^[8].

Case Presentation

Case 1: A 12 year old boy presented with chronic osteomyelitis. He was the fifth child of a consanguineous Iranian couple. In his birth history he had low Apgar score. There was no familial or hereditary disease in the family. Pregnancy was normal. He had several hospitalizations because of fever, seizure, heel sores and osteomyelitis. He had no reaction to pain and could not feel pain or heat. Brain CT scan and lumbar puncture findings were normal. Metabolic and TORCH study were negative. He is mentally retarded. The electromyography and nerve conduction velocity (EMG and NCV) were normal. The immune tests (complements, nitroblautetrazolium (NBT) test, immune globulins) and viral markers such as HBV, HCV and HIV tests, blood gas and serum uric acid were all normal.

This patient was referred to us to control the infection of hill sore (an ulceration measuring 10mm×10mm). We did our best to control the

infection by administering appropriate antibiotics and by the debridement of necrotic tissues to avoid limb amputation and to keep his quality of life as good as possible. He had also massive osteolysis in his mandible in which attempts were made for appropriate dental procedures. Obvious, self-mutilation, especially in his finger tips was observed. Radiographies also revealed osteolysis in his digit rum. The other sites such as lung, heart, abdomen and eyes were normal in physical examination (Fig. 1).

Case 2: A 13 year old girl was referred to our department because of purulent discharge from a deep sore in the talus and calcaneus of her right foot with history of recurrent osteomyelitis from the first months of life. She suffered from the absence of normal reaction to painful stimuli or heat. She occasionally had hyperthermia, and convulsions, high fever with abnormal electroencephalogram (EEG) and received anticonvulsant drugs. There was no family history of special or hereditary diseases. She was the second child of related (first cousins) parents. EMG-NCV, and immune tests were normal, and viral markers negative. The patient had first experienced osteomyelitis when she was 3 years old in her buttocks and lumbar sites. Her last hospitalization was because of a resistant infection which did not respond to different antibiotics during the 3 preceding months. Because of a harmful deformity in her heel and ineffective antibiotics, after an orthopedic consult,

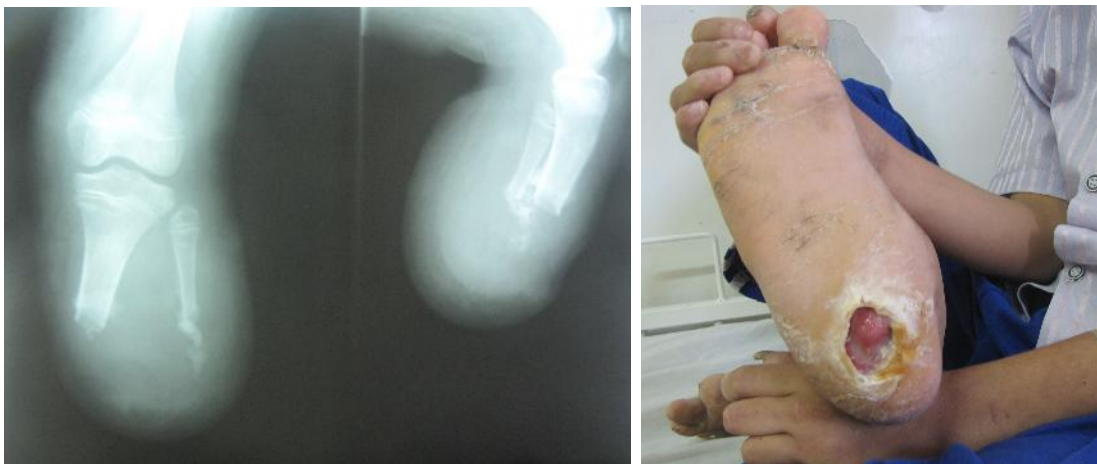

Fig. 1: Finger tip osteolysis (right) and painless heel sore (left) in a 12 year old boy with CIPA syndrome

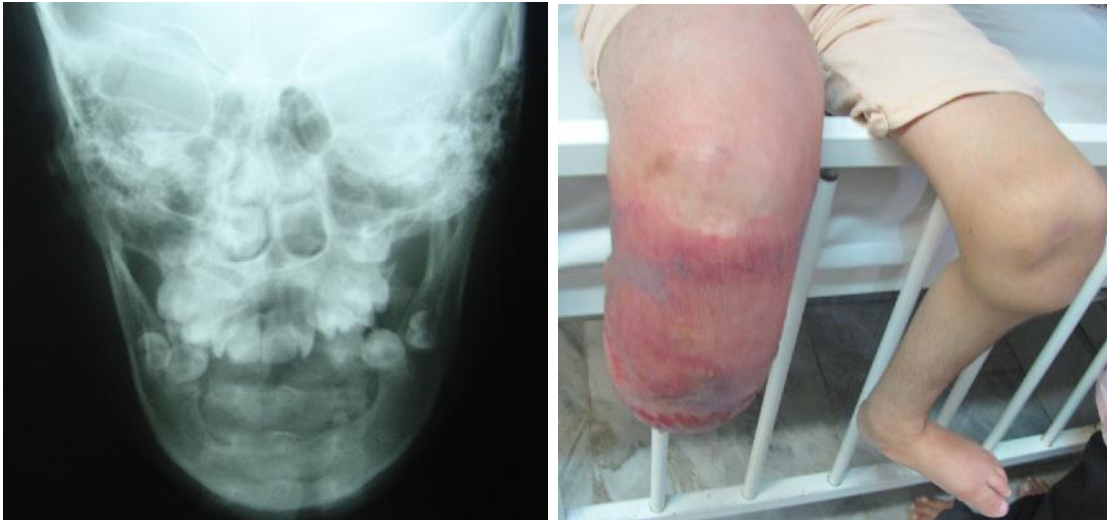

Fig. 3: Mandibular lysis, dental deformity and post amputation cellulitis, recurrent infection in a 13 year old girl with CIPA syndrome

an amputation was performed. Three weeks after the amputation, however, she came back with massive cellulitis in the site of surgery which progressed to the knee but she didn't feel any pain. Our case had also significant mandibular lysis and dental lisions. She was mentally retarded. Osteolysis on her fingertips was seen, but there was no sign of ocular disturbance (Fig. 3).

Case 3. An 8-year-old girl was referred to the pediatric department of Imam Khomeini Hospital because of fever, severe edema of right leg, inflammation and purulent discharge from the fistula in both legs especially right foot. She was mentally retarded and hit her heel onto the ground without any sensation of pain. She did not respond to any painful stimuli or heat shock, but could feel pressure and touch. There were some scars on her skin on different sites of the body which were, according to her parents, heat scars. Hands and fingers showed signs of biting. Because of chronic osteomyelitis, debridement of infectious site was performed and antibiotics administered several times. An EMG-NCV revealed a small fiber disturbance and low amplitude of SNAPS due to a skin problem. Immune tests, viral markers, blood gas and uric acid level were normal. She had no abnormality in ocular system. The EEG was mildly abnormal, and she was treated by antiepileptic drugs.

A Family history revealed that her parents were cousins, and she was the fourth child of this family with other children being normal. She had a history of recurrent seizures which were treated as a metabolic disease since she was 4 months old for 4 years but there was no efficacy (Fig 5).

Case 4: A 7 year old girl, the child of consanguineous (first cousins) parents, presented to the pediatrics department in Imam Khomeini Hospital 6 years ago with swelling and erythema in her right foot. Two siblings died at 2 and 3 years of age because of unknown reasons. She had a

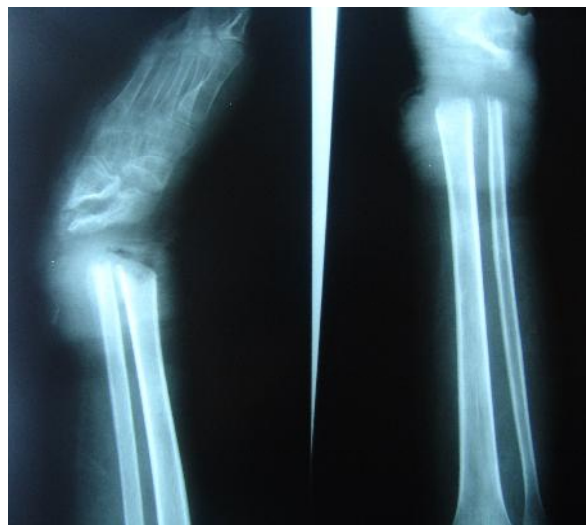


Fig. 5: Irregularity and lysis of bones

history of several episodes of osteomyelitis and gangrene of the right and left foot. Further, she had osteolytic lesions in her mandible and the vestibular epithelium of the mandible was destroyed. She was advised to do bone graft surgery. All of her teeth fell out when she was 3 years old, and she had total alopecia from 6th month of age. She also had history of recurrent fever, respiratory infection, cellulitis and osteomyelitis. The disease was misdiagnosed as chronic granulomatous disease (CGD) and treated with intravenous immunoglobulin (IVIG). In this admission immunologic tests including complement, NBT, and electrophoresis of immunoglobulins were normal. Seven years ago she became a candidate of amputation of her foot, but as she didn't agree, so received a graft and pin. Now she developed irregularity in the physeal and epiphyseal plate in tibia and fibula and had fracture of epiphyseal plate. Intelligence test was normal.

Discussion

CIPA is an autosomal recessive disease^[9], all of our patients had consanguineous parents. There are few cases of insensitivity to pain described in the literature, but there is no standard treatment ^[2]. Patients with CIPA can live a fairly normal life ^[4,7,10]. Three of our patients had mild mental retardation and attended special schools. However, there are certain precautions that need to be taken in order to ensure the safety of the patient. The patient must constantly check for cuts, bruises, self-mutilations, and other possible unfelt injuries. Also, they must regularly visit their doctor to receive a full work up to be sure that they do not have any insensitive internal problems that can be fatal. There are sixty documented cases in the United States^[1,9,11-17]. While some reports indicate that these patients can only live up to five years and predict a poor prognosis for this disorder ^[4,18,19,20], all of our patients were older. The reasons for death among patients with CIPA are things that could otherwise be treated. A heat attack, for instance, is much more dangerous for

patients with CIPA because they do not feel it, therefore do not know that they need to be hospitalized^[2,21,22]. Although Patients with CIPA often experience trauma, bony fractures, and osteomyelitis because of insensitivity to pain. Therefore, such patients may undergo surgery such as osteotomy and amputation, in three of our cases the involved joint was saved without amputation by utilizing conservative measures^[23]. Three of our patients had severe osteolysis in the oral cavity with osteolysis and finger tips amputation as a result of self mutilation. Congenital insensitivity to pain with anhydrosis may be misdiagnosed as leprosy, based on similar symptoms of severe injuries to the hands and feet, which is not match with our cases according to other findings^[24]. On the other hand, CIPA is the fourth type of hereditary sensory and autonomic neuropathy (HSAN), known as HSAN IV (It is also referred to as HSAN Type IV).

The aim of reporting this syndrome is to make physicians familiar with this condition and to avoid unnecessary surgeries and even amputations, to use conservative treatments and make the diagnosis of this syndrome easier without extra laboratory requests. Unfortunately in our country we do not have the facility to confirm the diagnosis by genetic tests so we have to start treatment by clinical and paraclinical findings to make the patients quality of life better.

Conclusion

This study shows that we should notice the combination of some different signs and symptoms to find this syndromic disease.

References

1. Dearborn G. A case of congenital pure analgesia. *J Nerv Ment Dis* 1932; 75:612-5.
2. Rasmussen P. The congenital insensitivity-to-pain syndrome (analgesia congenita). *Int J Paediatr Dent* 1996; 6:117-22.

3. Hall KH. Paediatric Orofacial Medicine and Pathology. 3rd ed. London: Chapman & Hall Medical. 1994; pp 330-5.
4. Narayanan V. Oral and maxillofacial manifestations of hereditary sensory neuropathy. *Br J Oral Maxillofac Surg* 1996; 34:446-9.
5. Nagasako EM, Oaklander AL, Dworkin RH. Congenital insensitivity to pain: An update. *Pain* 2003; 101:213-9.
6. Dick PJ. Neuronal atrophy and degeneration predominantly affecting peripheral sensory and autonomic neurons. In: Dick PJ, Thomas PK, Griffin JW, Low, PA, Podreslo, JC eds. *Peripheral Neuropathy*. 17th ed. Philadelphia: Saunders. 1993; pp 1065-93.
7. Emad MR, Raissi GR. Congenital insensitivity to pain with anhidrosis. *Electromyogr Clin Neurophysiol* 2003; 43:409-41.
8. Mardy S, Miura Y, Endo F, et al. Congenital Insensitivity to pain with anhidrosis (CIPA): effect of TRKA (NTRK1) missense mutations on autophosphorylation of the receptor tyrosine kinase for nerve growth factor. *Hum Mol Genet* 2011;10(3):179-88.
9. Kouvelas N, Terzoglou C. Congenital insensitivity to pain with anhidrosis. *Ped Dent* 1989;11(1):47-51.
10. Thompson CC, Park RI, Prescott Gh. Oral manifestation of the congenital insensitivity-to-pain syndrome. *Oral Surg Oral Med Oral Pathol* 1980;50(3):220-5.
11. Littlewood SJ, Mitchell L. The dental problems and management of a patient suffering from congenital insensitivity to pain. *Int J Paediatr Dent* 1998;8(1):47-50.
12. Rosenberg S, Nagahashi Marie SK, Kliemann S. Congenital insensitivity to pain with anhidrosis (hereditary sensory and autonomic neuropathy type IV). *Pediatr Neurol* 1994;11(1):50-6.
13. Brahim JS, Roberts MW, McDonald H. Oral and maxillofacial complications associated with congenital sensory neuropathy with anhidrosis. *J Oral Maxillofac Surg* 1987;45(4):331-4.
14. Shaaban H, Bayat A, Davenport P, et al. Necrotising fasciitis in an infant with congenital insensitivity to pain syndrome. *British J Plast Surg* 2002;55(2):160-3.
15. Auer-Grumbach M, De Jonghe P, Verhoeven K, et al. Autosomal dominant inherited neuropathies with prominent sensory loss and mutilations. *Arch Neurol* 2003;60(3):329-32.
16. Bonkowsky JL, Johnson CC, Smith AG, Swoboda KJ. An infant with primary tooth loss and palmar hyperkeratosis: a novel mutation in the NTRK1 gene causing congenital insensitivity to pain with anhidrosis. *Pediatrics* 2003;112(3 pt 1):237-41.
17. Boraz RA. Familial dysautonomia, Riley-Day syndrome. *J Dent Child* 1984;51(1):64-5.
18. Rakocz M, Frand M, Brand N. Familial dysautonomia with Riga-Fede's disease: report of case. *J Dent Child* 1987;54(1):57-9.
19. Nicholson GA, Dawkins JL, Blair IP, Kennerson ML, et al. The gene for hereditary sensory neuropathy type I (HSN-I) maps to chromosome 9q22.1-q22.3. *Nat Genet* 1996;13(1):101-4.
20. Irod FB, Hilz MJ. Inherited autonomic neuropathies. *Semin Neurol* 2003;23(4):381-90.
21. Verhoeven K, Coen K, De Vriendt E, et al. SPTLC1 mutation in twin sisters with hereditary sensory neuropathy type 1. *Neurology* 2004;62(6):1001-2
22. Lafreniere RG, MacDonald M, Dube M, et al. Identification of a novel gene (HSN2) causing hereditary sensory and autonomic neuropathy type II through the study of Canadian genetic isolates. *Am J Hum Genet* 2004;74(5):1064-73.
23. Smael Labib, Mohamed Adnane Berdai, Sanae abourazzak, Mustapha Hida, Mustapha Harandou. Congenital insensitivity to pain with anhidrosis: report of a family case. *Pan Afr Med J* 2011;9:33
24. Available at: http://en.wikipedia.org/wiki/Congenital_insensitivity_to_pain_with_anhidrosis#Differential_diagnosis