

## Extensive Mongolian Spots with Autosomal Dominant Inheritance

Beeregowda YC\*<sup>1</sup>, MD; Naveen Kumar BV<sup>1</sup>, MD, and Manjunatha YC<sup>2</sup>, MD, DNB

1. Department of Pediatrics, Sri Devaraj Urs Medical College, Tamaka, India
2. Department of Radiodiagnosis, Pondicherry Institute of Medical Sciences, Kalapet, India

Received: Dec 01, 2010; Final Revision: Feb 05, 2011; Accepted: Mar 13, 2011

### Abstract

**Background:** Mongolian spots are benign skin markings at birth which fade and disappear as the child grows. Often persistent extensive Mongolian spots are associated with inborn error of metabolism. We report thirteen people of the single family manifested with extensive Mongolian spots showing autosomal dominant inheritance.

**Case Presentation:** A one day old female child, product of second degree consanguineous marriage, born by normal vaginal delivery with history of meconium stained amniotic fluid and birth asphyxia. On examination the child showed extensive bluish discoloration of the body involving trunk and extremities in both anterior and posterior aspects associated with bluish discoloration of the tongue. A detailed family history revealed most of the family members manifested with extensive bluish discoloration of the body soon after birth which faded in the first few years of life and completely disappeared by puberty. Thus it was diagnosed to be extensive Mongolian spots with an autosomal dominant inheritance.

**Conclusion:** Knowledge about the natural history of extensive Mongolian spots, their inheritance and association with certain metabolic diseases mainly IEM and Mucopolysaccharidosis aids in the diagnosis and in order to improve the patient's prognosis.

*Iranian Journal of Pediatrics, Volume 22 (Number 2), June 2012, Pages: 252-254*

**Key Words:** Mongolian Spots; Dermal Melanocytosis; Inborn Error of Metabolism; Birth Marks

### Introduction

Mongolian spots are also called as congenital dermal melanosis. These skin lesions are mostly but, not exclusively seen in Asian children. They are usually 1-2 cm or smaller in size. These manifests as blue or slate gray macular lesions of varying sizes, most commonly located on lumbosacral, posterior thighs, legs and shoulders<sup>[1]</sup>. Extensive or generalized Mongolian spots usually involve whole of the anterior and

posterior aspects of the trunk, limbs and occasionally face. Although they are usually benign in character, Mongolian spots can cause significant anxiety for both parents and doctors due to their unusual appearance and unexpected location and number. They usually fade during first few years of life. Persistent extensive Mongolian spots are often associated with inborn error of metabolism (IEM) such as GM1-gangliosidosis and Mucopolysaccharidosis<sup>[2]</sup>. Knowledge about the natural history, inheritance and associations of

\* Corresponding Author;

Address: Department of Pediatrics, Sri Devaraj Urs Medical College, Tamaka, Kolar-563101 India

E-mail: manjuyc@gmail.com

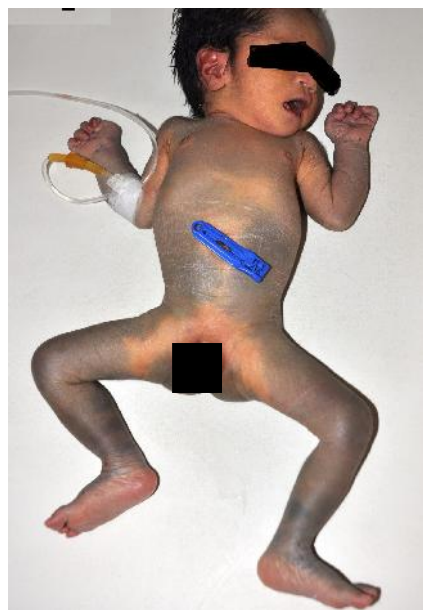these spots aids not only in the diagnosis of certain serious conditions but also in timely intervention of the disease.

### Case Presentation

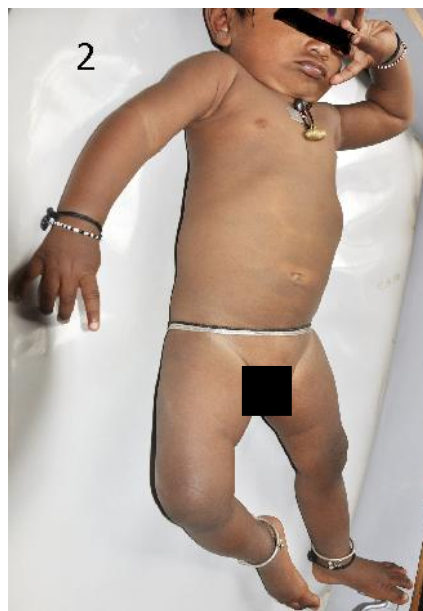A one day old female child, product of second degree consanguineous marriage, born by normal vaginal delivery with history of meconium stained amniotic fluid and birth asphyxia. On examination the child showed extensive bluish discoloration of the body involving trunk and extremities in both anterior and posterior aspects (Fig 1) associated with bluish discoloration of the tongue. Child has normal weight for the age (2.75 Kg), height for the age (47.5 cm), but the heart rate (160 beats/min) and respiratory rate (66 cycles/min) are increased. Peripheral pulses were palpable. General condition of the baby was poor with reduced oxygen saturation ( $SpO_2$  80% in room air). The baby did not have organomegaly and the fundus examination was normal. Routine blood investigations showed a total white cell count of 14000/cu mm, differential count: neutrophils - 87% with band forms of 3%. Blood was sent for culture and sensitivity treated with ampicillin and gentamycin. Three hours after admission the discoloration of tongue (cyanosis) had disappeared but there was persistent bluish discoloration of the body excluding face, palms, soles, external genitalia, and area around the nipples and areola (Fig 1). Blood culture did not reveal any growth. Hematological, urine and radiological (skeletal survey and ultrasound abdomen) examination workup for inborn errors of metabolism did not reveal any abnormality. Child recovered completely and was discharged after seven days.

A detailed family history revealed that most of the family members were manifested with extensive bluish discoloration of the body soon after birth as depicted in the Pedigree chart which faded in the first few years of life and completely disappeared by puberty. The fading extensive Mongolian spots were also seen in the first cousin of the patient (Fig 2). None of the family members

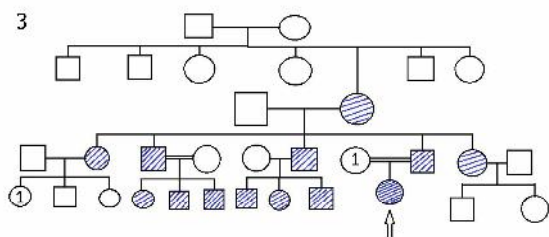
had developmental delay or history suggestive of metabolic disorders. Thus in view of characteristic family Pedigree presentation (Fig 3) of the bluish discoloration of the skin, which fades away in the later life, it was diagnosed to be extensive Mongolian spots of an autosomal dominant inheritance.



**Fig. 1:** Photograph of the child shows extensive Mongolian spots involving the trunk and extremities



**Fig. 2:** Photograph of the 9 months old first cousin of the baby (Fig 1) shows fading extensive Mongolian spots



**Fig. 3:** Pedigree chart showing autosomal dominant inheritance pattern of extensive Mongolian spots in the family. Arrow: case 1: Consanguineous marriage with maternal uncle

## Discussion

Mongolian spots or dermal melanocytosis result from failure of complete melanocyte migration into the epidermis before birth with ensuing dermal nesting and melanin production<sup>[1]</sup>. Among different ethnic groups, just under 10% of Americans, over 90% of African Americans, about 80% of Asians, about 70% of Hispanics and fewer than 10% of Caucasians have Mongolian spots<sup>[3]</sup>.

Mongolian spots are organized as being sacral or extra sacral. More than 75% of the lesions occur in the sacrogluteal region. The shoulder and extensor surface of the upper extremities are other relatively common locations. Mongolian spots uncommonly appear on the abdomen and chest and, rarely, on the palms or soles<sup>[1]</sup>. Certain atypical sites are also reported in mandibular and temporal region<sup>[4,5]</sup>.

The typical Mongolian spot is noted at birth and size may vary from a few millimeters to more than 10 cm. They may increase in size for 1 to 2 years and peak in color intensity at 1 year. They become less noticeable and eventually fade during the first few years of life but they occasionally persist. Histological examination of the lesion reveals a deep dermal melanocytic proliferation scattered among the collagen bundles. The stem cell factor and endothelin 3 are the major pilot growth factors targeting C-Kit and ED3R, respectively<sup>[1]</sup>.

The extensive Mongolian spots associated with inborn error of metabolism (IEM) such as GM1-gangliosidosis and Mucopolysaccharidosis show no sign of resolution. They may also become

heavier in their colors<sup>[6-8]</sup>. The association between Mendelian inheritance, benign extensive Mongolian spots and those with IEM is not reported so far in the literature. Whereas the above case typically follow autosomal dominant inheritance.

## Conclusion

To conclude, knowledge about the natural history of extensive Mongolian spots, their inheritance and association with certain metabolic diseases mainly IEM and Mucopolysaccharidosis aids in the diagnosis in order to improve the patient's prognosis.

## References

1. Taieb A, Boralier F. Hypermelanosis of newborn and of the infant. *Dermatol Clin* 2007;25(3):327-36.
2. Ochiai T, Suzuki Y, Kato T, et al. Mugishima H, et al. Natural history of extensive Mongolian spots in mucopolysaccharidosis type II (Hunter syndrome): a survey among 52 Japanese patients. *J Eur Acad Dermatol Venereol* 2007;21(8):1082-5.
3. Jacobs AH, Walton RG. The incidence of birthmarks in the neonate. *Pediatrics* 1976; 58(2):218-22.
4. Tanyasiri K, Kono T, Groff WF, et al. Mongolian spots with involvement of mandibular area. *J Dermatol* 2007;34(6):381-4.
5. Leung AK, Kao CP, Lee TK. Mongolian spots with involvement of the temporal area. *Int J Dermatol* 2001;40(4):288-9.
6. Ochiai T, Ito K, Okada T, et al. Significance of extensive Mongolian spots in Hunter's syndrome. *Br J Dermatol* 2003;148(6):1173-8.
7. Hanson M, Lupski J, Hicks J, et al. Association of dermal melanocytosis with lysosomal storage disease: clinical features and hypotheses regarding pathogenesis. *Arch Dermatol* 2003; 139(7):916-20.
8. Silengo M, Battistoni G, Spada M. Is there a relationship between extensive Mongolian spots and inborn error of metabolism? *Am J Med Genet* 1999;87(3):276-7.