



The Diagnosis of Early Fetal Cardiac Changes of the Gestational Diabetic Mothers: Presenting the Preload Index

Ehsan Aghaei Moghadam¹, Aliakbar Zeinaloo², Morteza Danaeian³, Sedigheh Hantoushzadeh⁴, Fahimeh Ghotbizadeh Vahdani¹, Ali Mazouri⁵, Ali Mohebbi⁴ and Azin Ghamari^{6,*}

¹Department of Pediatrics, Tehran University of Medical Science, Tehran, Iran

²Children's Medical Center, Pediatrics Center of Excellence, Tehran, Iran

³Maternal, Fetal and Neonatal Research Center, Vali-Asr Hospital, Tehran University of Medical Sciences, Tehran, Iran

⁴Growth and Development Research Center, Pediatrics Center of Excellence, Children's Medical Center, Tehran University of Medical Sciences, Tehran, Iran

⁵Iran University of Medical Science, Tehran, Iran

⁶Children's Medical Center, Pediatrics Center of Excellence, Tehran University of Medical Sciences, Tehran, Iran

*Corresponding author: Children's Medical Center, Pediatrics Center of Excellence, Tehran University of Medical Sciences, Tehran, Iran. Email: azin.ghamari1992@gmail.com

Received 2018 November 16; Revised 2019 January 19; Accepted 2019 February 13.

Abstract

Objectives: To evaluate fetal cardiac changes in gestational diabetic mothers, compared to healthy ones by means of different indices and to determine which index can first represent the alterations.

Methods: The study was conducted as an observational cross-sectional study, including 25 pregnant women with gestational diabetes as the cases and 50 healthy pregnant women as the controls. The preload index, left and right side myocardial performance index (MPI), Interventricular septal hypertrophy, the left and right side cardiac output were assessed in all the patients.

Results: The gestational ages were 31.65 ± 8.02 and 31.64 ± 5.37 weeks in case and control group respectively, without any significant difference. Both of the left and right ventricular MPI did not differ statistically between the case and controls. The cases had a greater Interventricular septal hypertrophy but the cardiac output was similar. The preload index was higher in the fetuses of the gestational diabetic mothers.

Conclusions: In our study, the MPI did not show any difference between the fetuses of the gestational diabetic mothers and non-diabetic ones; but, fetuses of gestational diabetic mothers had a greater value of PLI, representing early diastolic function changes in right heart even before the overt heart failure occurred. This could be a sign of vasculopathy in gestational diabetic mothers.

Keywords: Cardiac Function, Preload Index, Myocardial Performance Index, Gestational Diabetes, Fetal Echocardiography

1. Background

Diabetes mellitus is one of the most common endocrine disorders all over the world. It is estimated that 1 in 11 adults suffer from diabetes and gestational diabetes mellitus an impact of 1 in every 7 births (1). Abortion and congenital malformations occur as a result of poor glycemic control during contraception and first trimester (2, 3). Cardiac muscle hyperplasia, disorganized pattern of myofibrils (4) as well as activation of chronic inflammatory pathways by placental genes (5) are caused by maternal diabetes which brings about cardiac performance alteration and increased vulnerability to stress (6). Cardiac muscle contractility abnormalities, hyperbilirubinemia, neonatal hypoglycemia (7, 8) and diastolic dysfunction caused by impaired ventricular compliance (9) are the reported complications for the fetuses of the diabetic mothers. Fetal echocardiography plays a role as a non-invasive modality

for the evaluation of fetal heart anatomy, function and hemodynamics (10). Diastolic function can be assessed by Doppler echocardiography (11) and ventricular myocardial contraction and expansion during systole and diastole by tissue Doppler echocardiography (12, 13). Not affected by ventricular geometry and heart rate and including both systolic and diastolic parameters, myocardial performance index (MPI) has been emerged as useful Doppler index for the global cardiac function evaluation (10). E/A velocities at mitral and tricuspid valves are the tools for diastolic function assessment (14). Pre load index, first described by Kanzaki and Chiba (15), is an index which represents the right atrial pressure, by using the flow velocities in Inferior Vena Cava, reflecting the preload status of the heart.

2. Objectives

This study was conducted to investigate fetal cardiac ventricular function by evaluating preload index, MPI, E/A ratio, ventricular septal thickness and cardiac output and to determine which is more beneficial for detecting early myocardial changes.

3. Methods

3.1. Study Population

The study was conducted as an observational cross-sectional study, at a tertiary referral center, Children's Medical Center, Tehran, Iran. Between March 2016 and March 2017, 25 consecutive women with gestational diabetes mellitus and 50 healthy pregnant women were recruited. The evaluations were performed in 18 - 23 weeks of gestation. The diagnosis of the gestational diabetes was based on WHO criteria, with fasting plasma glucose < 7.0 mmol/L, 2-hour post prandial glucose level ± 7.8 mmol/L and < 11.1 mmol/L after ingestion of 75 gram glucose for tolerance test (16). The exclusion criteria were multiple pregnancies, congenital malformations, abnormal fetal heart rate, maternal systemic hypertension, systemic lupus erythematosus, pregnancy-induced hypertension, preeclampsia, eclampsia, chromosomal abnormalities, intrauterine growth restriction and pregnancy by assisted reproductive technology and any drugs prescribed for mother other than routine vitamins. The control group was selected among healthy patients with no remarkable obstetric history. HbA1c was controlled in all the participants, the level of which was below 6 in both cases and controls. The drug history was negative for Aspirin. The study was approved by our institutional review board and informed consent was obtained from all participants.

3.2. Imaging Protocol

All imaging studies were performed by a single physician using Philips affinity 70 w Ultrasound machine, with the convex probe (2 - 9 Hz). The structural abnormality was ruled out by an initial systemic 2-dimensional fetal echocardiography with high frame rate (60 - 150 frame/sec), the existence of malformations was checked in all standard views. The segmental sequential approach was taken for a complete fetal echocardiographic examinations (17). Three or more waveforms were recorded using pulsed Wave Doppler (PW), with isonation angle < 20 degrees.

3.3. Myocardial Performance Index

The MPI index was calculated for both right and left heart by PW Doppler. Three intervals were recorded for each index: Isovolumetric contraction time (ICT), isovolumetric relaxation time (IRT) and ejection time (ET). ICT is the period between mitral/tricuspid valve closure and aortic/pulmonary valve opening. IRT is the period between aortic/pulmonary valve closure and mitral/tricuspid valve opening and ET is the period between aortic/pulmonary valve opening and closure. $\text{Mod-MPI} = (\text{ICT} + \text{IRT})/\text{ET}$.

3.4. Pre-Load Index

This index was recorded during the periods of fetal apnea, when there were no breathing movements. With the observation of blood flow in IVC, the sampling volume was placed as close as possible to the heart. The best alignment of the Doppler for PLI determination could be obtained from longitudinal view of the IVC, just below the RA-IVC junction. Care must be taken not to be mistaken by the hepatic vein flows. Ductus venous flow may sometimes interfere with this investigation. Doppler flow optimization is necessary to get the best possible results. Doppler gain should be adjusted, so there will be no unnecessary noises. The Doppler envelope should fill two thirds of the imaging plane. The reverse flow (A wave) during atrial contraction, the initial forward flow (Sf wave) during atrial relaxation and ventricular contraction, second forward flow (Df wave) during ventricular diastole were observed. The preload index was defined as A/Sf (Figure 1) (15).

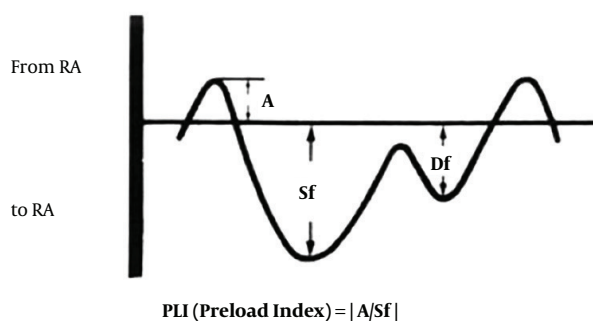


Figure 1. The blood flow pattern of the IVC for calculating the preload index ($\text{PLI} = A/Sf$)

3.5. Inter-Ventricular Septal Thickening

Using the M-mode echocardiography during the diastole, the Inter-ventricular septal thickening was measured by placing the M-line perpendicular to Inter-ventricular

septum, just below the aortic valves in transverse five-chamber view during the suspended voluntary maternal respiration with no fetal breathing movements.

3.6. Cardiac Output

Right and left side cardiac output was calculated by using the following formula:

Left side cardiac output = $0.785 \times (\text{aortic valve diameter})^2 \times \text{VTI} \times \text{HR}$

Right side cardiac output = $0.785 \times (\text{pulmonic valve diameter})^2 \times \text{VTI} \times \text{HR}$

Where VTI means velocity time integral and HR means heart rate.

3.7. Statistical Analysis

The data was analyzed with SPSS software version 22. The quantitative values were expressed with mean \pm SD and P value less than 0.05 was considered significant. The normality of the parameters distribution pattern was evaluated by Kolmogorov Smirnov test. The *t*-test was used for normally distributed ones; otherwise the Mann-Whitney test was used.

4. Results

This study was conducted on 25 cases, pregnant women with gestational, and on 50 healthy pregnant women without any history of diabetes, who came to our institution for routine check-up. All the case group had good glycemic control. Male gender of the fetuses had a greater portion in control group (67.40% vs. 65.60%) but female gender in case group (34.40% vs. 32.60%). The mean gestational age was 33 ± 5 weeks, the case group had 31 ± 8 weeks of gestation and control 31 ± 5 weeks, without any significant difference ($P = 0.994$). The left ventricular MPI and Right ventricular MPI did not differ statistically between the cases and controls ($P = 0.359$ and 0.961). Cases had a greater interventricular wall thickness in comparison to controls ($P = 0.044$). The right sided and left sided cardiac output did not differ significantly between the cases and controls ($P = 0.624$ and 0.329). The PLI value was greater in the case group (0.57 ± 0.11) compared to the control group (0.47 ± 0.11) with P value of 0.001 (Table 1, Figures 2 and 3).

5. Discussion

Cardiac function impairment in the fetuses of the diabetic mothers during the second and third trimester is well established (14). Organogenesis problems with defects in neural crest migration during the first trimester

Table 1. The Detailed Results of Measured Cardiac Indices^a

	Case Group	Control Group	P Value
Left MPI	0.43 ± 0.09	0.48 ± 0.27	0.359
Right MPI	0.45 ± 0.11	0.46 ± 0.32	0.961
Interventricular septal thickness	0.23 ± 0.07	0.20 ± 0.04	0.044
Left cardiac output	741.76 ± 391.98	612.60 ± 517.90	0.329
Right cardiac output	904.81 ± 731.72	821.92 ± 710.4	0.624
PLI	0.57 ± 0.11	0.47 ± 0.11	0.001

Abbreviations: MPI, myocardial performance index; PLI, pre-load index.
^a Values are expressed as mean \pm SD.

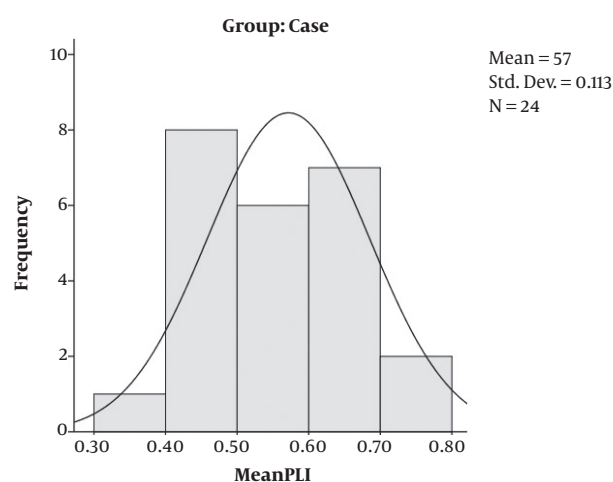


Figure 2. PLI mean distribution in the case group. PLI: pre-load Index

will lead to structural conotruncal defects (18); however, in the second and third trimester myocardial hypertrophy and myocardial dysfunction occur as a result of hyperglycemia, with a 5-time greater risk of still birth (19), moreover, the alteration in myocardial contractile protein isoforms befalls in the second trimester (20). Fetal echocardiography has emerged as a great progress for prenatal diagnosis of congenital heart disease that has made the intra-uterine treatment possible as well. Cardiac function changes in the sonographic parameters emerge even sooner than cardiac structure ultrasonic changes (21). Diastolic dysfunction is considered as the earliest change in fetal myocardium which proceeds to systolic dysfunction and finally symptomatic heart failure (21).

In 1996, a new modality named myocardial performance index has been introduced for the assessment of heart failure (22). It is a useful tool in the pediatric population for the cardiac evaluation of the patients undergoing anthracycline therapy (23), single ventricle physiology

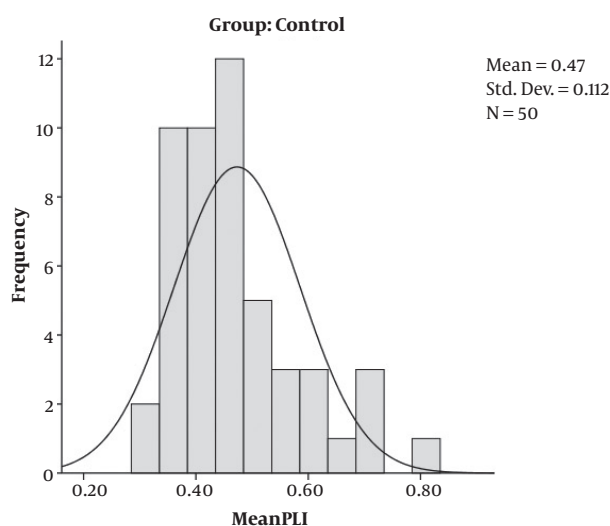


Figure 3. PLI mean distribution in the control group. PLI: pre-load Index

(24) and candidates for heart transplant (25). It has been shown that the MPI is increased in the fetuses of the diabetic mothers, independent of onset of maternal diabetes but dependent of the insulin usage (26); although the results of our study showed no difference in both right and left side MPI. According to Tsutsumi et al. (27), the fetuses of diabetics have higher level of MPI in 27 to 40 weeks of gestation, compared with controls. Similar result has been reported by Balli et al. (28), demonstrating greater left ventricular MPI in the fetuses of the women with gestational diabetes; however, Ichizuka et al. (29) have shown that this index is increased in large-for-gestational fetuses of diabetics, and not in the appropriate-for-gestation or small-for-gestation fetuses. On the other hand, according to a recent study by Pilania et al. (30), MPI at 26 - 28 weeks and cardiac output at 34 - 36 weeks of gestation can predict the adverse outcomes. Despite all the previous reports, our study did not approve any abnormalities in MPI of the fetuses of diabetic mothers. Previous studies have propounded fetal progressive cardiac output decrement through the pregnancy of diabetics (31). In our patients, the cardiac output, both in the right and left side, were similar to the healthy ones.

Having a pulsatile pattern, blood flow of inferior vena cava (IVC) is synchronized with cardiac cycle (32). IVC blood flow patterns can be detected by pulsed Doppler echocardiography in the fetuse (33). Using IVC pulsed Doppler echocardiography, the PLI index can be calculated, representing preload state of the fetus heart (15). PLI value increment is associated with several conditions such as tricuspid regurgitation or some structural heart diseases (15),

lower umbilical atrial blood pH, higher hematocrit at the time of the birth and increased risk of neonatal morbidity (34). Up to now, several indices, such as MPI and E/A ratio, have been suggested for early detection of diastolic dysfunction, as the primary sign of proceeding to heart failure. As far as we know, diastolic heart failure leads to increased cardiac preload, thus Increased PLI index, which reflects diastolic dysfunctions. In our study, in contrast to the previous studies, the MPI did not differ between the fetuses of the gestational diabetic mothers and non-diabetic ones; but, fetuses of gestational diabetic mothers had a greater value of PLI, representing early changing in diastolic function in the right heart even before the heart failure occurs. This could be a sign of vasculopathy in gestational diabetic mothers.

Footnotes

Authors' Contribution: Ehsan Aghaei Moghadam and Aliakbar Zeinaloo designed the project and came up with the idea of cardiac evaluation and the project was performed under their supervision, besides the collaboration for writing the final paper. Morteza Danaeian, Sedigheh Hantoushzadeh and Fahimeh Ghotbizadeh Vahdani collected the data. Ali Mohebbi analyzed the data. Ali Mazouri and Azin Ghamari wrote the paper.

Conflict of Interests: This study has not any conflict of interests.

Ethical Approval: The study was approved by institutional review board.

Funding/Support: This study has not been funded by any institutions.

References

1. DJIDAAtlas. *International diabetes federation*. 7th ed. Brussels, Belgium: International Diabetes Federation; 2015.
2. Starikov R, Bohrer J, Goh W, Kuwahara M, Chien EK, Lopes V, et al. Hemoglobin A1c in pregestational diabetic gravidas and the risk of congenital heart disease in the fetus. *Pediatr Cardiol*. 2013;**34**(7):1716-22. doi: [10.1007/s00246-013-0704-6](https://doi.org/10.1007/s00246-013-0704-6). [PubMed: [23619831](https://pubmed.ncbi.nlm.nih.gov/23619831/)].
3. Lale S, Yu S, Ahmed A. Complex congenital heart defects in association with maternal diabetes and partial deletion of the A2BP1 gene. *Fetal Pediatr Pathol*. 2011;**30**(3):161-6. doi: [10.3109/15513815.2010.547555](https://doi.org/10.3109/15513815.2010.547555). [PubMed: [21355681](https://pubmed.ncbi.nlm.nih.gov/21355681/)].
4. Reller MD, Kaplan S. Hypertrophic cardiomyopathy in infants of diabetic mothers: An update. *Am J Perinatol*. 1988;**5**(4):353-8. doi: [10.1055/s-2007-999722](https://doi.org/10.1055/s-2007-999722). [PubMed: [2971360](https://pubmed.ncbi.nlm.nih.gov/2971360/)].
5. Radaelli T, Varastehpour A, Catalano P, Hauguel-de Mouzon S. Gestational diabetes induces placental genes for chronic stress and inflammatory pathways. *Diabetes*. 2003;**52**(12):2951-8. doi: [10.2337/diabetes.52.12.2951](https://doi.org/10.2337/diabetes.52.12.2951). [PubMed: [14633856](https://pubmed.ncbi.nlm.nih.gov/14633856/)].
6. Tare M, Bensley JG, Moss TJ, Lingwood BE, Kim MY, Barton SK, et al. Exposure to intrauterine inflammation leads to impaired function and

- altered structure in the preterm heart of fetal sheep. *Clin Sci (Lond)*. 2014;**127**(9):559–69. doi: [10.1042/CS20140097](https://doi.org/10.1042/CS20140097). [PubMed: [24815024](https://pubmed.ncbi.nlm.nih.gov/24815024/)].
7. Maryann N. M., Craig S. S., Priya G. R., James R. S. Hypertension and diabetes mellitus. In: Black HR, Elliott WJ, editors. *Hypertension: A companion to Braunwald's heart disease*. Elsevier; 2007. p. 406–47. doi: [10.1016/B978-1-4160-3053-9.50040-8](https://doi.org/10.1016/B978-1-4160-3053-9.50040-8).
 8. Luengmettakul J, Sunsaneevithayakul P, Talungchit P. Pregnancy outcome in women with gestational diabetes mellitus according to the Carpenter-Coustan criteria in Thailand. *J Obstet Gynaecol Res*. 2015;**41**(9):1345–51. doi: [10.1111/jog.12727](https://doi.org/10.1111/jog.12727). [PubMed: [26111427](https://pubmed.ncbi.nlm.nih.gov/26111427/)].
 9. Weiner Z, Zloczower M, Lerner A, Zimmer E, Itskovitz-Eldor J. Cardiac compliance in fetuses of diabetic women. *Obstet Gynecol*. 1999;**93**(6):948–51. [PubMed: [10362160](https://pubmed.ncbi.nlm.nih.gov/10362160/)].
 10. Tei C. New non-invasive index for combined systolic and diastolic ventricular function. *J Cardiol*. 1995;**26**(2):135–6. doi: [10.1016/S0029-7844\(99\)00003-4](https://doi.org/10.1016/S0029-7844(99)00003-4). [PubMed: [7674144](https://pubmed.ncbi.nlm.nih.gov/7674144/)].
 11. Labovitz AJ, Pearson AC. Evaluation of left ventricular diastolic function: Clinical relevance and recent Doppler echocardiographic insights. *Am Heart J*. 1987;**114**(4 Pt 1):836–51. doi: [10.1016/0002-8703\(87\)90795-2](https://doi.org/10.1016/0002-8703(87)90795-2). [PubMed: [2959134](https://pubmed.ncbi.nlm.nih.gov/2959134/)].
 12. Garcia MJ, Thomas JD, Klein AL. New Doppler echocardiographic applications for the study of diastolic function. *J Am Coll Cardiol*. 1998;**32**(4):865–75. doi: [10.1016/s0735-1097\(98\)00345-3](https://doi.org/10.1016/s0735-1097(98)00345-3).
 13. Nagueh SF, Bachinski LL, Meyer D, Hill R, Zoghbi WA, Tam JW, et al. Tissue Doppler imaging consistently detects myocardial abnormalities in patients with hypertrophic cardiomyopathy and provides a novel means for an early diagnosis before and independently of hypertrophy. *Circulation*. 2001;**104**(2):128–30. doi: [10.1161/01.CIR.104.2.128](https://doi.org/10.1161/01.CIR.104.2.128). [PubMed: [11447072](https://pubmed.ncbi.nlm.nih.gov/11447072/)]. [PubMed Central: [PMC2900859](https://pubmed.ncbi.nlm.nih.gov/PMC2900859/)].
 14. Rizzo G, Arduini D, Romanini C. Cardiac function in fetuses of type I diabetic mothers. *Am J Obstet Gynecol*. 1991;**164**(3):837–43. doi: [10.1016/0002-9378\(91\)90526-W](https://doi.org/10.1016/0002-9378(91)90526-W). [PubMed: [2003550](https://pubmed.ncbi.nlm.nih.gov/2003550/)].
 15. Kanzaki T, Chiba Y. Evaluation of the preload condition of the fetus by inferior vena caval blood flow pattern. *Fetal Diagn Ther*. 1990;**5**(3-4):168–74. doi: [10.1159/000263589](https://doi.org/10.1159/000263589). [PubMed: [2130842](https://pubmed.ncbi.nlm.nih.gov/2130842/)].
 16. Alberti KG, Zimmet PZ. Definition, diagnosis and classification of diabetes mellitus and its complications. Part 1: Diagnosis and classification of diabetes mellitus provisional report of a WHO consultation. *Diabet Med*. 1998;**15**(7):539–53. doi: [10.1002/\(SICI\)1096-9136\(199807\)15:7<539::AID-DIA668>3.0.CO;2-S](https://doi.org/10.1002/(SICI)1096-9136(199807)15:7<539::AID-DIA668>3.0.CO;2-S). [PubMed: [9686693](https://pubmed.ncbi.nlm.nih.gov/9686693/)].
 17. Zielinsky P, Haertel JC, Lucchese FA. [Sequential approach to congenital heart diseases: a two-dimensional echocardiographic approach]. *Arq Bras Cardiol*. 1985;**45**(2):129–44. Portuguese. [PubMed: [3915197](https://pubmed.ncbi.nlm.nih.gov/3915197/)].
 18. Morgan SC, Relaix F, Sandell LL, Loeken MR. Oxidative stress during diabetic pregnancy disrupts cardiac neural crest migration and causes outflow tract defects. *Birth Defects Res A Clin Mol Teratol*. 2008;**82**(6):453–63. doi: [10.1002/bdra.20457](https://doi.org/10.1002/bdra.20457). [PubMed: [18435457](https://pubmed.ncbi.nlm.nih.gov/18435457/)]. [PubMed Central: [PMC5452612](https://pubmed.ncbi.nlm.nih.gov/PMC5452612/)].
 19. Casson IF, Clarke CA, Howard CV, McKendrick O, Pennycook S, Pharoah PO, et al. Outcomes of pregnancy in insulin dependent diabetic women: Results of a five year population cohort study. *BMJ*. 1997;**315**(7103):275–8. doi: [10.1136/bmj.315.7103.275](https://doi.org/10.1136/bmj.315.7103.275). [PubMed: [9274545](https://pubmed.ncbi.nlm.nih.gov/9274545/)]. [PubMed Central: [PMC2127202](https://pubmed.ncbi.nlm.nih.gov/PMC2127202/)].
 20. Baschat AA. Development of the fetal cardiac and extracardiac Doppler flows in early gestation. In: Yagel S, Silverman NH, Gembruch U, editors. *Fetal Cardiology*. London, UK: Martin Dunitz, Taylor and Francis Group; 2003. p. 121–39.
 21. Russell NE, Foley M, Kinsley BT, Firth RG, Coffey M, McAuliffe FM. Effect of pregestational diabetes mellitus on fetal cardiac function and structure. *Am J Obstet Gynecol*. 2008;**199**(3):312 e1–7. doi: [10.1016/j.ajog.2008.07.016](https://doi.org/10.1016/j.ajog.2008.07.016). [PubMed: [18771996](https://pubmed.ncbi.nlm.nih.gov/18771996/)].
 22. Tei C, Dujardin KS, Hodge DO, Kyle RA, Tajik AJ, Seward JB. Doppler index combining systolic and diastolic myocardial performance: clinical value in cardiac amyloidosis. *J Am Coll Cardiol*. 1996;**28**(3):658–64. doi: [10.1016/0735-1097\(96\)00202-1](https://doi.org/10.1016/0735-1097(96)00202-1). [PubMed: [8772753](https://pubmed.ncbi.nlm.nih.gov/8772753/)].
 23. Mahdavi C, Zeinaloo AA, Ghamari A, Aghaei Moghadam E, Kocharian A, Mirzaaghaian MR, et al. Anthracycline-induced cardiotoxicity in children cancer patients: An imaging study by two-dimensional global longitudinal strain using automated function imaging technique. *J Compr Pediatr*. 2018;**In Press**(In Press). doi: [10.5812/com-preped.59701](https://doi.org/10.5812/com-preped.59701).
 24. Williams RV, Ritter S, Tani LY, Pagoto LT, Minich LL. Quantitative assessment of ventricular function in children with single ventricles using the Doppler myocardial performance index. *Am J Cardiol*. 2000;**86**(10):1106–10. doi: [10.1016/S0002-9149\(00\)01168-1](https://doi.org/10.1016/S0002-9149(00)01168-1). [PubMed: [11074208](https://pubmed.ncbi.nlm.nih.gov/11074208/)].
 25. Mooradian SJ, Goldberg CS, Crowley DC, Ludomirsky A. Evaluation of a noninvasive index of global ventricular function to predict rejection after pediatric cardiac transplantation. *Am J Cardiol*. 2000;**86**(3):358–60. doi: [10.1016/S0002-9149\(00\)00935-8](https://doi.org/10.1016/S0002-9149(00)00935-8). [PubMed: [10922454](https://pubmed.ncbi.nlm.nih.gov/10922454/)].
 26. Figueroa H, Silva MC, Kottmann C, Viguera S, Valenzuela I, Hernandez-Andrade E, et al. Fetal evaluation of the modified-myocardial performance index in pregnancies complicated by diabetes. *Prenat Diagn*. 2012;**32**(10):943–8. doi: [10.1002/pd.3937](https://doi.org/10.1002/pd.3937). [PubMed: [22825924](https://pubmed.ncbi.nlm.nih.gov/22825924/)].
 27. Tsutsumi T, Ishii M, Eto G, Hota M, Kato H. Serial evaluation for myocardial performance in fetuses and neonates using a new Doppler index. *Pediatr Int*. 1999;**41**(6):722–7. [PubMed: [10618901](https://pubmed.ncbi.nlm.nih.gov/10618901/)].
 28. Balli S, Pac FA, Ece I, Oflaz MB, Kibar AE, Kandemir O. Assessment of cardiac functions in fetuses of gestational diabetic mothers. *Pediatr Cardiol*. 2014;**35**(1):30–7. doi: [10.1007/s00246-013-0734-0](https://doi.org/10.1007/s00246-013-0734-0). [PubMed: [23780554](https://pubmed.ncbi.nlm.nih.gov/23780554/)].
 29. Ichizuka K, Matsuoka R, Hasegawa J, Shirato N, Jimbo M, Otsuki K, et al. The Tei index for evaluation of fetal myocardial performance in sick fetuses. *Early Hum Dev*. 2005;**81**(3):273–9. doi: [10.1016/j.earlhumdev.2004.07.003](https://doi.org/10.1016/j.earlhumdev.2004.07.003). [PubMed: [15814209](https://pubmed.ncbi.nlm.nih.gov/15814209/)].
 30. Pilaian R, Sikka P, Rohit MK, Suri V, Kumar P. Fetal cardiodynamics by echocardiography in insulin dependent maternal diabetes and its correlation with pregnancy outcome. *J Clin Diagn Res*. 2016;**10**(7):QC01–4. doi: [10.7860/JCDR/2016/17993.8079](https://doi.org/10.7860/JCDR/2016/17993.8079). [PubMed: [27630907](https://pubmed.ncbi.nlm.nih.gov/27630907/)]. [PubMed Central: [PMC5020204](https://pubmed.ncbi.nlm.nih.gov/PMC5020204/)].
 31. Lisowski LA, Verheijen PM, De Smedt MM, Visser GH, Meijboom EJ. Altered fetal circulation in type-1 diabetic pregnancies. *Ultrasound Obstet Gynecol*. 2003;**21**(4):365–9. doi: [10.1002/uog.88](https://doi.org/10.1002/uog.88). [PubMed: [12704745](https://pubmed.ncbi.nlm.nih.gov/12704745/)].
 32. Reuss ML, Rudolph AM, Dae MW. Phasic blood flow patterns in the superior and inferior venae cavae and umbilical vein of fetal sheep. *Am J Obstet Gynecol*. 1983;**145**(1):70–8. doi: [10.1016/0002-9378\(83\)90342-3](https://doi.org/10.1016/0002-9378(83)90342-3). [PubMed: [6849346](https://pubmed.ncbi.nlm.nih.gov/6849346/)].
 33. Chiba Y, Utsu M, Kanzaki T, Hasegawa T. Changes in venous flow and intra tracheal flow in fetal breathing movements. *Ultrasound Med Biol*. 1985;**11**(1):43–9. doi: [10.1016/0301-5629\(85\)90006-7](https://doi.org/10.1016/0301-5629(85)90006-7). [PubMed: [3892816](https://pubmed.ncbi.nlm.nih.gov/3892816/)].
 34. Nicolaides KHRG, Hecher K. *Placental and fetal Doppler*. London: The Parthenon Publishing Group; 2000. doi: [10.1201/b14685](https://doi.org/10.1201/b14685).