



# Intraoperative Nursing Cooperation in Endoscopy-Assisted Surgery of Pyriform Sinus Fistula in Chinese Children: Experience in 196 Cases

Zhen Wang<sup>1</sup>, Zhibao Lv<sup>2</sup>, Qunfeng Lu<sup>3</sup>, Qingfeng Sheng<sup>2</sup>, Yan Li<sup>1</sup> and Xia Yang<sup>1,\*</sup>

<sup>1</sup>OR, Shanghai Children's Hospital, Shanghai, China

<sup>2</sup>General Surgery Department, Shanghai Children's Hospital, China

<sup>3</sup>Nursing Department, Shanghai Children's Hospital, China

\*Corresponding author: OR, Shanghai Children's Hospital, Shanghai, China. Email: yangxia@shchildren.com.cn

Received 2019 January 07; Revised 2019 March 04; Accepted 2019 March 20.

## Abstract

**Objectives:** To summarize the experience of intraoperative nursing cooperation in endoscopy-assisted surgery of pyriform sinus fistula (PSF) in children.

**Methods:** The charts of 196 children diagnosed with PSF undergone endoscopy-assisted surgery during August 2010 to August 2018 were retrospectively analyzed and in particular, the nursing cooperation reviewed.

**Results:** All 196 cases were treated with endoscopy-assisted surgery following induction of general anesthesia with endotracheal intubation. Fistula tract was successfully found and completely resected. Good outcome was achieved in all but five patients during a follow-up of 2 months to 8 years. One patient had temporary hoarseness after surgery and recovered after 3 months. One patient developed left-side Horner's syndrome. PSF recurred in 3 cases.

**Conclusions:** Endoscopy-assisted surgery for PSF consists of two parts: endoscopy assistance and open-neck operation resection. As a combined surgery, there are integral parts for operating room nurses to make full preparation, understand the surgical method, master the surgical procedures and special requirements, strengthen the cooperation and collaboration closely with surgical personnel to ensure successful operation.

**Keywords:** Pyriform Sinus Fistula, Children, Endoscopy, Nursing Cooperation

## 1. Background

Congenital pyriform sinus fistula (CPSF) is a relatively rare cervical branchial malformation originating from incomplete occlusion of the third or fourth pharyngeal pouch during pregnancy (1, 2). The main clinical manifestations are recurrent acute suppurative thyroiditis or repeated left neck infection (3-5). Radical resection of fistula after resolution of inflammation is the key to avoid recurrence. However, it is difficult to find the fistula in traditional open-neck surgery, or the resection is incomplete, which may lead to recurrence (1, 6). In recent years, minimally invasive endoscopic occlusion of the internal opening for the treatment of PSF is performed, including biocauterization (7), electrocautery (8), chemocautery (9), coblation (10), laser cauterization (11), and suture closure (6), etc. But only a few cases are reported with high recurrence rate. Some endoscopic minimally invasive treatments were controversial (12, 13). Between August 2010 and August 2018, 196 children with PSF treated with endoscopy-assisted surgery under the guidance of a surgical specialist (Z.L.) at Children's Hospital of Shanghai Jiao Tong Uni-

versity were included in the study. The fistula could be accurately found by endoscopy in all cases, the fistula sinus tract was completely resected through open-neck surgery, and good outcome was achieved.

## 2. Methods

Retrospective analysis was performed on 196 children diagnosed with PSF in Children's Hospital of Shanghai from August 2010 to August 2018. Data were collected by the surgical anesthesia information system, including gender, age, diagnosis, and site of operation. Postoperative data were collected from doctors' follow-up records and outpatient visits. Ethical approval was obtained from the Ethics Board of the Children's Hospital of Shanghai Jiao Tong University.

## 3. Results

The study was composed of 106 males and 90 females (M/F ratio 1.18:1). The median age at surgery was 6 years

(range, 6 months to 17 years). 183 (93.37%) cases were located at left side, 10 (5.10%) cases at right side and 3 (1.53%) cases were bilateral (Table 1). All the children underwent endoscopy-assisted surgery following induction of general anesthesia with endotracheal intubation. Fistula tract was successfully found and completely resected through open-neck surgery. Good outcome was achieved in all but 5 cases (2.55%) with complications occurred during a follow-up of 2 months to 8 years. One patient had temporary hoarseness after surgery and recovered after 3 months. One patient developed left-side ptosis and miosis (Horner's syndrome). PSF recurred in 3 cases.

**Table 1.** Summary of 196 Children with PSF

Characteristic	No. (%)
<b>Sex</b>	
Male	106 (54.08)
Female	90 (45.92)
<b>Side of anomaly</b>	
Left	183 (93.37)
Right	10 (5.10)
Bilateral	3 (1.53)
<b>Age, y</b>	
≤ 6	109 (55.61)
> 6	87 (44.39)
<b>Outcome</b>	
Temporary hoarseness	1 (0.51)
Horner syndrome	1 (0.51)
Recurrence	3 (1.53)

## 4. Discussion

### 4.1. Preoperative Visit and Assessment

The children and their parents were nervous and anxious before surgery because of repeated treatment due to recurrent neck redness or abscess. Preoperative visit should be made to introduce disease related knowledge, operating room environment, surgical methods, etc., so children and parents can actively respond to surgery. Operating room nurses should make adequate preoperative assessment to check the patient's basic information (age, height, weight), surgical site and skin, as well as preoperative items preparation and use of prophylactic antibiotics. It is also important to observe whether the mouth is damaged or the teeth are loose according to the operation requirements. In recent years, we have completed a certain number of endoscopy-assisted operations with surgical nursing cooperation. A workflow was developed to

help surgical nursing staff get familiar with preoperative preparation and surgical procedures (Figure 1).

### 4.2. Preparation of Instruments and Items

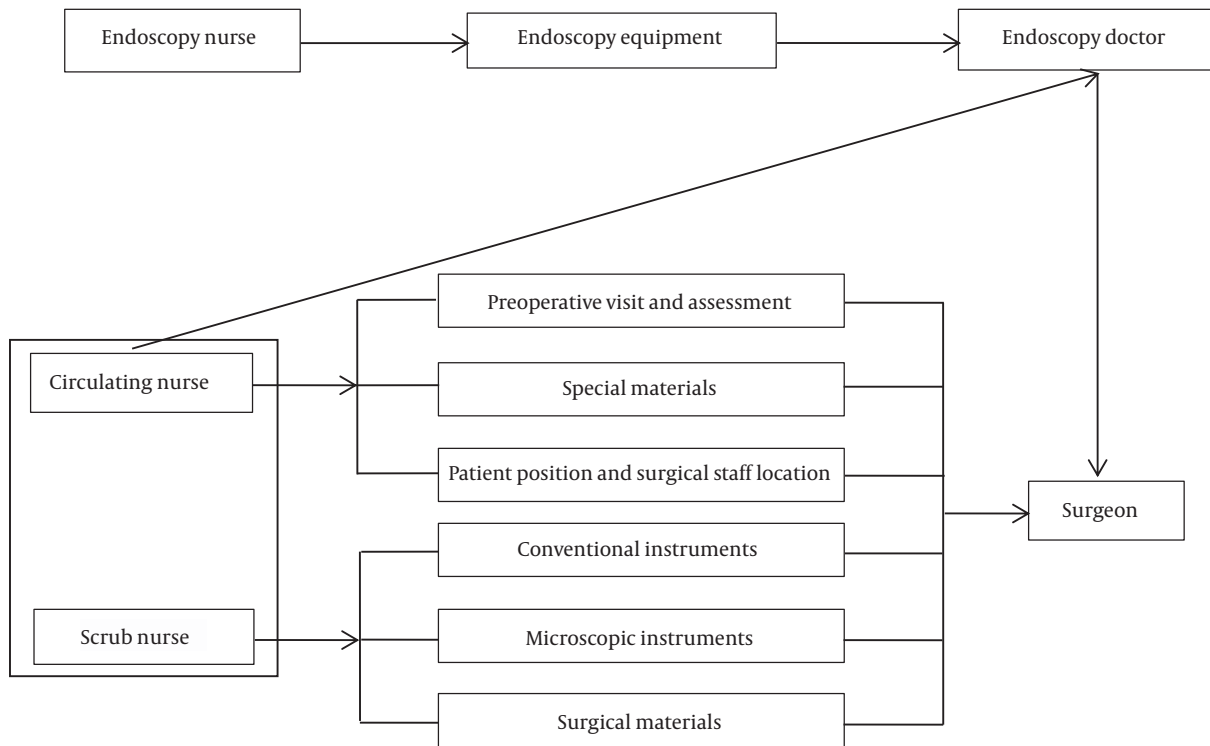
Conventional surgical instruments kit, microsurgical instruments, VICRYL sutures (3/0, 4/0, 5/0), endoscopy operation system (Olympus, type GIF-160), positioning catheter (Star Tip cannula, type PR-110Q-1, not sterilization), 2% glutaraldehyde, endoscopy bite, methylene blue (2mL per bottle), 5mL disposable syringes, paraffin oil, eye film, etc. The catheter was soaked with 2% glutaraldehyde before operation (Figure 2B) to achieve sterilization effect (14). The catheter, especially its cavity was rinsed repeatedly with sterilized water before use. Keep sterile throughout the procedures to prevent pollution of the catheter.

### 4.3. Intraoperative Patient Position and Surgical Staff Location

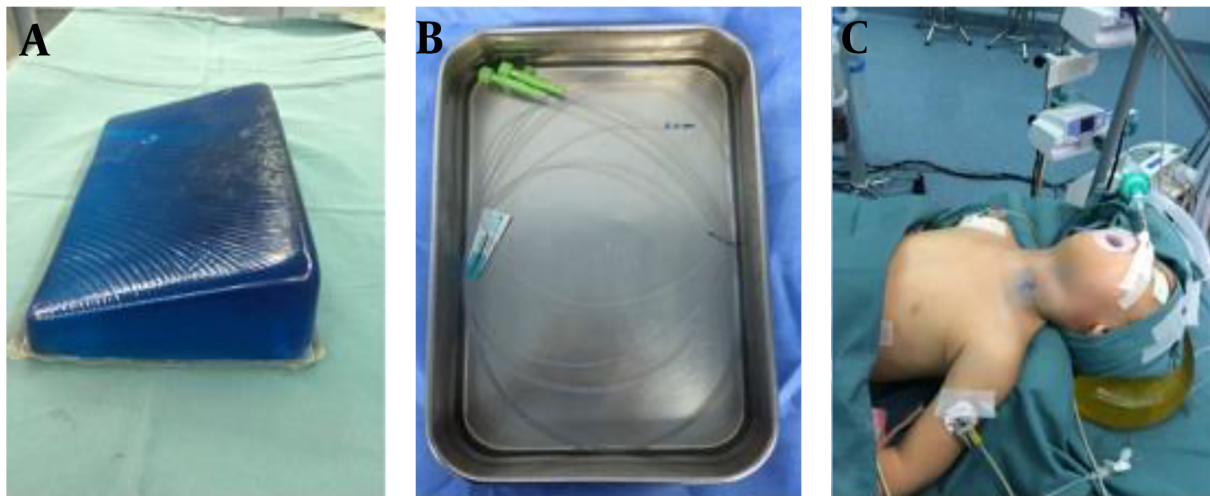
The children were placed in a supine position on the operating bed following induction of general anesthesia with nasal endotracheal intubation. Using soft pads to raise the shoulder with the neck hyperextended to fully expose the surgical field (Figure 2C) (1, 2, 15). Appropriate position pads (Figure 2A) were selected according to the body shape of the child and silicone head ring was used to fix the head to prevent displacement during the operation. Two disposable eye patches protected the eyes to prevent damage caused by methylene blue dropped into while injecting. Fix the endotracheal intubation correctly to prevent slipping. In the whole process, attention must be paid to protect the neck and limbs to maintain normal function. Due to the use of nasal intubation and frequent operation of endoscope, special attention should be paid to the protection of the eyes and facial skin. Close coordination and cooperation was required because of different divisions of labor during the operation. We designed a surgical staff location map according to the operation requirements (Figure 3) to allocate the operation area reasonably and to avoid the confusion of space and location.

### 4.4. Operation Cooperation

The scrub nurse cooperated with the surgeon accurately and quickly to perform the following operations: a 3-4 cm transverse elliptical neck incision was made at the level of the cricoid cartilage, with a previous infection and incision scar used whenever possible. The upper and lower margins of the flaps were sutured to the sides of the incision with the suture triangle needle to fully expose the surgical area. Divided tissue and the platysma flap, incised the linea alba cervicalis, and then the sternocleidomastoid muscle and anterior cervical strap muscles were contoured and retracted laterally. After ligation and cut of the



**Figure 1.** Surgical nursing cooperation workflow



**Figure 2.** Preparation of instruments and intraoperative patient position. A, position pads; B, the catheter was soaked with 2% glutaraldehyde before operation; C, intraoperative patient position.

superior thyroid artery and vein with 5-0 absorbable sutures, the upper pole of the thyroid lobe was retracted laterally to show the surfaces of cricothyroid muscle. The fistula tract was carefully explored when dissecting the scar

tissue anterior and inferior to the inferior cornu of the thyroid cartilage. Instruments were prepared meticulously and operated carefully during the dissection to protect vital tissues and structures especially the recurrent laryn-

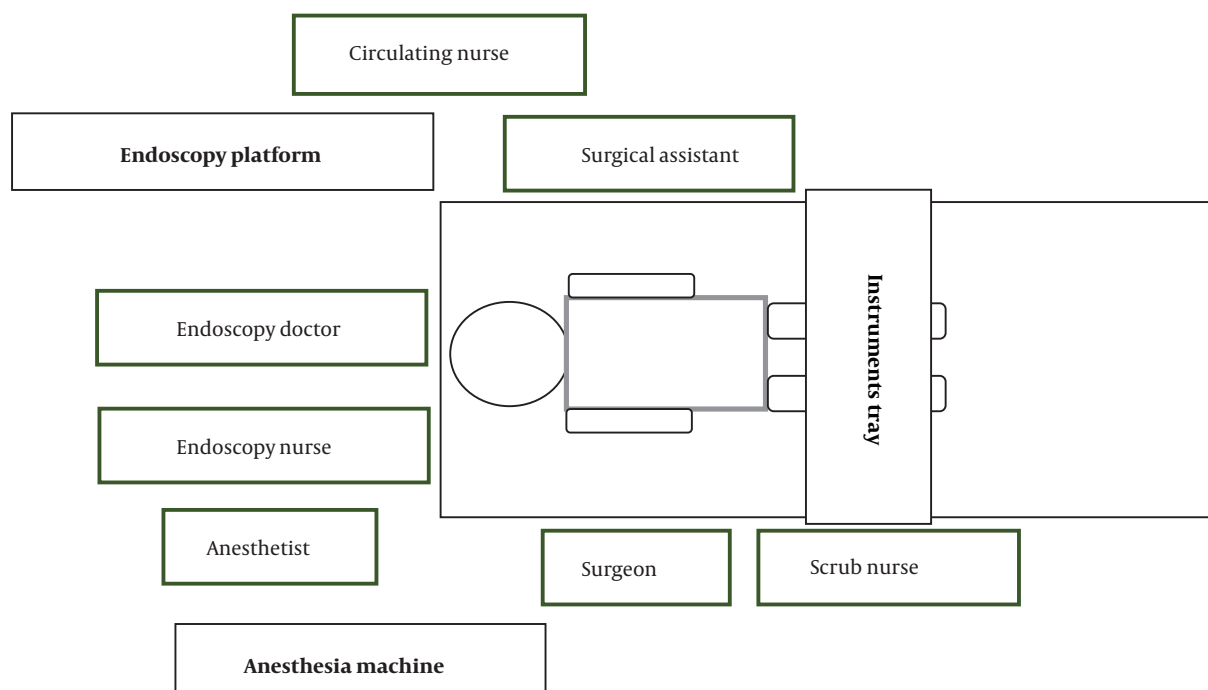


Figure 3. Surgical staff location map

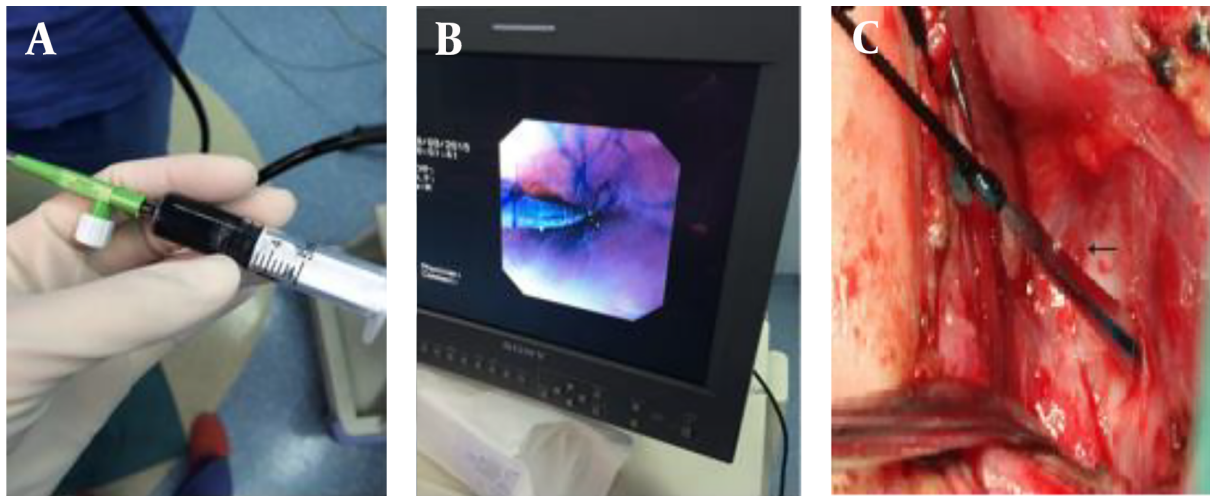
geal nerve (1, 2). Finding fistula is challenging due to its complex anatomical course, especially in patients with repeated infection or drainage and inadequate management with fistula and surrounding tissue erosion and necrosis or dense adhesion. Then, endoscopy can be applied.

#### 4.5. Endoscopy Collaboration

The endoscope was inserted by the endoscopy doctor with assistance of an endoscopy nurse to search for the internal opening of the pyriform fossa. Light can be applied as an indicator with its transillumination identified in operative incision (1, 2). The circulating nurse should turn off the astral lamp temporarily to help the surgeon distinguish the transillumination light. After finding the tract, the endoscope was fixed to avoid displacement. Sterilized catheter was inserted by endoscopy doctor and circulating nurse. The endoscopy doctor gently pushed the catheter as instructed by the surgeon if it was inserted into the tract. The surgeon continued to search for and separate the fistula tract guided by the catheter with surgical incision. The catheter needs to be gently pressed against the inner opening of the tract if it fails to enter the distant fistula, then 1:1 diluted methylene blue is injected (Figure 4A) by the circulating nurse with gentle and moderate pressure which can be judged by the moving speed of methylene blue in the catheter. If the resistance is large, it means that the tip of catheter is close to the inner opening wall. At this

time, circulating nurse should stop injecting and inform endoscopy doctor to return the catheter to avoid the fistula rupture due to excessive pressure. The total capacity of a catheter was 2.4 mL. Methylene blue was seen on the endoscope screen (Figure 4B) after injection of 2.4 mL and another 0.5 mL can be injected repeatedly. The fistula tract was further separated along the blue stain until reached near the base of the pyriform fossa, then was ligated and resected with or without its adjacent tissues (e.g., part of the thyroid, muscle, scar tissue) with two 3-0 non-absorbable sutures (Figure 4C). The incision is closed in layers with absorbable sutures after irrigated with diluted Anerdian and saline. A drain leather is placed. After the operation, methylene blue was carefully sucked out the mouth and nasal cavity.

It is worth noting that complete resection of fistula tract by endoscopy-assisted surgery requires surgeons to master the anatomical features of PSF to avoid iatrogenic injury (1-4, 16). On the other hand, it is equally important to find fistula or staining of fistula under endoscopy. Nurses should prepare for endoscopy assistance while cooperating closely with surgeons. Since there was no dedicated catheter, we chose ERCP angiographic catheter (Type PR-110Q-1) for injection of methylene blue based on the following: the length and diameter of the catheter is appropriate to be inserted into the inner opening of the pyriform fossa; the tip of the catheter is round and smooth which



**Figure 4.** Operative view. A, the catheter is connected to a disposable syringe of diluted methylene blue. B, catheter is inserted into the tract and the diluted methylene blue is injected. C, clear identification of the fistula tract is shown after intraoperative endoscopy-assisted methylene blue injection.

can prevent the tract from puncturing; the hardness of the catheter is appropriate for the endoscopy doctor to push repeatedly without bending.

At present, complete resection of fistula is still the most common and thorough treatment for PSF (1, 2, 6, 15, 16). However, in a review of 177 published reports on PSF, 377 patients who underwent open surgery, 15% recurrence occurred after initial surgery, the same as under endoscopic cauterization. In addition, complications after surgery occurred primarily in children 8 years or younger with a rate of 10% (3). Therefore, it is very important to select the appropriate technology to completely resect the fistula tract. Endoscopy-assisted technique is simple to operate and easy to master. Combined with open surgery, fistula tract can be accurately found and completely resected (1, 2, 16). As a combined method, endoscopy-assisted surgery for PSF is currently reported in Children's Hospital of Shanghai Tiao Tong University and Children's Hospital of Fudan University. There are no standardized procedures for surgical nursing cooperation. In order to better cooperate with surgery, we have summarized the cooperation procedures in recent years. The nurses should carefully conduct preoperative visit and assessment, fully understand the surgical methods, master the procedures and special requirements, and closely cooperate with surgical personnel to ensure successful operation.

#### Footnotes

**Authors' Contribution:** Xia Yang conceived this study, Zhen Wang and Qunfeng Lu drafted the article, Zhibao Lv finished the surgery, Qingfeng Sheng and Yan Li collected the data. All authors have read and approved this article.

**Conflict of Interests:** It is not declared by the authors.

**Ethical Approval:** Ethical approval was obtained from the Ethics Board of the Children's Hospital of Shanghai Jiao Tong University.

**Funding/Support:** Outstanding Young Talents Program of Shanghai Nursing Association was supported this study.

**Patient Consent:** It is not declared by the authors.

#### References

- Xiao X, Zheng S, Zheng J, Zhu L, Dong K, Shen C, et al. Endoscopic-assisted surgery for pyriform sinus fistula in children: Experience of 165 cases from a single institution. *J Pediatr Surg.* 2014;**49**(4):618-21. doi: [10.1016/j.jpedsurg.2013.11.004](https://doi.org/10.1016/j.jpedsurg.2013.11.004). [PubMed: [24726124](https://pubmed.ncbi.nlm.nih.gov/24726124/)].
- Sheng Q, Lv Z, Xiao X, Xu W, Liu J, Wu Y. Endoscopic-assisted surgery for pyriform sinus fistula in Chinese children: A 73-consecutive-case study. *J Laparoendosc Adv Surg Tech A.* 2016;**26**(1):70-4. doi: [10.1089/lap.2015.0129](https://doi.org/10.1089/lap.2015.0129). [PubMed: [26485644](https://pubmed.ncbi.nlm.nih.gov/26485644/)].
- Nicoucar K, Giger R, Pope HG Jr, Jaecklin T, Dulguerov P. Management of congenital fourth branchial arch anomalies: A review and analysis of published cases. *J Pediatr Surg.* 2009;**44**(7):1432-9. doi: [10.1016/j.jpedsurg.2008.12.001](https://doi.org/10.1016/j.jpedsurg.2008.12.001). [PubMed: [19573674](https://pubmed.ncbi.nlm.nih.gov/19573674/)].
- Nicoucar K, Giger R, Jaecklin T, Pope HG Jr, Dulguerov P. Management of congenital third branchial arch anomalies: A systematic review. *Otolaryngol Head Neck Surg.* 2010;**142**(1):21-28 e2. doi: [10.1016/j.otohns.2009.09.001](https://doi.org/10.1016/j.otohns.2009.09.001). [PubMed: [20096218](https://pubmed.ncbi.nlm.nih.gov/20096218/)].
- Leboulanger N, Ruellan K, Nevoux J, Pezzettigotta S, Denoyelle F, Roger G, et al. Neonatal vs delayed-onset fourth branchial pouch anomalies: Therapeutic implications. *Arch Otolaryngol Head Neck Surg.* 2010;**136**(9):885-90. doi: [10.1001/archoto.2010.148](https://doi.org/10.1001/archoto.2010.148). [PubMed: [20855681](https://pubmed.ncbi.nlm.nih.gov/20855681/)].
- Nomura A, Fukumoto K, Yamoto M, Takahashi T, Nakaya K, Sekioka A, et al. Microlaryngoscopic surgery for pyriform sinus fistulas in children: A report of two cases. *Surg Case Rep.* 2018;**4**(1):113. doi: [10.1186/s40792-018-0521-5](https://doi.org/10.1186/s40792-018-0521-5). [PubMed: [30203269](https://pubmed.ncbi.nlm.nih.gov/30203269/)]. [PubMed Central: [PMC6131676](https://pubmed.ncbi.nlm.nih.gov/PMC6131676/)].

7. Di Nardo G, Valentini V, Angeletti D, Frediani S, Iannella G, Cozzi D, et al. Recurrent pyriform sinus fistula successfully treated by endoscopic Glubran 2 sealing: A rare case and literature review. *SAGE Open Med Case Rep.* 2016;**4**:2050313X16672151. doi: [10.1177/2050313X16672151](https://doi.org/10.1177/2050313X16672151). [PubMed: [27781098](https://pubmed.ncbi.nlm.nih.gov/27781098/)]. [PubMed Central: [PMC5066581](https://pubmed.ncbi.nlm.nih.gov/PMC5066581/)].
8. Ishinaga H, Kobayashi M, Qtsu K, Nishida K, Sakaida H, Kitano M, et al. Endoscopic electrocauterization of pyriform sinus fistula. *Eur Arch Otorhinolaryngol.* 2017;**274**(11):3927-31. doi: [10.1007/s00405-017-4713-6](https://doi.org/10.1007/s00405-017-4713-6). [PubMed: [28836049](https://pubmed.ncbi.nlm.nih.gov/28836049/)].
9. Yanagisawa S, Oshio T, Kato M, Kano M, Tsuji Y, Morikawa Y. Endoscopic chemocauterization for pyriform sinus fistula in children. *Pediatr Int.* 2017;**59**(7):807-11. doi: [10.1111/ped.13294](https://doi.org/10.1111/ped.13294). [PubMed: [28387991](https://pubmed.ncbi.nlm.nih.gov/28387991/)].
10. Wang L, Sang J, Zhang Y, Wang L, Gong W, Cao H. Evaluation of endoscopic coblation treatment for obliteration of congenital pyriform sinus fistula. *Acta Otolaryngol.* 2018;**138**(6):574-8. doi: [10.1080/00016489.2017.1420916](https://doi.org/10.1080/00016489.2017.1420916). [PubMed: [29310505](https://pubmed.ncbi.nlm.nih.gov/29310505/)].
11. Wang S, He Y, Zhang Y, Zhang J, Shah R, Feng G, et al. CO2 laser cauterization approach to congenital pyriform sinus fistula. *J Pediatr Surg.* 2018;**53**(7):1313-7. doi: [10.1016/j.jpedsurg.2017.06.020](https://doi.org/10.1016/j.jpedsurg.2017.06.020). [PubMed: [28689887](https://pubmed.ncbi.nlm.nih.gov/28689887/)].
12. Han Q, Li K, Xiao X, Zheng S. Endoscopic management for congenital pyriform sinus fistula. *Int J Pediatr Otorhinolaryngol.* 2018;**104**:228-9. doi: [10.1016/j.ijporl.2017.09.002](https://doi.org/10.1016/j.ijporl.2017.09.002). [PubMed: [28919406](https://pubmed.ncbi.nlm.nih.gov/28919406/)].
13. Huang YC, Hsu WC. Letter to the editor: Response to "KTP laser endoscopic tissue fibrin glue biocauterization for congenital pyriform sinus fistula in children". *Int J Pediatr Otorhinolaryngol.* 2018;**104**:230-1. doi: [10.1016/j.ijporl.2017.09.003](https://doi.org/10.1016/j.ijporl.2017.09.003). [PubMed: [28935275](https://pubmed.ncbi.nlm.nih.gov/28935275/)].
14. Rutala WA, Weber DJ. *Healthcare Infection Control Practices Advisory Committee (HICPAC). Guideline for disinfection and sterilization in healthcare facilities.* Centers for Disease Control and Prevention; 2008.
15. Zhu H, Xiao X, Zheng S, Shen C. Diagnosis and management of pyriform sinus cyst in neonates: 16-year experience at a single center. *J Pediatr Surg.* 2017;**52**(12):1989-93. doi: [10.1016/j.jpedsurg.2017.08.041](https://doi.org/10.1016/j.jpedsurg.2017.08.041). [PubMed: [28987714](https://pubmed.ncbi.nlm.nih.gov/28987714/)].
16. Sheng Q, Lv Z, Xiao X, Zheng S, Huang Y, Huang X, et al. Diagnosis and management of pyriform sinus fistula: Experience in 48 cases. *J Pediatr Surg.* 2014;**49**(3):455-9. doi: [10.1016/j.jpedsurg.2013.07.008](https://doi.org/10.1016/j.jpedsurg.2013.07.008). [PubMed: [24650477](https://pubmed.ncbi.nlm.nih.gov/24650477/)].