

## **Protective Effect of Caffeic Acid Phenethyl Ester (CAPE) on Amiodarone-Induced Pulmonary Fibrosis in Rat**

Narjes Zaeemzadeh<sup>a</sup>, Aliasghar Hemmati<sup>a\*</sup>, Ardeshir Arzi<sup>a</sup>,  
Mohammadtaha Jalali<sup>b</sup> and Iran Rashidi<sup>c</sup>

<sup>a</sup>Department of Pharmacology and Toxicology, School of Pharmacy. <sup>b</sup>Department of Laboratory Sciences, School of Paramedics, <sup>c</sup>Department of Pathology, School of Medicine, Ahwaz Jundishapur University of Medical Sciences, Ahwaz, Iran.

---

### **Abstract**

Treatment with amiodarone, a commonly prescribed antidysrhythmic agent, is associated with pulmonary fibrosis (PF) which is a commonly progressive and untreatable disease. Caffeic acid phenethyl ester (CAPE) is a phenolic antioxidant and an active anti-inflammatory, anticancer, antimicrobial and antioxidant component of propolis (bee glue; a resinous hive product collected by honey bees). In the current study, the effects of CAPE on amiodarone-induced pulmonary fibrosis in rat were investigated.

Male rats were divided into 4 groups. The first group only received amiodarone (6.25 mg/Kg) on first and third day. The second group received only vehicle (distilled water) with the same volume and in the same time as the first group. The third and fourth groups received amiodarone and were treated with CAPE, 5 and 10  $\mu\text{mol/day}$  respectively, from 2 days before the first dose of amiodarone and until 21 days after the second dose of amiodarone. At the end of treatment course, lung tissue was removed for histopathology and biochemical evaluations. Malondialdehyde (MDA) concentration, myeloperoxidase (MPO) and superoxide dismutase (SOD) activities were determined in lung tissue. Histopathological evaluation was performed using light microscopy. MDA level and the activity of myeloperoxidase and superoxide dismutase enzymes significantly decreased in the group which was treated with CAPE (5  $\mu\text{mol/Kg}$ ). However, 10  $\mu\text{mol/Kg}$  CAPE had not such an effect. Both doses of CAPE could histopathologically reduce the fibrogenic effects of amiodarone. CAPE was shown to be effective in reducing amiodarone-induced pulmonary fibrosis with the dose of 5  $\mu\text{mol/Kg}$ .

**Keywords:** Pulmonary fibrosis; Amiodarone; Caffeic acid phenethyl ester; Rat.

---

### **Introduction**

Pulmonary fibrosis (PF) is a progressive and essentially untreatable disease with a fatal outcome, which is characterized by an altered cellular composition of the alveolar region with excessive deposition of collagen. Typical

features in this disease include dyspnea, diffuse interstitial infiltrates and poor prognosis. There are five million people worldwide that are affected by this disease. In the United States there are over 200,000 patients with pulmonary fibrosis. As a consequence of misdiagnosis, the actual number may be significantly higher. More than 40,000 of these patients expire annually. This is the same as the people who die from breast cancer. The pathogenesis of pulmonary fibrosis

---

\* Corresponding author:

E-mail: hemmati\_aa@yahoo.com

remains incompletely understood, but lung inflammation is a major underlying component of a wide variety of pulmonary fibroproliferative disorders (1-3).

It has been suggested in the last decades that the main responsible agent in PF is reactive oxygen species (ROS) such as superoxide, hydrogen peroxide, peroxynitrites and hydroxyl radicals, which are generated also in normal physiological conditions in the human body. These ROS are capable of initiating and promoting oxidative damage in the form of lipid per oxidation (LPO). The antioxidant serves as a defensive factor against free radicals in the body. Enzymes such as superoxide dismutase, catalase and glutathione peroxidase are the main system that opposes oxidation and act as a protective mechanism. If the free radicals production becomes more than the capacity of enzymatic system, the second line of defense (vitamins) may come to action. Antioxidant such as vitamins C and E quench free radicals and become oxidized and inactive (3-5).

Treatment with amiodarone (AM), commonly prescribed as an antiarrhythmic agent, may decrease the incidence of mortality following myocardial infarction or due to out-of-hospital sudden cardiac arrest. However amiodarone administration is associated with few adverse effects including pulmonary injury resulting in fatal pulmonary fibrosis. The mechanisms for amiodarone pulmonary injury include direct toxicity to lung tissue, hypersensitivity reaction to amiodarone, and enhanced oxidative stress. Alteration of membrane properties and activation of alveolar macrophages and cytokine release are the other proposed mechanisms of amiodarone toxicity (6, 7).

Propolis or bee glue is a resinous hive product collected by honey bees from plant exudates (especially conifer buds) and contains more than 160 constituents. It is used to repair hive cracks by bees. Historically it has been used for various purposes, especially as a medicine and has been used empirically as a traditional remedy in folk medicine for centuries. Recently, propolis has been extensively marketed by the pharmaceutical industries as an alternative medicine and as the health-food in various parts of the world. Propolis has been claimed to improve the health and prevent diseases such as diabetes, heart

diseases, and even cancer. Flavonoids are thought to be responsible for many of its biological and pharmacological activities including anticancer, anti-inflammatory, antimicrobial and antioxidant effects (7-9). Several investigations on propolis in Eastern Europe and South America have indicated that flavonoids concentrated in propolis are powerful antioxidants which are capable to scavenge free radicals (10).

Caffeic acid phenethyl ester (CAPE) is a phenolic antioxidant and is an active anti-inflammatory component of propolis. CAPE was shown to exert its antioxidant activity by suppressing lipid peroxidation, scavenging the reactive oxygen species, and inhibiting xanthine oxidase and nitric oxide synthase activities. It may reduce the activity of superoxide dismutase (11). It was also found to inhibit 5-lipoxygenase catalysed oxygenation of linoleic acid and arachidonic acid in micromolar (10  $\mu$ M) concentrations and potentially induces the inflammatory cell apoptosis through a glucocorticoid receptor independent mechanism (12).

In the current study we investigated the anti-inflammatory and anti-oxidant effects of CAPE on amiodarone-induced pulmonary fibrosis in rat. The indices for evaluating these effects include: myeloperoxidase (MPO) activity, malondialdehyde (MDA) concentration (indicators of oxidative stress), superoxide dismutase (SOD) activity (an antioxidant enzyme), and histopathological examination (12).

## Experimental

### *Animals*

Male Wistar albino rats weighing 180-200 g were purchased from Animal house and research center, Jundishapur University of Medical Sciences, Ahwaz, Iran. The animals were kept on a standard food-pellet and tap-water *ad libitum*. The rats were housed in polycarbonate cages (5 animals per cage) and kept in an air-conditioned animals' room at a temperature of  $23 \pm 3^\circ\text{C}$  with a relative humidity of  $50 \pm 5\%$ . The animals' room was on a 12 h light-dark period cycle.

### *Chemical agents*

*Amiodarone:* Donated by Amin

Pharmaceutical Company, Isfahan, Iran

Caffeic acid phenethyl ester (CAPE) (C8221):  
Purchased from Sigma-Aldrich, Germany

Malondialdehyde (MDA) assay kit (NWK-MDA01): Obtained from Northwest Life Science Specialties, LLC (NWLSS™), Vancouver, Canada

Myeloperoxidase (MPO) assay kit (ASA-001): Obtained from Cytostore Targeted Research Tools, Canada

Superoxide dismutase (SOD) assay kit (FR10): Obtained from Oxford Biomedical Research, USA.

#### *Induction of pulmonary fibrosis by amiodarone*

Amiodarone was dissolved in distilled water at 60°C and allowed to be cooled in room temperature before instillation (13). The rats were anesthetized with sodium methohexital (40 mg/Kg). Two doses of amiodarone (6.25 mg/Kg) were given as intra-tracheal instillations, first on what is designated as day 1 and the second on day 3 (14).

#### *Drugs treatment groups*

The animals divided into the following groups (10 rats per group (n = 10)): Group 1: This group received only intra-tracheal amiodarone as positive control. Group 2: The rats in this group received only intra-tracheal vehicle (distilled water) as negative control. Group 3: This group received CAPE 5 µmol/Kg/day, IP, from 2 days before the first dose of amiodarone instillation until 3 weeks after the second dose of amiodarone instillation. Group 4: Received CAPE 10 µmol/Kg/day, IP, 2 days before the first dose of amiodarone instillation until 3 weeks after the second dose of amiodarone (15). The vehicle in all solutions was distilled water.

#### *Collecting tissue samples*

After the last injection of CAPE, rats were killed by sternotomy, following deep ether-induced anesthesia. After mid-line sternotomy, both lungs were removed. Right lungs were preserved in formaldehyde solution (10%) for histopathological evaluation and left lungs were divided into 3 parts, washed with heparinized

saline and stored in -70°C for biochemical examinations.

#### *Biochemical assays*

a) *Malondialdehyde (MDA) assay*: This assay is based on the reaction of MDA with thiobarbituric acid (TBA); forming a MDA-TBA2 adduct that absorbs at 532 nm (16, 17). The assay was performed through the above mentioned kit and via the manufacturer instructions.

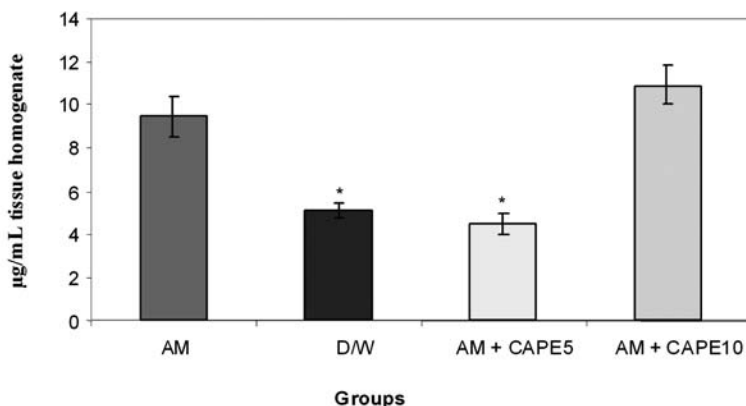
b) *Myeloperoxidase (MPO) assay*: In this assay, H<sub>2</sub>O<sub>2</sub> is broken down by MPO released from samples by homogenization in detergent. The produced radical oxygen (O) combines with a hydrogen-donating chromogen which is thereby converted to a colored compound. The appearance of this colored compound is measured, over time, with a spectrophotometer (at 450 nm) to determine MPO activity in a sample (18). The assay was performed through the above mentioned kit and via the manufacturer protocol.

c) *Superoxide dismutase (SOD) assay*: The assay's method is based on the SOD-mediated increase in the rate of autoxidation of 5, 6, 6a, 11btetrahydro-3, 9, 10-trihydroxybenzo[c]fluorene in aqueous alkaline solution to yield a chromophore with maximum absorbance at 525 nm. The chromophore has not been isolated or characterized (19). The assay is also performed through the above mentioned kit and via the manufacturer protocol.

#### *Histopathological examination and scoring*

Lung tissues were fixed in 10% formaldehyde solution for paraffin slides and sectioned at approximately 5 µm thickness. Tissue affixed to a glass slide deparaffinized, rehydrated and counterstained with hematoxylin and eosin (H&E) (20). The slides were examined by light microscopy and photographed (20). According to the literature, the following scoring codes were used:

0 = Normal lung tissue; 1 = Minimal fibrous with thickening of alveolar or bronchial wall; 2 = Moderate thickening of bronchial wall with mild damage to lung architecture; 3 = Severe distortion of lung structure and presence of large fibrous areas (21).



**Figure 1.** Lung tissue Malondialdehyde concentrations ( $\mu\text{g/mL}$  tissue homogenate) Significant differences between amiodarone-treated group and negative control or  $5 \mu\text{M}$  CAPE-treated groups are indicated by \*( $p < 0.001$ ).

*Statistical analysis*

Statistical comparison was made by one-way ANOVA. Significant  $f$ - values were tested with Tukey's test. Data are presented as mean  $\pm$  SEM.

**Results**

*MDA concentrations in lung tissue*

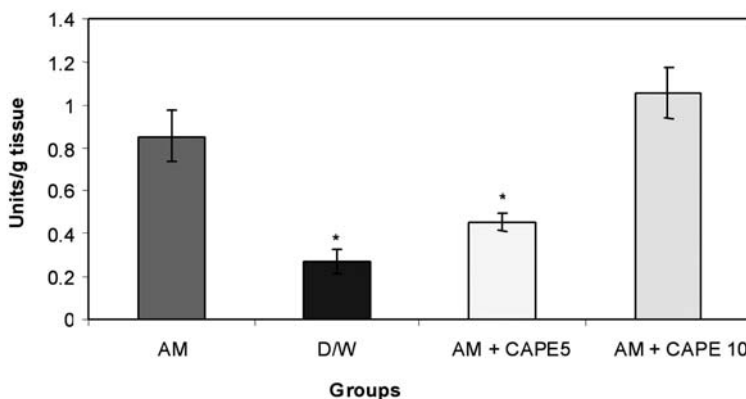
CAPE ( $5 \mu\text{M}$ ) could significantly ( $p < 0.001$ ) reduce the MDA concentration in amiodarone-treated group. However, higher concentration of CAPE ( $10 \mu\text{M}$ ) increased the MDA in amiodarone-treated lung tissue (Figure 1).

*MPO activity in lung tissue*

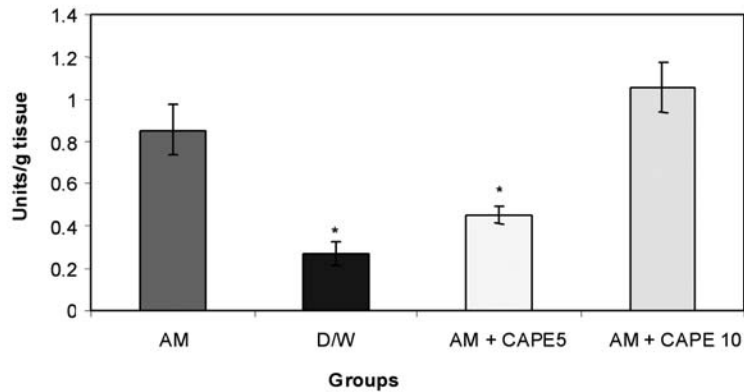
CAPE ( $5 \mu\text{M}$ ) could significantly ( $p < 0.001$ ) reduce the MPO activity in amiodarone-treated group. However, higher concentration of CAPE ( $10 \mu\text{M}$ ) increased the MPO activity in amiodarone-treated lung tissue (Figure 2).

*SOD activity in lung tissue*

CAPE ( $5 \mu\text{M}$ ) could significantly ( $p < 0.001$ ) reduce the SOD activity in amiodarone-treated group. However, higher concentration of CAPE ( $10 \mu\text{M}$ ) could not reduce the SOD activity in amiodarone-treated lung tissue (Figure 3).



**Figure 2.** Lung tissue Myeloperoxidase activity (units/g tissue) Significant differences between amiodarone-treated group and negative control or  $5 \mu\text{M}$  CAPE-treated groups are indicated by \*( $p < 0.001$ ).



**Figure 3.** Lung tissue superoxide dismutase (SOD) activity (units/mL tissue homogenate). Significant differences between amiodarone-treated group and negative control or 5  $\mu$ M CAPE-treated groups are indicated by \*( $p < 0.001$ ).

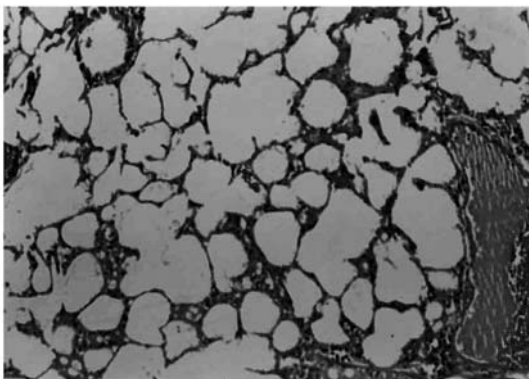
#### Light microscopic results

Histopathological evaluation of the pulmonary tissue was performed with light microscopy for the 4 different experimental groups after the end of study course. Lungs of rats in negative control group, which received distilled water, showed normal lung structure and no lesion was obvious (Figure 4). Three weeks after the second amiodarone instillation, there were infiltration of inflammatory cells and fibroblast and myofibroblast proliferation associated with perivascular and peribronchial fibrosis (Figure 5). In both CAPE-treated

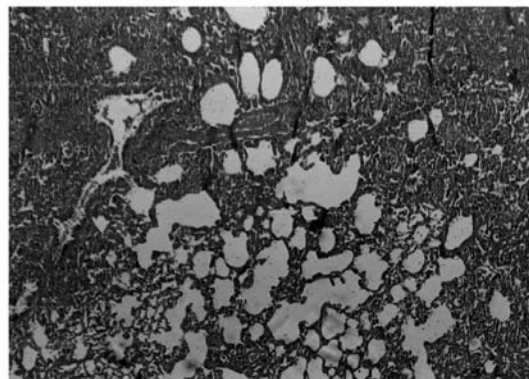
groups, considerable improvement in tissue structure was observed. In these groups, less inflammatory cells and decreased alveolar thickening was evident (Figures 6 and 7).

#### Discussion

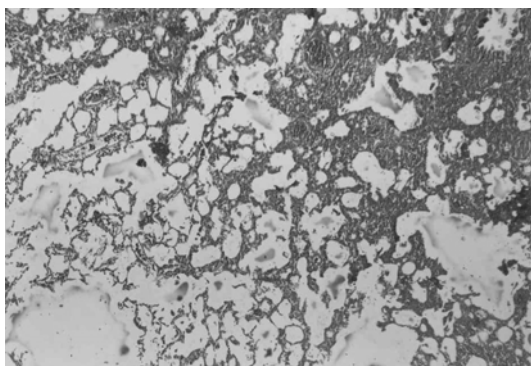
Pulmonary fibrosis (PF) is a chronic, often fatal inflammatory interstitial lung disorder characterized by an accumulation of alveolar macrophages and neutrophils in the lower respiratory tract, parenchymal cell injury, and fibrosis of the alveolar walls (22).



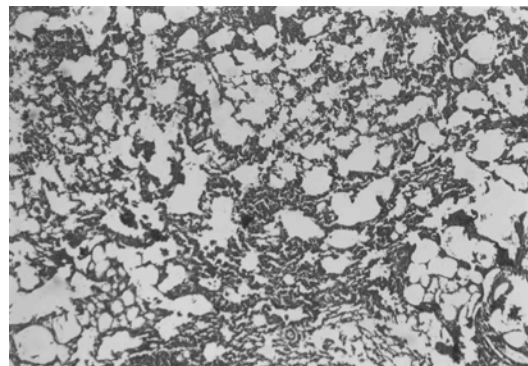
**Figure 4.** Photomicrograph of negative control lung tissue which received only IT distilled water, showing normal lung structure. No inflammatory cells are evident. Donated score = 0 (H&E,  $\times 100$ ).



**Figure 5.** Photomicrograph of rat lung tissue 3 weeks after the second amiodarone administration. There is an increase in cellularity of alveolar septum and intra-alveolar fibrosis with collagenous bands accompanying great septal thickness and diffuse damage to lung architecture is observed. Donated score is 3 (H&E,  $\times 100$ ).



**Figure 6.** Photomicrograph of rat lung tissue which received amiodarone + CAPE 5  $\mu\text{mol/Kg}$ . Less interstitial fibrosis with scattered septal thickness and slight infiltration of lymphocytes in comparison to positive control group is seen. Donated score = 2 (H&E,  $\times 100$ ).



**Figure 7.** Photomicrograph of rat lung tissue which received amiodarone + CAPE 10  $\mu\text{mol/Kg}$ . Decreased fibrosis and septal thickness is evident. Donated score = 1 (H&E,  $\times 100$ ).

The evidence of a redox imbalance in lung fibrosis is substantial, and the rationale for testing antioxidants as potential new therapeutics for lung fibrosis is appealing. Current animal models of lung fibrosis showed a clear involvement of ROS in their pathogenesis (23).

The mechanisms proposed for amiodarone-induced PF are: (i) altered inflammatory mediator release; (ii) cell membrane perturbation; (iii) phospholipidosis promotion; (iv) altered  $\text{Ca}^{2+}$  cellular homeostasis; (v) mitochondrial dysfunction; and (vi) free radical production. Although the exact mechanism is not fully understood (24).

In this model of amiodarone-induced lung injury we observed a decrease in malondialdehyde concentrations, and myeloperoxidase and superoxide dismutase activities in lung tissue with CAPE (5  $\mu\text{mol/kg}$ ). In addition, in histopathological examination there were structural changes in amiodarone-treated group in comparison to negative control group (D/W treated animals). A pronounced decrease in lung fibrosis was observed in CAPE treated groups. Previous researches showed free radical scavenging, anti-inflammatory, anti-fibrotic and anti-endotoxine activities for CAPE (12, 21, 25).

In this study MDA increased significantly in the amiodarone treated group in comparison with the vehicle treated rats, and CAPE with the dose of 5  $\mu\text{mol/kg}$  could decrease it significantly even less than the negative control group. As MDA is a highly reactive agent produced

as a byproduct of polyunsaturated fatty acid peroxidation and arachidonic acid metabolism, (26) we can say that low-dose CAPE is a very potent anti-lipid peroxidation and antioxidant agent. In contrast to previous studies (12, 21), there was not any improvement with 10  $\mu\text{mol/kg}$  CAPE and even there was significant increase in MDA concentration in comparison with negative control and low dose CAPE groups.

In current study we also found a significant decrease in MPO activity in the low-dose CAPE treated animals in comparison to positive control. When accumulated and activated, neutrophils can release myeloperoxidase, an 115,000-dalton protein which can interact with  $\text{H}_2\text{O}_2$ , a product of both mononuclear phagocytes and neutrophils, to form a highly toxic anion, which can initiate oxidative stress (12, 22). Our results suggest that low dose CAPE could successfully decrease inflammation and oxidant-mediated lung toxicity. However; high dose of CAPE had opposite effect compared to the previous studies; In fact there was significant increase in MPO activity in comparison with negative control and low dose CAPE groups (12, 21).

According to these findings it may exist a toxic effect for CAPE of 10  $\mu\text{mol/kg}$  via oxidant system. One possible explanation for this finding is that administration of high dose of CAPE (10  $\mu\text{mol/kg}$ ) might have caused tissue injury related to another species of active oxygen. It should be evaluated more, as the other studies do not show such an effect. Also it may be an observer error

or a technical defect in some studies.

We also found significant increase in SOD activity in positive control group in comparison with negative control. It is reasonable, as in the normal airway mucosa, antioxidant defense systems, such as superoxide dismutase (SOD), glutathione peroxidase, and catalase exist to protect the mucosa from various oxidant stimuli and in fact this enzyme has applied for the treatment of PF in some studies (27, 28) and they showed inhibitory effects of SOD on bleomycine-induced pulmonary fibrosis. As it was expected there was significant decrease in SOD activity in 5  $\mu\text{mol/kg}$  CAPE-treated group, close to negative control, which shows 5  $\mu\text{mol/kg}$  CAPE decreased the need for compensatory increase in SOD activity against amiodarone-induced oxidative injury.

In this study, we concluded that systemic CAPE with the dose of 5  $\mu\text{mol/kg}$  can diminish amiodarone-induced lung injury successfully. Therefore; CAPE may be a potential treatment for pulmonary fibrosis. However more investigations are required to elucidate the exact mechanism of this novel agent in pulmonary fibrosis.

### Acknowledgments

This project is a part of the thesis for N. Zaemzadeh as a PhD Student of pharmacology (via the project numbered U-86001) and the authors wish to thank Ahwaz Jundishapur University of Medical Sciences for their financial support and Dr. Ariyan Esmaeeli for his great cooperation as the statistical consultant.

### References

- (1) Coker RK and Laurent GJ. Anticytokine approaches in pulmonary fibrosis: bringing factors into focus. *Thorax* (1997) 52: 294-6.
- (2) Zhang K and Phan SH. Cytokines and pulmonary fibrosis. *Biol. Signals* (1996) 5: 232-9.
- (3) Hemmati AA, Aghel N, Nazari Z, Mohammadian B and Hasanvand N. Grape seed extract can reduce the fibrogenic effect of bleomycin in rat lung. *Iranian J. Pharm. Sci.* (2006) 2: 142-150
- (4) Kalpana C, Sudheer AR, Rajasekharan KN and Menon VP. Comparative effects of curcumin and its synthetic analogue on tissue lipid peroxidation and antioxidant status during nicotine-induced toxicity. *Singapore Med J.* (2007) 48: 124-30.
- (5) Mohammadzadeh S, Hamed M, Amanzadeh Y, Sadat Ebrahimi SE and Ostad SN. Antioxidant power of Iranian propolis extract. *Food Chem.* (2007) 103: 729-33.
- (6) Bolt MW, Raczy WJ, Brien JF and Massey TE. Effects of vitamin E on cytotoxicity of amiodarone and N-desethylamiodarone in isolated hamster lung cells. *Toxicol.* (2001) 166: 109-18.
- (7) Punithavathi D, Venkatesan N and Babu M. Protective effects of curcumin against amiodarone-induced pulmonary fibrosis in rats. *Br. J. Pharmacol.* (2003) 139: 1342-50.
- (8) Feng L, Suresh A, Yasuhiro T and Shigetoshi K. Cytotoxic constituents from Brazilian red propolis and their structure-activity relationship. *Bioorg. Med. Chem.* (2008) 16: 5434-40
- (9) Sahin O, Sulak O, Yavuz Y, Uz E, Eren I and Ramazan Yilmaz H. Lithium-induced lung toxicity in rats: the effect of caffeic acid phenethyl ester (CAPE). *Pathology* (2006) 38: 58-62.
- (10) Padmavathi R, Senthilnathan P, Chodon D and Sakthisekaran D. Therapeutic effect of paclitaxel and propolis on lipid peroxidation and antioxidant system in 7,12-dimethyl benz(a)anthracene-induced breast cancer in female Sprague Dawley rats. *Life Sci.* (2006) 78: 2820-5.
- (11) Koksel O, Ozdulger A, Tamer L, Cinel L, Ercil M, Degirmenci U, Kanik A and Atik U Effects of caffeic acid phenethyl ester on lipopolysaccharide-induced lung injury in rats. *Pulm. Pharmacol. Ther.* (2006) 19: 90-5.
- (12) Card JW, Leeder RG, Raczy WJ, Brien JF, Bray TM and Massey TE. Effects of dietary vitamin E supplementation on pulmonary morphology and collagen deposition in amiodarone- and vehicle-treated hamsters. *Toxicology* (1999) 133: 75-84.
- (13) Taylor MD, Van Dyke K, Bowman LL, Miles PR, Hubbs AF, Mason RJ, Shannon K and Reasor MJ. A characterization of amiodarone-induced pulmonary toxicity in F344 rats and identification of surfactant protein-D as a potential biomarker for the development of the toxicity. *Toxicol. Appl. Pharmacol.* (2000) 167: 182-90.
- (14) Agoston M, Orsi F, Feher E, Hagymasi K, Orosz Z, Blazovics A, Feher J and Vereckei A. Silymarin and vitamin E reduce amiodarone-induced lysosomal phospholipidosis in rats. *Toxicology* (2003) 190: 231-41.
- (15) Jentzsch AM, Bachmann H, Furst P and Biesalski HK. Improved analysis of malondialdehyde in human body fluids. *Free Radic. Biol. Med.* (1996) 20: 251-6.
- (16) Miller LS, O'Connell RM, Gutierrez MA, Pietras EM, Shahangian A, Gross CE, et al. MyD88 mediates neutrophil recruitment initiated by IL-1R but not TLR2 activation in immunity against *Staphylococcus aureus*. *Immunity.* 2006; 24: 79-91.
- (17) Miller LS, O'Connell RM, Gutierrez MA, Pietras EM, Shahangian A, Gross CE, Thirumala A, Cheung AL,

- Cheng G and Modlin RL. MyD88 mediates neutrophil recruitment initiated by IL-1R but not TLR2 activation in immunity against *Staphylococcus aureus*. *Immunity* (2006) 24: 79-91.
- (18) Nebot C, Moutet M, Huet P, Xu JZ, Yadan JC and Chaudiere J. Spectrophotometric assay of superoxide dismutase activity based on the activated autoxidation of a tetracyclic catechol. *Anal. Biochem.* (1993) 214: 442-51.
- (19) Bancroft J. D., and Stevens A. Theory and Practice of Histological Techniques. Edinburgh, UK: Churchill Livingstone 1990.
- (20) DiMango E, Ratner AJ, Bryan R, Tabibi S, Prince A. Activation of NF-kappaB by adherent *Pseudomonas aeruginosa* in normal and cystic fibrosis respiratory epithelial cells. *J Clin Invest.* 1998; 101: 2598-605.
- (21) Ozyurt H, Sogut S, Yildirim Z, Kart L, Iraz M, Armutcu F, Temel s, Özen S, Uzun A and Akyol Ö. Inhibitory effect of caffeic acid phenethyl ester on bleomycine-induced lung fibrosis in rats. *Clin. Chim. Acta* (2004) 339: 65-75.
- (22) Cantin AM, North SL, Fells GA, Hubbard RC and Crystal RG. Oxidant-mediated epithelial cell injury in idiopathic pulmonary fibrosis. *J. Clin. Invest.* (1987) 79: 1665-73.
- (23) Day BJ. Antioxidants as potential therapeutics for lung fibrosis. *Antioxid. Redox. Signal.* (2008) 10: 355-70.
- (24) Nicolescu AC, Comeau JL, Hill BC, Bedard LL, Takahashi T, Brien JF, Racz WJ and Massey TE. Aryl radical involvement in amiodarone-induced pulmonary toxicity: investigation of protection by spin-trapping nitrones. *Toxicol. Appl. Pharmacol.* (2007) 220: 60-71.
- (25) Armutcu F, Gurel A, Atmaca H and Kart L. Caffeic acid phenethyl ester and vitamin E moderates IL-1 $\beta$  and IL-6 in bleomycin-induced pulmonary fibrosis in rats. *Pesticide Biochem. Physiol.* (2006) 88: 48.
- (26) Supratim KR and Sengupta C. *In-vitro* evaluation of protective effects of ascorbic acid and water extract of *Spirulina plantesis* (blue green algae) on 5-Fluorouracil-induced lipid peroxidation. *Acta Pol. Pharm. Drug Res.* (2007) 64: 335-44.
- (27) Tamagawa K, Taooka Y, Maeda A, Hiyama K, Ishioka S and Yamakido M. Inhibitory effects of a lecithinized superoxide dismutase on bleomycin-induced pulmonary fibrosis in mice. *Am. J. Respir. Crit. Care Med.* (2000) 161: 1279-84.
- (28) Safaeian L, Jafarian A, Rabbani M, Mirmohammad Sadeghi H, Torabinia N and Alavi SA. The effect of AT1 receptor blockade on bax and bcl-2 expression in bleomycin-induced pulmonary fibrosis. *Daru* (2009) 17: 53-59.

---

This article is available online at <http://www.ijpr.ir>

---