

## Anti-ischemic Effect of *Nigella sativa* L. Seed in Male Rats

Hossein Hosseinzadeh<sup>\*a</sup>, Mahmoud Reza Jaafari<sup>a</sup>, Ali Reza Khoei<sup>b</sup>  
and Massoud Rahmani<sup>a</sup>

<sup>a</sup>Pharmaceutical Research Center, School of Pharmacy, Mashhad University of Medical Sciences, Mashhad Iran. <sup>b</sup>School of Medicine, Mashhad University of Medical Sciences, Mashhad Iran.

---

### Abstract

The anti-ischemic effect of aqueous and ethanolic extracts of *Nigella sativa* L. seed was studied using a four-vessel occlusion model in rats. The ischemia was evaluated by optical and transmission electron microscopy. After 20 min of forebrain ischemia, agents were administered intraperitoneally after reperfusion. Both extracts comprised an alkaloid. In ischemic rats, the aqueous (1 g/kg) and ethanolic (1.6 g/kg) extracts significantly reduced neural cell injuries in the CA1 and CA3 regions of rat hippocampus. The LD50 values (mice, i.p.) of the aqueous and ethanolic extracts were 1.69 g/kg and 2.25 g/kg, respectively. These results indicate that the *N. sativa* seed extracts could have a therapeutic effect against cerebral ischemia.

**Keywords:** *Nigella sativa* seed; Anti-ischemic activity; four-vessel occlusion; hippocampus.

---

### Introduction

Ischemic stroke results from a transient or permanent reduction in the cerebral blood flow, that is restricted to the territory of a major brain artery (1). Three major approaches have been investigated to ameliorate ischemia-induced brain damage: (i) interfering with the excitatory action of glutamate; (ii) preventing intracellular accumulation of Ca<sup>2+</sup>; and (iii) preventing the destructive actions of reactive oxygen species (2). Ischemia causes an increased lipid peroxidation reaction and elevated production of free radicals, which contributes to a secondary damage of the nervous tissue (3-4).

*Nigella sativa* L. (Ranunculaceae) seed and/or its' constituents have been reported to demonstrate

many pharmacological activities such as analgesic (5), anti-inflammatory (6), antioxidant and anti-eicosanoid (7-9), antibacterial (10), calcium channel blocking effects (11) and a decreasing effect on intracellular calcium in the mast cells (12).

Recently, it has been shown that *N. sativa* oil had a marked protective action against ischemia/reperfusion-induced gastric mucosal lesions, an effect that was associated with suppression in the levels of lipid peroxide (LPX) and lactate dehydrogenase (LDH) and an increase in those of glutathione (GSH) and superoxide dismutase (SOD) (13). As some of these activities (antioxidant, lipid peroxide inhibition, and decreasing effect on intracellular calcium) might be useful in the treatment of stroke damage, we have studied the anti-ischemic effects of *N. sativa* seed extracts in rats.

---

\* Corresponding author:

E-mail: hosseinzadehh@yahoo.com

## Experimental

### *Animals*

90 Male albino mice, weighing 25-30 g, and 24 Wistar rats, weighing 250-300 g, were obtained from a random bred colony and maintained with on a laboratory pellet chow (Khorassan Javane Co, Mashhad, I.R. Iran), in the animals house of Mashhad University of Medical Sciences. Animal were housed in a colony room with a 12/12 h light/dark cycle at  $21 \pm 2^\circ\text{C}$  and had free access to water and food. Principles of laboratory animal care were followed.

### *Plant material*

*N. sativa* seeds, collected from the northern parts of Khorassan, were purchased from a local market in Mashhad, Iran. Seeds were cultivated and the resulting plants identified by Mr Joharchi (247-1419-01) at the Herbarium Center of Mashhad Ferdowsi University.

### *Preparation of extracts*

The powdered seed (50 g) was boiled in 500 ml boiling water for 15 min. Subsequently, the mixture was filtered and concentrated under reduced pressure at  $35^\circ\text{C}$  (yield: 11.5% w/w). For preparation of the ethanolic extract, the powdered seed (50 g) was macerated in 500 ml ethanol (80% v/v) for three days and subsequently the mixture was filtered and concentrated under reduced pressure at  $40^\circ\text{C}$  (yield: 9.6% w/w).

### *Preliminary chemical tests*

Phytochemical screening of the extracts was performed using the following reagents and chemicals (14):

Alkaloid with dragendorff's reagent, flavonoids with the use of Mg and HCl; tannins with 1% gelatin and 10% NaCl solutions and saponins through their with ability to produce suds.

### *The acute toxicity*

Different doses of the extracts were injected into groups of six mice. After 48 h, any mortality was considered and LD50 values and the corresponding confidence limits were determined by the Litchfield and Wilcoxon method (PHARM/PCS Version 4).

### *Anti-ischemic activity*

#### *Surgery*

Ischemia was induced in rat using the four-vessel occlusion model (15). Rats were anesthetized by xylazine (6 mg/kg, i.p.) and ketamine (60 mg/kg, i.p.). Both vertebral arteries were electrocauterized after exposure of the alar foramina. On the next day, the bilateral common carotid arteries (CCAs) were isolated from the surrounding tissues. Forebrain ischemia was induced by occlusion of the CCAs using metal clips. After 20 min of forebrain ischemia CCAs, were unclamped and agents administered intraperitoneally after reperfusion. Three days after ischemia, the brain was removed and hippocampal formation determined by histological evaluation, using optical and transmission electron (Leo 910) microscopes.

Four groups of animals were used: Group 1 served as the ischemic control, to which saline was injected intraperitoneally (10 ml/kg, i.p.). To another group of animals, phenytoin (50 mg/kg) was administered (i.p.) as the positive control and to the remaining two groups of rats, the aqueous and ethanolic extracts (1 and 1.6 g/kg, respectively) (i.p.) were injected.

#### *Histology*

##### *Optical microscopy*

For optical microscopy studies, after craniotomy, the whole brain of each animal was removed and immediately immersed in 10% formaldehyde solution and fixed overnight. Multiple serial sagittal sections of each brain (hippocampus) were obtained (Leitz microtome) and routinely processed by embedding in paraffin blocks and 5  $\mu\text{m}$  thick sections were stained, using the histopathological hematoxylin/Eosin method (16). All the slides were studied single blindly and the amount of necrosis; with respect to the obvious cellular necrotic changes i.e. pyknosis (nuclear shrinkage and darkening), karyorrhexis (nuclear fragmentation) and karyolysis (nuclear lysis); was graded in a semiquantitative manner in all three hippocampus regions (CA1, CA2, CA3) of each brain hemisphere. In this applied grading system, necrotic grade one (mild) means necrotic changes in less than 10% of the hippocampal neurons, grade two (moderate) in about 10-50% and grade three (severe) in more

than 50% of neurons. Grade 0 means that no significant necrotic change has occurred. Then the grade number obtained from each group of differently treated animals (four groups, each consisting of 12 hippocampuses of 6 animals) in all three hippocampal regions were added up and a final necrotic score resulted for each group.

#### Electron microscopy

The samples were fixed for 30 min at 4°C and then overnight 2.5 % glutaraldehyde at room temperature, in a pH 7.2 0.1 M phosphate buffer solution containing. They were washed three times (duration of 24 h) in the same buffer at 4°C, then post fixed for 1 h 1% osmium tetroxide in the same buffer. Again, the samples were washed three times (10 min each time) with distilled water, then dehydrated and enblock stained as follows: 30% ethanol, room temperature, 5 min; 50% ethanol, room temperature, 5 min; saturated aranyl acetate in 70% ethanol, room temperature, 1 h; 70% ethanol, room temperature, 5 min; 96% ethanol, room temperature, 5 min; and 100% ethanol, room temperature three times, 5 min. Then, the alcohol was replaced by propylene oxide for three treatments, 5 min each time, at room temperature. The samples were infiltrated with an increasing concentration of Epon/Araldite resin in propylene oxide, 1:2 (30 min), 2:1 (2 h), and then pure Epon/Araldite (overnight). Finally, the samples were placed in fresh Epon/Araldite, placed at the bottom of gelatin capsules, and left to polymerize for 48 h at 55°C.

For ultra thin sections (50-90 nm), the block face was trimmed and cut on a LKB ultratome (type 4801A) with either glass knives (LKB

knifewater type 7801A) or a diamond knife (Diatom, MT 7403) at a thickness of silver-gold interface color, and picked up on 30 nm mesh copper grids. The sections were stained with a 2% aqueous solution of aranyl acetate for 3 min and then a lead citrate (0.5%) solution for 5-10 min. ultimately, the samples were viewed by a LEO 910 transmission electron microscope and photographs taken.

#### Statistical analysis

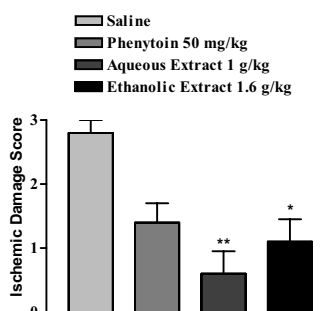
Analysis of variance followed by the multiple comparison test of Tukey-Kramer was used to compare antihypoxic data. Kruskal-Wallis followed by Dunn test was used to compare anti-ischemic data (non-parametric data). The data presented are expressed as mean values  $\pm$  S.E.M.

### Results and Discussion

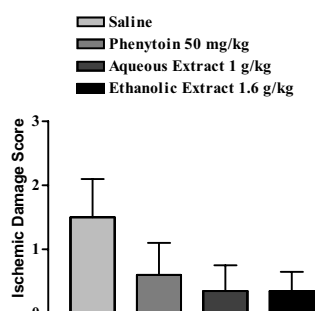
Preliminary phytochemical tests indicated that the aqueous and ethanolic extracts of *N. sativa* seed, only comprised of alkaloids.

The LD50 values in mice received aqueous and ethanolic extracts were 1.69 g/kg (95% CL: 1.36, 2.01) and 2.25 g/kg (95% CL: 1.93, 2.64), respectively.

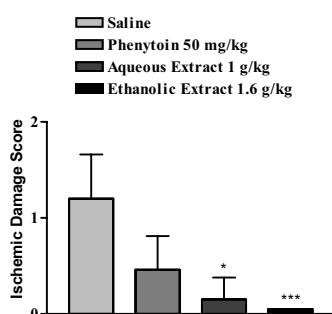
The extracts reduced the neuronal damage in the CA1 (Fig. 1) and CA3 (Fig. 3) hippocampal neurons of rat, but not in the CA2 neurons (Fig. 2). In the saline group, severe necrotic changes occurred, especially in the CA1, and also in the two other regions. In the phenytoin group (as the positive group), necrosis was about 50% less than the saline group.



**Figure 1.** Neuroprotective effects of *Nigella sativa* aqueous and ethanolic seed extracts and phenytoin in CA1 hippocampal neurons of rats after global cerebral ischemia. Agents were administered intraperitoneally. Values are the mean  $\pm$  S.E.M of ischemic damage grade for 6 rats, \* P<0.05, \*\* P<0.01, compared to the control, Dunn test.



**Figure 2.** Neuroprotective effects of *Nigella sativa* aqueous and ethanolic seed extracts and phenytoin in CA2 hippocampal neurons of rats after global cerebral ischemia. Agents were administered intraperitoneally. Values are the mean  $\pm$  S.E.M of ischemic damage grade for 6 rats, compared to the control, Kruskal-Wallis test.



**Figure 3.** Neuroprotective effects of *Nigella sativa* aqueous and ethanollic seed extracts and phenytoin in CA3 hippocampal neurons of rats after global cerebral ischemia. Agents were administered intraperitoneally. Values are the mean ± S.E.M of ischemic damage grade for 6 rats, \* P<0.05, \*\*\* P<0.001, compared to the control, Dunn test.

In the aqueous and ethanollic *N. sativa* seed extract groups, necrotic changes were lower than the saline group and the total score decreased by more than 50%.

In the saline ischemic group, complete chromatolysis accompanied by the disappearance of nucleus membrane was seen in the electron microscopy study (Fig. 4). In the aqueous extract group, incomplete destruction of the nuclear membrane, with the presence of several vacuoles, were seen in some samples. Absorbive vacuoles were seen in the ethanollic extract group. Chromatolysis and incomplete destruction of the nuclear membrane was observed in the phenytoin group. The results obtained in the present investigation suggest that the *N. sativa* seed extract decreases cerebral ischemia-reperfusion injury-induced pathological stress in the rat model.

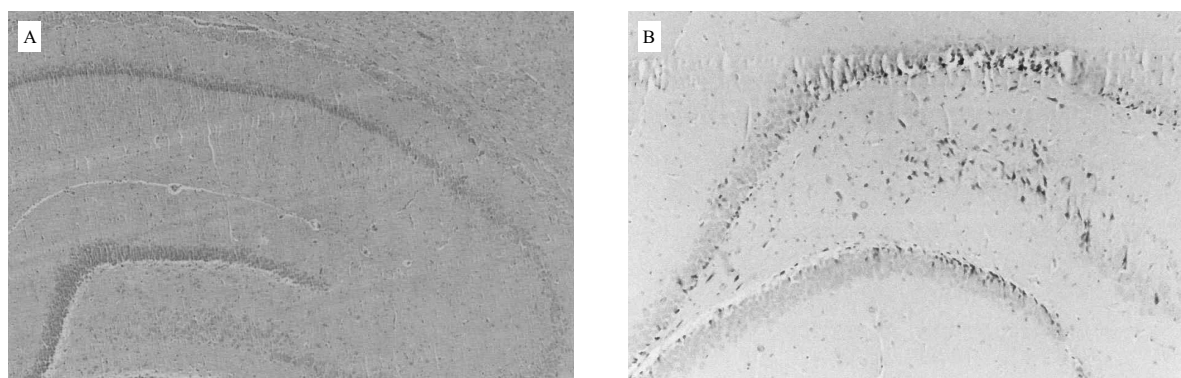
The exact mechanism of action of anti-ischemic activities is not clear. *N. sativa* seed has

a variety of activities including antioxidant (7, 9), anti-eicosanoid (8), calcium channel blocker effects (11) and a decreasing effect on intracellular calcium in mast cells (12). Antioxidant (17-18), lipoxygenase and cyclooxygenase inhibitory activities (19) and a reduction of intracellular calcium or calcium channel blocking effects (2, 20) may induce neuroprotective effects and lessen ischemic insults. Any of these activities may be involved in the anti-ischemic activity of the extract.

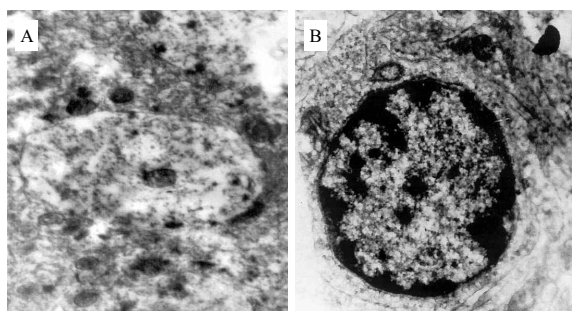
Phytochemical tests showed that the extracts contain alkaloids. Antihypoxic and anti-ischemic activities have been reported for some alkaloids (21-22). The putative pharmacologically active constituents of *N. sativa* seed are quinone compounds such as thymoquinone, dithymoquinone, thymohydroquinone, and thymol (23). Alkaloid compounds such as nigellimine (24) and nigellidine (25) have been found in *N. sativa* seeds.

Free radical-induced lipid peroxidation produces cytotoxic aldehydes, including malondialdehyde (MDA), 4-hydroxynonenal (HNE) and acrolein (26). Several studies have shown that the antioxidant compounds and free radical scavengers inhibit lipid peroxidation caused by free radicals and excitatory amino acid-induced neuronal injury following ischemia (27). The present study showed that the *N. sativa* extracts could decrease global ischemia-reperfusion injuries. The inhibition of injuries is probably related to the antioxidant properties, free radical scavenging and other effects of the extracts, which need further studies.

It is concluded that the aqueous and ethanollic



**Figure 4.** Optical microscopy photomicrograph of hematoxylin/Eosin-stained hippocampus of rat in either the absent ischemia (ischemic score=0) (A), or aqueous extract, 1 g/kg (ischemic score=1) (B) groups that had been subjected to 20 min global ischemia (Magnification 10×10).



**Figure 5.** Electron microscopy photomicrograph of acetate uranyle and lead citrate-stained CA1 hippocampus of rat in either normal saline (A), or aqueous extract, 1 g/kg (B) groups that had been subjected to 20 min global ischemia (Magnification ×6300 (A) and ×10,000 (B)).

extracts of *N. sativa* seeds have protective effects against ischemia in rat. This effect could be related to the presence of alkaloid component and/or other constituents.

### Acknowledgement

The authors are thankful to the Vice Chancellor of Research, Mashhad University of Medical Sciences for financial support.

### References

- (1) Dirnagl U, Iadecola C and Moskowitz MA. Pathobiology of ischemic stroke: an integrated view. *Trends Neurosci.* (1999) 22: 391-397
- (2) Jurlink BHJ and Sweeney MI. Mechanisms that result in damage during and following cerebral ischemia. *Neurosci. Behav. Rev.* (1997) 21: 121-128
- (3) Patel M, Day BJ, Crapo JD, Fridovich I and McNamara JO. Requirement for superoxide in excitotoxic cell death. *Neuron* (1996) 16: 345-355
- (4) Weglicki WB, Dichens BF and Mak JT. Enhanced lysosomal phospholipid degradation and lysophospholipid production due to free radicals. *Biochem. Biophys. Res. Commun.* (1984) 124: 229-235
- (5) Abdel-Fattah AM, Matsumoto K and Watanabe H. Antinociceptive effects of *Nigella sativa* oil and its major component, thymoquinone in mice. *Eur. J. Pharmacol.* (2000) 400: 89-97
- (6) Mutabagani A and El-Mahdy SA. Study of the anti-inflammatory activity of *Nigella sativa* L. and thymoquinone in rats. *Saudi Pharm. J.* (1997) 5: 110-113
- (7) Burits M and Bucar F. Antioxidant activity of *Nigella sativa* essential oil. *Phytother. Res.* (2000) 14: 323-328
- (8) Houghton PJ, Zarka R, de las Heras B and Hault JR. Fixed oil of *Nigella sativa* and derived thymoquinone inhibit eicosanoid generation in leukocytes and membrane lipid peroxidation. *Planta Med.* (1995) 61: 33-36
- (9) Turkdogan MK, Agaoglu Z, Yener Z, Sekeroglu R, Akkan HA and Avci ME. The role of antioxidant vitamins (C and E), selenium and *Nigella sativa* in the prevention of liver fibrosis and cirrhosis in rabbits: new hopes. *Dtsch. Tierarztl. Wochenschr.* (2001) 108: 71-73
- (10) Morsi NM. Antimicrobial effect of crude extracts of *Nigella sativa* on multiple antibiotics-resistant bacteria. *Acta Microbiol. Pol.* (2000) 49: 63-74
- (11) Gilani AH, Aziz N, Khurram IM, Chaudhary KS and Iqbal A. Bronchodilator, spasmolytic and calcium antagonist activities of *Nigella sativa* seeds (Kalonji): a traditional herbal product with multiple medicinal uses. *J. Pak. Med. Assoc.* (2001) 51: 115-120
- (12) Chakravarty N. Inhibition of histamine release from mast cells by nigellone. *Ann. Allergy* (1993) 70: 237-242
- (13) El-Abhar HS, Abdallah DM and Saleh S. Gastroprotective activity of *Nigella sativa* oil and its constituent, thymoquinone, against gastric mucosal injury induced by ischemia/reperfusion in rats. *J. Ethnopharmacol.* (2003) 84: 251-258
- (14) Evans WC. *Trease and Evans' Pharmacognosy.* Bailliere Tindall Press, London (1983) 309-706
- (15) Pulsinelli WA and Brierley JB. A new model of bilateral hemispheric ischemia in the unanesthetized rat. *Stroke* (1979) 10: 267-272
- (16) Sydserff SG, Cross AJ, Murray TK, Jones JA and Green AR. Clomethiazole is neuroprotective in models of global and focal cerebral ischemia when infused at doses producing clinically relevant plasma concentrations. *Brain Res.* (2000) 862: 59-62
- (17) Ahlemeyer B, Junker V, Hühne R and Kriegstein J. Neuroprotective effects of NV-31, a bilobalide-derived compound: evidence for an antioxidative mechanism. *Brain Res.* (2001) 890: 338-342
- (18) LARGERON M, MESPLES B, GRESSENS P, CECHELLI R and SPEDDING M. The neuroprotective activity of 8-alkylamino-1,4-benzoxazine antioxidants. *Eur. J. Pharmacol.* (2001) 424: 189-194
- (19) Arai K, Nishiyama N, Matsuki N and Ikegaya Y. Neuroprotective effects of lipoxygenase inhibitors against ischemic injury in rat hippocampal slice cultures. *Brain Res.* (2001) 904: 167-172
- (20) Funato H, Kawano H, Akada Y, Katsuki Y, Sato M and Uemura A. Effects of a calcium antagonist, lacidipine, on experimental focal cerebral ischemia in rats. *Jpn. J. Pharmacol.* (1997) 75: 415-423
- (21) Araki T, Kato H and Kogure K. Posts ischemic alteration of muscarinic acetylcholine and adenosine  $\alpha$ -1 binding sites in gerbil brain protective effects of a novel vinca alkaloid derivative vinconate and pentobarbital using an autoradiographic study. *Res. Exp. Med.* (1992) 192: 79-88
- (22) Favit A, Sortino M, Aleppo G, Scapagnini U and Canonico P. The inhibition of peroxide formation as

- a possible substrate for the neuroprotective action of dihydroergocryptine. *J. Neural. Transm. Suppl.* (1995) 45: 297-305
- (23) Ghosheh OA, Houdi AA and Crooks PA. High performance liquid chromatographic analysis of the pharmacologically active quinones and related compounds in the oil of the black seed (*Nigella sativa* L.). *J. Pharm. Biomed. Anal.* (1999) 19: 757-762
- (24) Rahman A, Malik S and Zaman K. Nigellimine: a new isoquinoline alkaloid from the seeds of *Nigella sativa*. *J. Nat. Prod.* (1992) 55: 676-678
- (25) Rahman A, Malik S, Hasan SS, Choudhary MI, Ni CZ and Clardy J. Nigellidine, a new indazole alkaloid from the seeds of *Nigella sativa*. *Tetrahedron Lett.* (1995) 36: 1993-1996
- (26) Rao MA, Hatcher JF and Dempsey RJ. Lipid metabolism in ischemic neuronal death. *Rec. Res. Dev. Neurochem.* (1999) 2: 533-549
- (27) Wang Q, Xu J, Rottinghaus GE, Simonyi A, Lubahn D, Sun GY and Sun AY. Resveratrol protects against global cerebral ischemic injury in gerbils. *Brain Res.* (2002) 958: 439-447

---

This article is available online at <http://www.ijpr-online.com>

---