

Original Article

A Comparative Study of Aminosidine Sulfate, Meglamine Antimoniate, Combination of both and Glucantime in Murine Leishmaniasis Treatment of Cutaneous Leishmaniasis, Caused by *Leishmania tropica*, with Topical Application of Paromomycin 20% in BALB-c Mice

Mohammad Shahidi Dadras^{a*}, Afshin Mirzaei^b, Bahram Kazemi^c,
Leyla Nabai^a and Ali Sharifian^a

^aSkin Research Center, Shohada Hospital, Shaheed Beheshti University of Medical Sciences, Tehran, Iran. ^bFaculty of Medicine, Rafsanjan University of Medical Science, Rafsanjan, Iran. ^cCellular and Molecular Biology Research Center, Faculty of Medicine, Shaheed Beheshti University of Medical Sciences, Tehran, Iran.

Abstract

The current treatment of choice for cutaneous leishmaniasis is either parenteral or intralesional antimonial compounds. Each of these treatments has its own downfalls which include toxic side effects with the parenteral injection and pain at the site of injection with the intralesional injection. In recent years, there has been more focus on Paromomycin as an alternative drug; however, current data arose many controversies.

In this study, the efficacy of different therapeutic regimens including topical paromomycin 20%, topical gentamycin 0.5%, intralesional glucantime injections, topical paromomycin 20% combine with gentamycin 0.5%, and placebo were compared. The results showed that the topical application of paromomycin had better response, less recurrence. In conclusion, topical paromomycin 20% can be an appropriate substitute for intralesional injection of glucantime, but more studies are needed to support its efficacy in human cutaneous leishmaniasis.

Keywords: BALB/c mice; Cutaneous leishmaniasis; Gentamycin; Meglumine antimoniate; Paromomycin.

Introduction

Cutaneous leishmaniasis is an infectious disease caused by several members of the *Leishmania* family. In the Old World, most cases are caused by *Leishmania major* and *L. tropica* (1, 2). Incidence of cutaneous leishmaniasis is about 0.3 to 1.5 millions annually (1). This infection is transmitted to human by mosquito bites from infected individuals and animal

hosts (1, 3). In the Middle East, outbreaks of this infection occurred due to new irrigation projects, decreased spraying of dichloro-diphenyl-trichloroethane (DDT) and an increase in the population of rodents and sand flies (1).

Cutaneous leishmaniasis is usually self-limited and only a few cases progress to mucocutaneous or disseminated forms that can lead to death (3). Since most lesions remain on the face and other exposed areas for several months, active lesions and their permanent scars can cause disfiguration and devastating psychological effects on infected

* Corresponding author:

E-mail: Shahidimohammad@yahoo.com

individuals. Therapy is necessary for reducing the duration of active disease and minimizing the scars; although, a more effective treatment for cutaneous leishmaniasis has yet to be discovered.

Currently, the drugs of choice are antimonial compounds (parenteral or intralesional) (1, 3). Parenteral administration of these drugs may cause cardiac, hepatic or pancreatic side-effects and can lead to death (1, 3). Intralesional injection is also painful (1) and may cause hypersensitivity and systemic side effects. This shows the necessity for an effective and less toxic treatment. Other drugs such as pentamidine, amphotericin B, allopurinol, ketoconazole and itraconazole are either too toxic or less effective to be considered as a first line of therapy (1, 3). Paromomycin (aminosidine), an aminoglycoside antibiotic, has received more attention for its anti-Leishmania activity in visceral leishmaniasis (3-5). Some authors believe that the efficacy of this drug is equal or more than antimonial compounds, but others disclaim this theory (3, 6, 7). Recently topical paromomycin, in the form of paromomycin 15% combined with methyl benzethonium chloride (MBCL) 12%, has appeared to be effective in cutaneous leishmaniasis (3, 8) specially on Old World types (*L. major* & *L. tropica*) (3); however, some authors believe that it is not as effective on other types (8, 9). Due to a high recurrence rate, this regimen was not accepted in most studies (10, 11). Max Groggl, et al found out that the combination of paromomycin 15% and gentamycin 0.5% was more effective with less recurrence rate near zero (12). In few patients, parenteral paromomycin in doses of 14-16 mg/kg caused renal or vestibular toxic side effects (6, 7, 13) which were not reported when a topical paromomycin was used; however, local irritation, hypersensitivity and pain were reported. Some authors mentioned that these side effects could be due to MBCL (9).

In this study the efficacy and side effects of topical paromomycin 20% alone and in combination with gentamycin 0.5% were assessed and the results were compared with intralesional injections of glucantime on cutaneous leishmaniasis in BALB/c mice.

Experimental

One hundred male BALB-c mice were purchased from Pasteur Institute and CinnaGen Inc. (Tehran, Iran). Promastigotes of *L. major* (MRho/IR/75/Nadim) were donated by the Faculty of Health in Tehran University of Medical Sciences. Paromomycin powder was purchased from Al-Havi Pharmaceutical Company. All of the drug preparations were produced in the Pharmaceutics Department of the Faculty of Pharmacy in Tehran University of Medical Sciences. Petrolatum was used as vehicle in topical preparation. Mice were kept in the Pharmacology Department of Faculty of Medicine's animal laboratory at Shaheed Beheshti University of Medical Sciences.

The hairs at the tail end of the back of the mice were clipped and about 5 million promastigotes of *L. major* were injected intradermally into the area. Almost 60 days later, those mice that had lesions with a diameter equal or greater than 2 millimeters were selected and divided into five equal groups with similar mean weights and matched according to their largest lesional diameters. Lesional diameter was measured by a translucent ruler. Each group was treated blindly for 20 days by one of these regimens:

- Group 1- ointment of paromomycin 20% and intralesional injection of placebo,
- Group 2- ointment of paromomycin 20%+ gentamycin 0.5% and intralesional injection of placebo,
- Group 3- the ointment base and intralesional injection of placebo (control group),
- Group 4- the ointment base and intralesional injection of glucantime (20-30 mg/kg) by diluting vials containing 6 mg/ml,
- Group 5- ointment of gentamycin 0.5% and intralesional injection of placebo.

All drug preparations were produced and packed separately and labeled as I to V. Researchers were not informed about the type of treatment in each group until the end of the data analysis. Ointments were applied twice a day and injections were made once every five days in all 5 groups by one of the researchers. The first day of treatment was defined as day 0. The weight and the largest lesional diameters (LLDs) of the mice were measured on day 2. Then, they were

assigned to a therapy group with matched weights and LLDs. The largest lesional diameters (LLD) were measured during the treatment period on days 0, 4, 8, 12, 16, 20 (the end of treatment), 25 and 30. No clinical side effects such as local irritation or hair loss were observed. On the day 30, the cured mice were selected and followed through for determination of the recurrence rates until the day 95 and LLDs were measured on days 40, 50, 60, 70, 80 and 90.

The data provided by this study was analyzed by ANOVA (post Hoc) and T tests using SPSS 11 software.

Results

A total of 60 infected male mice were assigned to the five treatment groups (12 mice in each group). The mean weight of each group was matched about 26 grams. The means of LLDs at the time of assignment in each group were: group 1 (5.9±2.99 mm), group 2 (5.8±2.59 mm), group 3 (6.0±2.05 mm), group 4 (6.1±1.88 mm) and group 5 (5.9±1.78 mm).

On the day 3, a mouse in group 5 (gentamycin) was lost for an unrelated reason and excluded from the study.

Primary results of the treatments

Mean LLD in each group on day 2 to 30 was calculated and displayed in Figure. 1. Lesions of the mice in groups 3 (placebo), 4 (glucantime) and 5 (gentamycin) not only did not respond to the therapy, but also enlarged continuously. LLDs of lesions in groups 1 (paromomycin) and 2 (paromomycin+gentamycin) decreased respectively due to the treatment but the response to paromomycin alone had an earlier onset. On day 8 the mean of LLD in group 1 (paromomycin 20% alone) decreased and was less than other groups ($p<0.05$). On day 12 the mean of LLD in group 2 (paromomycin 20%+gentamycin 0.5%) started to decrease and became less than groups 3 (control), 4 (glucantime) and 5 (gentamycin 0.5%) ($p<0.05$) but remained larger than group 1 ($p<0.05$). On day 16, the difference of LLDs between group 1 and 2 was subsided but the mean LLD in both groups were less than the others ($p<0.05$). On days 20, 25 and 30, no difference between group 1 and 2 was detected,

but the mean LLD difference between the mentioned groups and the others became more obvious by day 30, when all lesions in groups 1 and 2 were cured (24 mice). However, in all these days, the mean LLD in groups 3, 4 and 5 were increasing constantly and no mice in the mentioned groups (35 mice) were cured. During the treatment period, there were no statistical differences among the mean of LLDs in groups 3, 4 and 5, and on the day 30 the mean of LLDs in these groups were as follows: group 3:15.8±2.34 mm, Group 4:14.7±2.61 mm, group and 5: 15.9±2.21 mm.

Side effects

From the day 12 and onwards, some superficial lesions without indurations appeared in several mice in groups 1 and 2. These lesions were limited to the treated areas. Based on clinical appearance and subsequent resolution after end of the treatment, it was concluded that these lesions were due to contact dermatitis. Precise measurement of LLDs was partially interfered by these new and unrelated lesions. No other clinical side effects such as hair loss were seen in any of the groups.

Recurrence

Groups 1 and 2 were followed until day 95. The recurrence rate and the mean LLDs in the follow-up period are displayed in Figure. 2 and 3, respectively. On day 60, a mouse in group 1 died but had no lesions. Recurrent lesions were seen earlier and in larger numbers of mice in group 2 comparing to group 1 ($p<0.05$). The first recurrent lesion in group 2 was seen on day 40, but none was seen in group 1 until day 60. At the end of the study, recurrence was seen in just 3 of 11 mice in group 1 (27.27%) comparing to 9 cases out of 12 in group 2 (75%). In group 1, no new recurrent lesion was seen after day 70.

Discussion

Treatment of cutaneous leishmaniasis is a major therapeutic challenge. Various therapeutic regimens have been applied for different types of Leishmania to achieve maximum efficacy with minimum side effects (1, 3). No ideal therapy for cutaneous leishmaniasis has been identified yet.

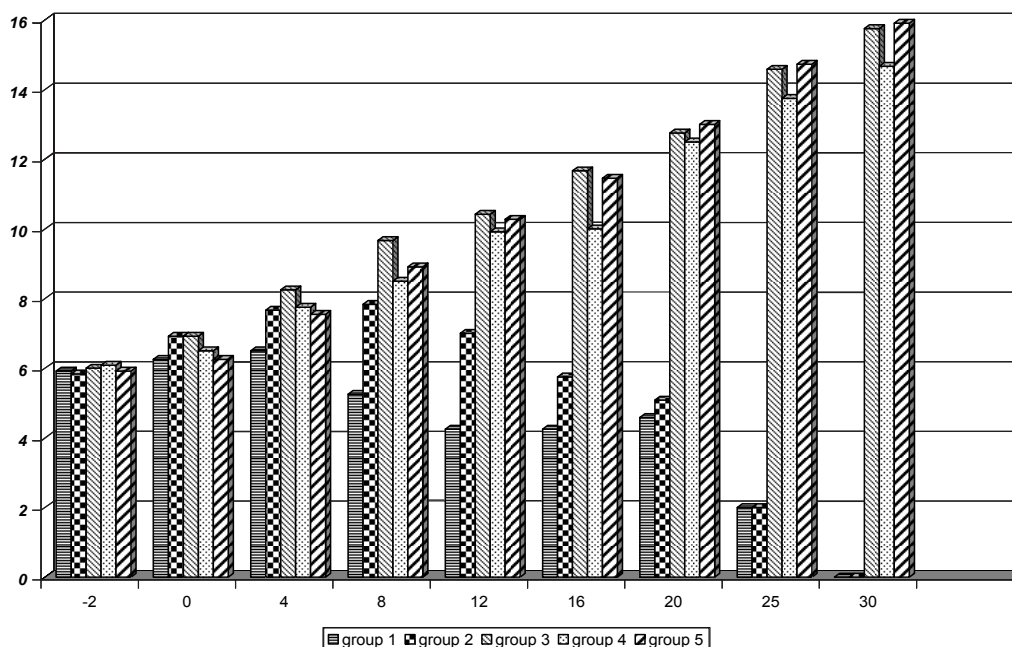


Figure 1. Mean of largest lesional diameters in different groups of mice with experimental cutaneous leishmaniasis from day -2 until day 30. The beginning day of treatment assigned as day 0.

- Group 1: treated with topical paromomycin 20%
- Group 2: treated with topical paromomycin 20%+ gentamycin 0.5%
- Group 3: treated with intralesional glucantime
- Group 4: treated with placebo
- Group 5: treated with topical gentamycin 0.5%

Pentavalent antimonial compounds are the first choice of therapy (1, 3), but local injection of these drugs is painful and not practical for patients with several lesions. Systemic administration of these drugs needs Hospital admission and monitoring for side effects. Among other drugs, the most efficient treatment for old world leishmaniasis is paromomycin; although the available data seems controversial.

Pascal del Giudice et al in 1998 had a case report of treating the cutaneous leishmaniasis due to *L. infantum* in one patient (a 9- month baby) with topical paromomycin without recurrence in a one month follow-up (2).

In 1998 G. Oliva et al studied the efficacy of meglumine antimoniate and aminosidine (parenteral) alone or in combination, in the treatment of the canine viscerocutaneous leishmaniasis due to *L. infantum* (14). They concluded aminosidine alone had a lower cure rate than meglumine antimoniate and that the combination of meglumine antimoniate with aminosidine would increase the cure rate of both drugs without any difference in their recurrence

rates.

In 2001 A P Fernandes et al studied the effects of combined interleukin-12 and topical paromomycin on experimental leishmaniasis in BALB-c mice (10). They administered a special o/w base paromomycin 5% for 12 days and they believed this preparation had at least, an equal effect as normal base paromomycin 15%. In all those treated with paromomycin (alone or in combination with interleukin-12), complete clinical cure was observed by day 30, but the ones treated with paromomycin alone had recurrent lesions on day 86 after the end of treatment. However, at the end of study (day 120) 50% of the mice with three injections of interleukin-12 and 25% with 6 injections of interleukin-12 had recurrent lesions. Interleukin-12 alone had no more effect than placebo. So it was deduced that paromomycin alone had an unacceptable recurrence rate, but when combined with interleukin-12 there was a reduction in the recurrence rate to an acceptable range. In our study, paromomycin 20% in a simple base was used for longer time (20 days); the same cure

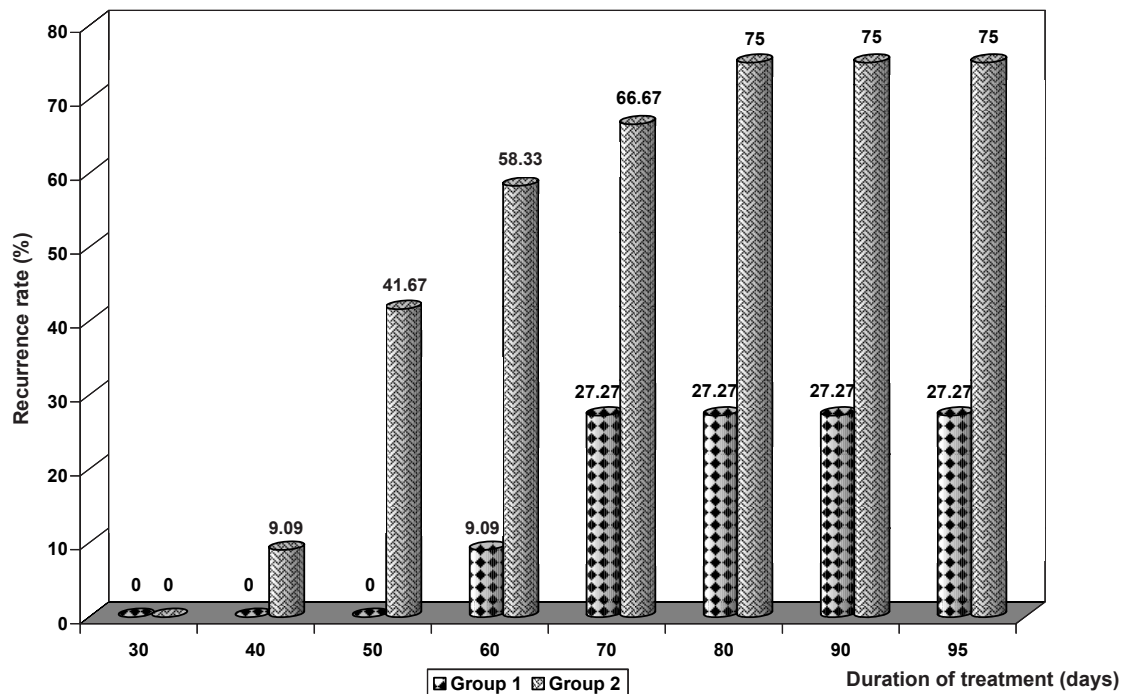


Figure 2. Title: Recurrence rate in groups 1 and 2* of mice with experimental cutaneous leishmaniasis from day 30 until day 95. The beginning day of treatment assigned as day 0.

Group 1: treated with topical paromomycin 20%

Group 2: treated with topical paromomycin 20%+ gentamycin 0.5%

rate with a less recurrence rate (less than 28% in our study versus more than 50% in theirs on day 95) was obtained. Furthermore, their recommended therapy needs several perilesional injections (like glucantime) which are very expensive as the first line of therapy especially for developing countries. This regimen is usually not recommended for these countries except for the resistant cases.

T K Jha et al in 1998 compared aminosidine and sodium stibogluconate for treating visceral leishmaniasis in North Bihar, India (6). They treated 120 patients either with parenteral aminosidine at three different dosages or with sodium stibogluconate 20 mg/kg/day for 30 days and followed them up for 180 days. The cure rate without any recurrence at the end of follow up period in patients treated with 12, 16 and 20 mg/kg aminosidine were 77%, 93% and 97% respectively, and in patients treated with glucantime was 63% while no side-effects were seen in any groups. Thus, it was concluded that aminosidine could be the first drug of choice in visceral leishmaniasis in India.

Max Grogl et al have had a successful topical treatment of murine cutaneous leishmaniasis with a combination of paromomycin (aminosidine) and gentamycin in 1999 (12). They treated male BALB-c mice with induced leishmaniasis by different drug regimens according to the different types of *Leishmania*. In a study, the effect of a ten day therapy with a combination of paromomycin 15% and methylbenzethonium chloride (MBCL) 12% was compared with a combination of paromomycin 15% and gentamycin 0.5%. They achieved complete clinical cure with the combination of paromomycin and gentamycin (100%) as opposed to the other group (60%). At the end of the study (70 days after the end of the therapy) no recurrence in the group treated with paromomycin plus gentamycin was detected while 90% of the mice in the other group had recurrent lesions. It was concluded that the combination of paromomycin and gentamycin enhanced their anti-leishmanial activity; however, our results were exactly opposite. Although we used paromomycin 20% in a different base, it seems that it cannot cause much difference and

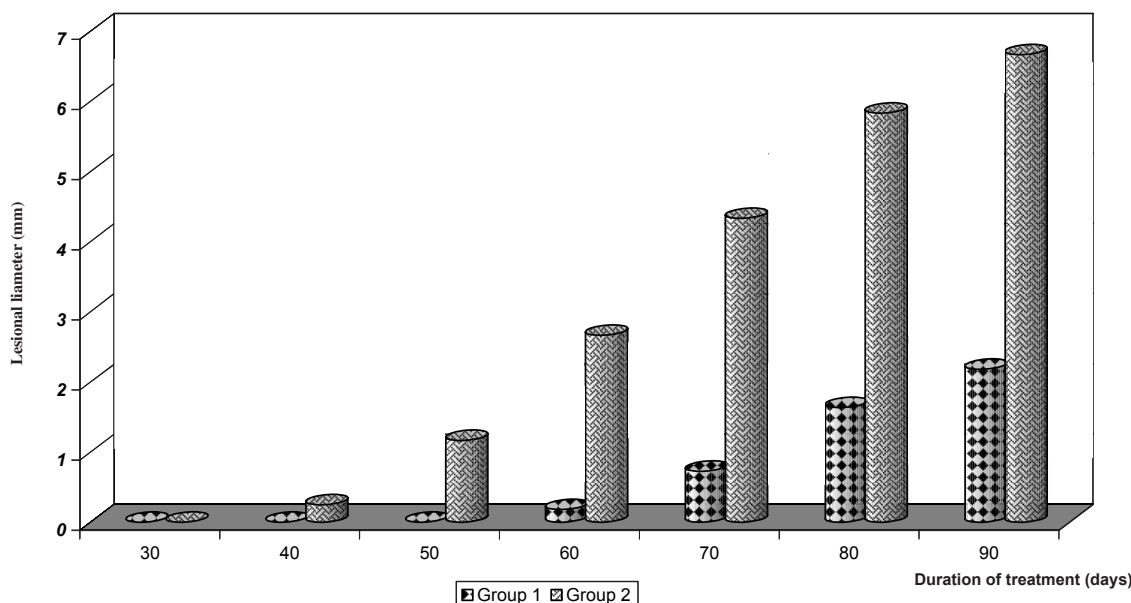


Figure 3. Title: Mean of largest lesional diameters in groups 1 and 2* of mice with experimental cutaneous leishmaniasis from day 30 until day 90. The beginning day of treatment assigned as day 0
 *Group 1: treated with topical paromomycin 20%
 Group 2: treated with topical paromomycin 20%+ gentamycin 0.5%

further investigations are necessary to find out the possible causes.

In our study, we achieved a high cure rate and an acceptable recurrence rate by paromomycin 20% in BALB-c mice with cutaneous leishmaniasis due to *L. major*. Adding gentamycin 0.5% to paromomycin 20% delayed its action and increased the recurrence rate. Neither local injection of glucantime nor topical gentamycin 0.5% ointment was effective. In the case of glucantime, the results were unexpected and might be due to the following reasons:

1- BALB-c mice have inherited immune-deficiency and have been more vulnerable to chronic leishmaniasis; furthermore, as mentioned in other studies, glucantime can not completely cure leishmaniasis in BALB-c mice (4).

2- In this study we used diluted glucantime (6 mg/ml) based on mouse weight and an accepted non-toxic dosage in human (20 mg/kg) (1, 3) that might have lower therapeutic effect. In other reports that had better results with glucantime in BALB-c mice used higher doses (up to 200 mg/kg) were used without monitoring or reporting any cardiac or other side effects (4).

Among other drugs used for leishmaniasis, just amphotericin B has a promising efficacy

for treating visceral leishmaniasis, (1, 3) but due to the high incidence of its side-effects and toxicity, this drug has no place in the treatment of cutaneous leishmaniasis.

Previous articles mentioned that contact dermatitis which was seen when topical paromomycin/methyl benzethonium chloride (MBCL) combination was used, may caused by the latter compound (9). However, in our study paromomycin 20% in simple base without MBCL produced contact dermatitis as well.

According to the current information and our results, we may conclude that topical paromomycin 20% can be the first drug of choice for the treatment of old world cutaneous leishmaniasis due to a more convenient application than antimonial compounds and also lack of side effects. More studies are currently undergoing on the effect of this regimen on human leishmaniasis.

References

- (1) Davidson RN. Practical guide for the treatment of leishmaniasis. *Drugs* (1998) 56: 1009-1018
- (2) Giudice P, Marty P, Lacour JP, Perrin CH, Pralong F, Haas H, Dellamonica P and Fichoux Y. Cutaneous leishmaniasis due to *Leishmania infantum*. *Arch.*

- Dermatol.* (1998) 134: 193-198
- (3) Balana-Fouce R, Reguera RM, Cubria JC and Ordonez D. The pharmacology of leishmaniasis. *Gen. Pharmac.* (1998) 30: 435-443
- (4) Gangneux J-P, Sulahian A, Garin Y J-F, Deruin F. Efficacy of aminosidine administered alone or in combination with meglumine antimoniate for the treatment of experimental visceral leishmaniasis caused by *Leishmania infantum*. *J. Antimicrob. Chemother.* (1997) 40: 287-289
- (5) Maarouf M, Lawrence F, Brown S and Robert-Gero M. Biochemical alteration in paromomycin-treated *Leishmania donovani* promastigotes. *Parasitol. Res.* (1997) 83: 198-202
- (6) Jha TK, Olliaro P, Thakur CPN, Kanyok TP, Singhania BL, Singh IJ, Singh NKP, Akhour SY and Jha S. Randomized controlled trial of aminosidine (paromomycin) V sodium stibogluconate for treating visceral Leishmaniasis in north Bihar, India. *B. M. J.* (1998) 316: 1200-1205
- (7) Vexenat JA, Olliaro PL, Fonseca de Castro JA, Cavalcante R, Furtado Campos JH, Tavares JP and Miles MA. Clinical recovery and limited cure in canine visceral leishmaniasis treated with aminosidine (paromomycin). *Am. J. Trop. Med. Hyg.* (1998) 58: 448-453
- (8) Ozgoztasi O and Baydar I. A randomized clinical trial of topical paromomycin versus oral ketoconazole for treating cutaneous leishmaniasis in Turkey. *Int. J. Dermatol.* (1997) 36: 61-63
- (9) Neva FA, Ponce C, Ponce E, Kreutzer R, Modabber F and Olliaro P. Non-ulcerative cutaneous leishmaniasis in Honduras fails to respond to topical paromomycin. *Trans R. Soc. Trop. Med. Hyg.* (1997) 91: 473-475
- (10) Fernandes AP, Carvalho FAA, Tavares CAP, Santiago HC, Castro GA, Tafuri WL, Ferreira LAM and Gazzinelli RT. Combined Interleukin-12 and topical chemotherapy for established leishmaniasis drastically reduces tissue parasitism and relapse in susceptible mice. *J. Infect. Dis.* (2001) 183: 1646-1652
- (11) Soto J, Fuya P, Herrera R and J Berman. Topical paromomycin/methylbenzethonium chloride plus parenteral meglumine antimoniate as treatment for American cutaneous leishmaniasis, controlled study. *Clin. Infect. Dis.* (1998) 26: 56-58
- (12) Grogl M, Schuster BG, Ellis WY and Berman JD. Successful topical treatment of marine cutaneous leishmaniasis with combination of paromomycin (aminosidine) and gentamycin. *J. Parasitol.* (1999) 85: 354-359
- (13) Kanyok TP, Killian AD, Rodvold KA and Danziger LH. Pharmacokinetics of intramuscularly administered aminosidine in healthy subjects. *Antimicrob. Agents Chemother.* (1997) 41 (5): 982-986
- (14) Oliva G, Gradoni L, Cortese L, Orsini S, Ciaramella P, Scalone A, Luna R and Persechino A. Comparative efficacy of meglumine antimoniate and aminosidine sulfate, alone or in combination, in canine leishmaniasis. *Ann. Trop. Med. Parasitol.* (1998) 92: 165-1671
- (15) Maarouf M, Kouchkovsky Y, Brown S, Xavier Petit P and Robert -Gero M. *In vivo* interference of paromomycin with mitochondrial activity of leishmania. *Exp. Cell Res.* (1997) 232: 339-348
-
- This article is available online at <http://www.ijpr-online.com>