



Coil Embolization of a Pseudoaneurysm of the Petrous Internal Carotid Artery Presenting with Otorrhagia: A Case Report and Review of the Literature

Ahmad Hosseinzadeh^{1,2}, AliReza Rasekhi³, Afshin Borhani-Haghighi⁴, Majid Asnaashari^{1,2}, Saeed Abdollahifard^{5,6,*} and Seyed Arman Moein^{2,6}

¹Department of Vascular Surgery, Shiraz University of Medical Sciences, Shiraz, Iran

²Thoracic and Vascular Surgery Research Center, Shiraz University of Medical Sciences, Shiraz, Iran

³Department of Radiology, Shiraz University of Medical Sciences, Shiraz, Iran

⁴Clinical Neurology Research Center, Shiraz University of Medical Sciences, Shiraz, Iran

⁵Research Center for Neuromodulation and Pain, Shiraz, Iran

⁶Student Research Committee, Shiraz University of Medical Sciences, Shiraz, Iran

*Corresponding author: Research Center for Neuromodulation and Pain, Shiraz, Iran. Email: saeed_abdf@hotmail.com

Received 2021 September 02; Revised 2022 March 22; Accepted 2022 March 29.

Abstract

Introduction: Otorrhagia is not a common manifestation of petrous internal carotid artery (ICA) aneurysm. Besides idiopathic cases, different etiologies, including trauma, infection, and radiation, have been suggested for petrous ICA aneurysms/pseudoaneurysms. However, there is limited experience in the management of this rare aneurysm/pseudoaneurysm with coil embolization.

Case Presentation: A 58-year-old man, who was a known case of chronic otitis media, was referred from the otorhinolaryngology ward with intractable bleeding from the right ear. A pseudoaneurysmal lesion (7 mm × 5 mm) was detected in the petrous segment of the internal carotid artery. The patient underwent coil embolization with no complications.

Conclusion: To the best of our knowledge, this is the first case of petrous ICA pseudoaneurysm, presenting with only intractable otorrhagia. The patient was successfully treated with coil embolization, with no need for further interventions. Besides, a review of petrous ICA aneurysms or pseudoaneurysms presenting with otorrhagia was performed.

Keywords: Interpetrosal Internal Carotid Artery Pseudoaneurysm, Coil Embolization, Endovascular Treatment, Otorrhagia

1. Introduction

Intractable otorrhagia, as a solitary symptom, is not a common manifestation of petrous internal carotid artery (ICA) aneurysms and pseudoaneurysms. Besides idiopathic cases, various etiologies, such as trauma, infection, and radiation, have been suggested for petrous ICA aneurysms. Secured by the petrous bone, these aneurysms are challenging targets for open surgery, making endovascular approaches an advantageous treatment for these cases (1, 2). Considering the variety of endovascular options, such as stenting and coil embolization, besides the rarity of this condition, herein, we report a case of petrous ICA pseudoaneurysm presenting with only otorrhagia, who was treated by coil embolization. Moreover, a review of petrous ICA aneurysms and pseudoaneurysms presenting with otorrhagia was conducted.

2. Case Presentation

A 58-year-old man, who was a known case of chronic otitis media, was referred from the otorhinolaryngology ward with intractable bleeding from the right ear. He had a history of tympanoplasty and mastoidectomy due to chronic otitis media 23 years ago. Although he never mentioned otorrhagia in his medical history, he had experienced severe hearing loss and episodes of otorrhea since the operation. After hemodynamic stabilization, a computed tomography (CT) angiogram of the head and neck was requested for the patient, which was highly suspicious of a pseudoaneurysmal lesion of the right ICA. Considering the possible location of the ICA lesion, the patient underwent conventional angiography, which indicated a 7 × 5 mm pseudoaneurysm in the right petrous ICA and confirmed our previous findings.

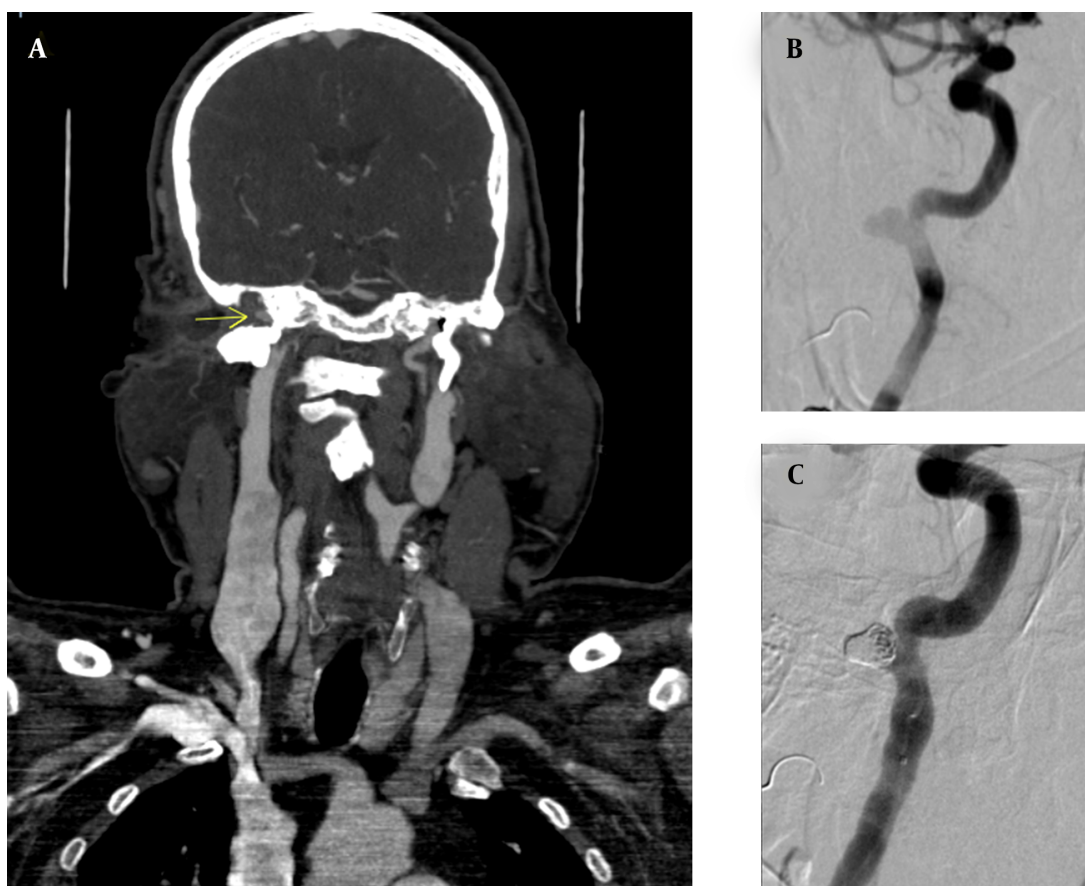


Figure 1. Pre- and post-treatment images of pseudoaneurysm. (A) CT angiography of the head and neck, indicating a petrous internal carotid artery pseudoaneurysm; (B) Conventional angiography, indicating a pseudoaneurysm; (C) Conventional angiography indicating the obliteration of pseudoaneurysm.

Femoral artery access was replaced with a 7F vascular access sheath (Accura Systems Inc., USA). Using a 7F Conciere GE guiding catheter (Merit Medical Systems, Inc., USA), an Echelon-14 microcatheter (Ev3 Inc., USA) was inserted into the pseudoaneurysm by a SilverSpeed-10 microguidewire (Ev3 Inc., USA). The pseudoaneurysm was packed with an Axium Prime 3D coil (6 mm × 20 cm; eV3 Inc., USA) and Axium Prime helical coil (6 mm × 20 cm; eV3, Inc.), with no complications. At the time of this procedure, no flow diverter stent was available in our center. After the procedure, a final angiography of the right ICA was performed, revealing normal blood flow through the ICA, with obliteration of pseudoaneurysm. The patient visited the center twice in the past year, and no signs of aneurysm recurrence, otorrhagia, or other symptoms were found (Figure 1).

3. Discussion

Massive otorrhagia has limited differential diagnoses, such as glomus tumors and vascular lesions, including uncovered jugular bulbs, ICA aneurysmal lesions, hemangioma, and arteriovenous malformations (3, 4). Although few of these differential diagnoses, such as glomus tumors, may appear the same as petrous ICA on physical examination, a CT angiography of the head and neck can provide a definite diagnosis (4). Nearly 40% of aneurysms in the human body originate from the internal carotid artery; however, different parts of this artery are not similarly involved in aneurysm formation (5). Petrous ICA is less affected by aneurysms compared to other intracranial arteries (6). Infection and trauma are among the main etiologies for aneurysm formation (7, 8).

In a systematic review investigating the manifestations of petrous ICA aneurysms, the most common manifesta-

Table 1. A Review of Cases Similar to the Present Case

Authors	Year	Age	Sex	Symptoms	Etiology	Treatment
Anderson et al. (15)	1972	19	Female	Otorrhagia	Idiopathic	Occlusion with a metallic clip
Holtzman and Parisier (13)	1979	35	Male	Otorrhagia; Hearing loss	Congenital/ infection without a known origin	Common carotid artery ligation and; transection
Chiappetta et al. (17)	1983	60	Man	Otorrhagia	Infection	Common carotid artery ligation
Forshaw et al. (4)	2000	20	n/a	Otorrhagia; Hearing loss; Tinnitus	Idiopathic	Balloon occlusion
Cheng et al. (16)	2001	35	Male	Otorrhagia;	Radiation-induced	Stenting
Oyama et al. (12)	2010	60	Male	Otorrhagia;	Chronic otitis media	Coil embolization, proximal ICA ligation, and EC bypass
Mascitelli et al. (11)	2015	Middle aged	n/a	Otorrhagia; Hearing loss	Chronic otitis media	Stenting
Nemeth et al. (10)	2017	68	Female	Otorrhagia; Otorrhea; Otagia	Malignant otitis externa	Stenting
Akhtar et al. (14)	2017	13	Male	Otorrhagia;	Congenital	Superficial temporal artery/middle cerebral artery bypass
Yu et al. (1)	2018	58	Male	Otorrhagia;	Iatrogenic	Extracranial-intracranial (EC-IC) bypass with ICA occlusion

tions were cranial nerve palsy for primary aneurysms and bleeding for secondary aneurysms (2). The present case was an aneurysm of petrous ICA, which only presented with intractable otorrhagia, possibly originating from chronic otitis media. The angiography of ICA confirmed the diagnosis of an aneurysmal lesion in the petrous segment of ICA. Since access to this area of the head and neck is challenging, and serious complications may occur during surgery, open surgery is not the primary intervention (9). Today, minimally invasive endovascular techniques, such as coil embolization and stenting, have replaced open surgery (1).

In this study, we also conducted an extensive literature review in the NCBI database for petrous ICA aneurysms and pseudoaneurysms, presenting with massive bleeding from the ears. A total of 10 similar cases were found in 10 articles, as summarized in Table 1. The etiology of aneurysm was infection in four cases (10-12), congenital in two cases (13, 14), idiopathic in two cases (4, 15), radiation-induced in one case (16), and iatrogenic in one case (1). Only three out of 10 cases reported coil embolization. Moreover, Yu et al. used coil embolization for the treatment of petrous ICA aneurysms; nevertheless, nine years after this procedure, the patient presented to the hospital with hematoma and recurrence of otorrhagia. The coil wire had ruptured the aneurysmal lesion, and an iatrogenic pseudoaneurysm was formed. The patient was sent to the operating room, and after removing the coil, extracranial-intracranial bypass was performed, and ICA was occluded (1).

Mascitelli et al. reported a case of mycotic aneurysm of petrous ICA, for whom coil embolization was carried out. However, 12 days after coil embolization, the episodes of otorrhagia were repeated, and stent insertion was performed as the final treatment (11). Additionally, Oyama et al. performed coil embolization, proximal ICA ligation, and external carotid bypass for a patient with a petrous ICA pseudoaneurysm and a history of chronic otitis media, without any complications (12). To the best of our knowledge, this was the first case of petrous ICA pseudoaneurysm, presenting with only otorrhagia, who was treated with coil embolization without any complications. We managed to obliterate the petrosal pseudoaneurysmal sac by coil embolization, with no damage to the main blood flow in ICA and no further need for a bypass.

Based on the present findings, physicians should consider petrous ICA aneurysms and pseudoaneurysms as lethal differential diagnoses after finding no apparent cause for intractable ear bleeding. Besides, CT angiography of the head and neck and confirmatory angiography of ICA can rule out other differential diagnoses. Although some studies have reported complications arising from coil embolization, by using a proper technique, coil embolization can be a less invasive and lifesaving treatment option for the management of petrous ICA pseudoaneurysms. Therefore, coil embolization of a narrowneck petrous ICA pseudoaneurysm can be a safe and suitable treatment option for this type of pseudoaneurysm.

Footnotes

Authors' Contributions: HA, RA, BA, and AM contributed to the conception of this study. AS and MSA wrote the first draft of the manuscript, and HA, RA, BA, and AM finalized the work.

Conflict of Interests: There is no conflict of interest to be declared.

Data Reproducibility: No new data were created or analyzed in this study. Data sharing does not apply to this article.

Funding/Support: This research received no specific grant from any funding agency in the public, commercial, or not-for-profit sectors.

Informed Consent: Informed consent was obtained from the patient for publication of this case report and accompanying images.

References

1. Yu LB, Zhang D, Yang SH, Zhao JZ. Surgical management of giant intrapetrous internal carotid aneurysm presenting with coil exposure after endovascular treatment. *Neurosurg Rev.* 2018;**41**(3):891-4. doi: [10.1007/s10143-018-0964-y](https://doi.org/10.1007/s10143-018-0964-y). [PubMed: [29572579](https://pubmed.ncbi.nlm.nih.gov/29572579/)].
2. Murai Y, Shirokane K, Kitamura T, Tateyama K, Matano F, Mizunari T, et al. Petrous Internal Carotid Artery Aneurysm: A Systematic Review. *J Nippon Med Sch.* 2020;**87**(4):172-83. doi: [10.1272/jnms.JNMS.2020_87-407](https://doi.org/10.1272/jnms.JNMS.2020_87-407). [PubMed: [32238731](https://pubmed.ncbi.nlm.nih.gov/32238731/)].
3. Petri M, Dinescu V, Necula V, Cosgarea M. Otorrhagia as the initial presentation of an internal carotid artery aneurysm in the middle ear. Case presentation. *Clujul Med.* 2016;**89**(2):297-300. doi: [10.15386/cjmed-528](https://doi.org/10.15386/cjmed-528). [PubMed: [27152084](https://pubmed.ncbi.nlm.nih.gov/27152084/)]. [PubMed Central: [PMC4849391](https://pubmed.ncbi.nlm.nih.gov/PMC4849391/)].
4. Forshaw MA, Higgins N, Hardy DG, Moffat DA. Rupture of an internal carotid artery aneurysm in the petrous temporal bone. *Br J Neurosurg.* 2000;**14**(5):479-82. doi: [10.1080/02688690050175355](https://doi.org/10.1080/02688690050175355). [PubMed: [11198777](https://pubmed.ncbi.nlm.nih.gov/11198777/)].
5. Wang Y, Guan B, Tian T, Peng X, Xu LI. Intrapetrous internal carotid artery aneurysm diagnosed on the basis of middle ear effusion: A case report. *Oncol Lett.* 2015;**10**(1):283-6. doi: [10.3892/ol.2015.3178](https://doi.org/10.3892/ol.2015.3178). [PubMed: [26171015](https://pubmed.ncbi.nlm.nih.gov/26171015/)]. [PubMed Central: [PMC4487174](https://pubmed.ncbi.nlm.nih.gov/PMC4487174/)].
6. Benoit BG, Wortzman G. Traumatic cerebral aneurysms. Clinical features and natural history. *J Neurol Neurosurg Psychiatry.* 1973;**36**(1):127-38. doi: [10.1136/jnnp.36.1.127](https://doi.org/10.1136/jnnp.36.1.127). [PubMed: [4691685](https://pubmed.ncbi.nlm.nih.gov/4691685/)]. [PubMed Central: [PMC494287](https://pubmed.ncbi.nlm.nih.gov/PMC494287/)].
7. Ho CL, Lam JHH, McAdory LE. Carotid Mycotic Aneurysm associated with Persistent Primitive Hypoglossal Artery. Case Report and Literature Review. *J Radiol Case Rep.* 2019;**13**(3):1-7. doi: [10.3941/jrcr.v13i3.3588](https://doi.org/10.3941/jrcr.v13i3.3588). [PubMed: [31565171](https://pubmed.ncbi.nlm.nih.gov/31565171/)]. [PubMed Central: [PMC6743856](https://pubmed.ncbi.nlm.nih.gov/PMC6743856/)].
8. Spanos K, Karathanos C, Stamoulis K, Giannoukas AD. Endovascular treatment of traumatic internal carotid artery pseudoaneurysm. *Injury.* 2016;**47**(2):307-12. doi: [10.1016/j.injury.2015.09.015](https://doi.org/10.1016/j.injury.2015.09.015). [PubMed: [26453153](https://pubmed.ncbi.nlm.nih.gov/26453153/)].
9. Moonis G, Hwang CJ, Ahmed T, Weigle JB, Hurst RW. Otologic manifestations of petrous carotid aneurysms. *AJNR Am J Neuroradiol.* 2005;**26**(6):1324-7. [PubMed: [15956490](https://pubmed.ncbi.nlm.nih.gov/15956490/)]. [PubMed Central: [PMC8149044](https://pubmed.ncbi.nlm.nih.gov/PMC8149044/)].
10. Nemeth T, Szakacs L, Bella Z, Majoros V, Barzo P, Voros E. The treatment of pseudoaneurysms with flow diverters after malignant otitis externa. *Interv Neuroradiol.* 2017;**23**(6):609-13. doi: [10.1177/1591019917729804](https://doi.org/10.1177/1591019917729804). [PubMed: [28992722](https://pubmed.ncbi.nlm.nih.gov/28992722/)]. [PubMed Central: [PMC5814079](https://pubmed.ncbi.nlm.nih.gov/PMC5814079/)].
11. Mascitelli JR, De Leacy RA, Oermann EK, Skovrlj B, Smouha EE, Ellozy SH, et al. Cervical-petrous internal carotid artery pseudoaneurysm presenting with otorrhagia treated with endovascular techniques. *J Neurointerv Surg.* 2015;**7**(7). e25. doi: [10.1136/neurintsurg-2014-011286.rep](https://doi.org/10.1136/neurintsurg-2014-011286.rep). [PubMed: [24996434](https://pubmed.ncbi.nlm.nih.gov/24996434/)].
12. Oyama H, Hattori K, Tanahashi S, Kito A, Maki H, Tanahashi K. Ruptured pseudoaneurysm of the petrous internal carotid artery caused by chronic otitis media. *Neurol Med Chir (Tokyo).* 2010;**50**(7):578-80. doi: [10.2176/nmc.50.578](https://doi.org/10.2176/nmc.50.578). [PubMed: [24996434](https://pubmed.ncbi.nlm.nih.gov/24996434/)].
13. Holtzman RN, Parisier SC. Acute spontaneous otorrhagia resulting from a ruptured petrous carotid aneurysm. Case report. *J Neurosurg.* 1979;**51**(2):258-61. doi: [10.3171/jns.1979.51.2.0258](https://doi.org/10.3171/jns.1979.51.2.0258). [PubMed: [448437](https://pubmed.ncbi.nlm.nih.gov/448437/)].
14. Akhtar MU, Akram M, Ahmed TM, Bhatti AM. Superficial temporal artery-middle cerebral artery bypass for internal carotid artery petrous aneurysm: A case report. *J Pak Med Assoc.* 2017;**67**(1):128-30.
15. Anderson RD, Liebeskind A, Schechter MM, Zingesser LH. Aneurysms of the internal carotid artery in the carotid canal of the petrous temporal bone. *Radiology.* 1972;**102**(3):639-42. doi: [10.1148/102.3.639](https://doi.org/10.1148/102.3.639). [PubMed: [4334043](https://pubmed.ncbi.nlm.nih.gov/4334043/)].
16. Cheng KM, Chan CM, Cheung YL, Chiu HM, Tang KW, Law CK. Endovascular treatment of radiation-induced petrous internal carotid artery aneurysm presenting with acute haemorrhage. A report of two cases. *Acta Neurochir (Wien).* 2001;**143**(4):351-5. discussion 355-6. doi: [10.1007/s007010170089](https://doi.org/10.1007/s007010170089). [PubMed: [11437288](https://pubmed.ncbi.nlm.nih.gov/11437288/)].
17. Chiappetta F, Vangelista S, Pirrone R. Recurrent massive otorrhagia caused by a petrous carotid aneurysm. *J Neurosurg Sci.* 1982;**26**(3):205-7. [PubMed: [7182441](https://pubmed.ncbi.nlm.nih.gov/7182441/)].