



Intraosseous Neurofibroma and Concurrent Involvement of the Mandible, Maxilla and Orbit: Report of a Case

Zahra Dalili^{1*}, Gholamhossein Adham²

¹ Department of Maxillofacial Radiology, Dental School, Guilan University of Medical Sciences, Rasht, Iran

² Department of Maxillofacial Surgery, Dental School, Guilan University Of Medical Sciences, Rasht, Iran

ARTICLE INFO

Article type:
Case Report

Article history:
Received: 27 Dec 2010
Revised: 20 Nov 2011
Accepted: 21 Dec 2011

Keywords:
Neurofibroma
S100 Proteins
Magnetic Resonance Imaging
Cone-Beam Computed Tomography

ABSTRACT

Neurofibroma is an autosomal dominant disorder which has major criteria such as hyperpigmentation (cafe-au lait spots), cutaneous and subcutaneous tumors and bone deformities. In this report, a case of multifocal intraosseous neurofibroma in a 16-year-old male with right facial asymmetry, multiple unerupted maxillary posterior teeth and a previous history of infratemporal and orbital neurofibroma is presented. The majority of reported cases occurred in the posterior portion of the mandible and a limited number in the maxilla. Cone beam CT (CBCT) was performed for better evaluation of the extension and form of the maxillary and mandibular lesions. This report presents a rare situation of simultaneous peripheral neurofibromatosis (NF) and multifocal intraosseous NF in the mandible, maxilla and orbits and also focuses on advanced imaging findings of bony and soft tissue neurofibroma.

Published by Kowsar Corp. All rights reserved.

► Implication for health policy/practice/research/medical education:

This report focuses on advanced imaging findings of a rare case of neurofibroma. An interesting finding in this presentation is the concurrent involvement of multiple facial structures. It could be effective in the education of medical and dental students.

► Please cite this paper as:

Dalili Z, Adham Gh. Intraosseous Neurofibroma and Concurrent Involvement of the Mandible, Maxilla and Orbit: Report of a Case. *Iran J Radiol.* 2012;9(1):45-9. DOI: 10.5812/iranjradiol.6684

1. Introduction

Neurofibroma (NF) is an autosomal dominant disorder in 50 percent of cases and in the other fifty percent, there is no negative familial trait. This group has the highest mutation rate among genetic diseases (1, 2).

The two major classifications are NF-1, a generalized form, and NF-2, a central form(3).The major location of NF is the posterior portion of the mandible. A few cases have been presented in the maxilla (1). Females are involved more than males (4). Hyperpigmentation (cafe-au-lait spots) and cutaneous or subcutaneous tumors are

observed in the majority of the patients (5).

More common radiographic findings of the jaw bones are enlargement of the mandibular foramen and the inferior alveolar canal, an elongated coronoid process, a deep sigmoid notch, unerupted teeth and a cystic lesion. Neurofibroma of the orbit as an isolated entity (6) and also associated with systemic involvement (7) is also reported.

More than 40 cases of solitary neurofibroma have been reported until 2006 (1). The majority of them occurred in the posterior portion of the mandible and a limited number in the maxilla. In this article, we report a case of neurofibroma with concurrent unilateral involvement of the maxilla, mandible, orbit and infratemporal fossa. Besides, the CBCT features of this lesion in the maxilla and the mandible, magnetic resonance imaging (MRI) findings of the lesion in the infratemporal fossa and CT findings of the orbits have been discussed. This report

* Corresponding author: Zahra Dalili, Department of Maxillofacial Radiology, Dental School, Imam St., P O Box: 41887-94755, Rasht, Iran. Tel: +98-1313230775, Fax: +98-1313230776, E-mail: Dalili@gums.ac.ir

DOI: 10.5812/iranjradiol.6684

Copyright © 2012, Iranian Society of Radiology and Tehran University of Medical Sciences. Published by Kowsar Corp. All rights reserved.

has focused on advanced imaging findings of this lesion, their importance in the diagnosis and occurrence of the peripheral lesion accompanied by a rare form of multifocal intraosseous neurofibroma.

2. Case Presentation

The patient, a 16-year-old male, was referred with right facial asymmetry and multiple unerupted maxillary pos-

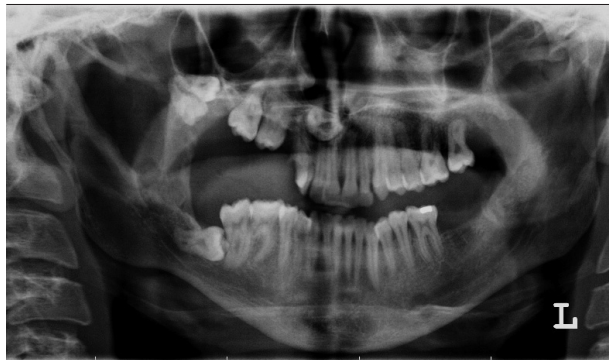terior teeth. There was no history of pain. The palatal enlargement was observed on the right side of the maxilla. The overlying soft tissue on the palatal side of the right posterior portion of the maxilla was soft and fluctuant without gingival ulceration and inflammation. In clinical examination, several cutaneous nodular masses and hyperpigmentations were observed. Periauricular soft tissue swelling on the left side with extension to the posterior portion of the auricle and also external auditory meatus were observed. Hypoglobus and proptosis of the left eye were detected.

In the panoramic view, a deep sigmoid notch, an elongated left coronoid process and separated pericoronar radiolucency were found. Impaction of the right maxillary molar teeth and destruction of the overlying bone were also observed (Figure 1).

CBCT was carried out for better evaluation of the extension and form of the maxillary and mandibular lesions (Figure 2 and 3). Axial views from the mid portion of the ramus to the level of the maxillary sinus revealed large pericoronar mass on the right side of the maxilla from the right maxillary canine to the tuberosity area with extension to the posterior portion of the right maxillary sinus and push the lateral and posterior wall of the right maxillary sinus to the antral cavity.

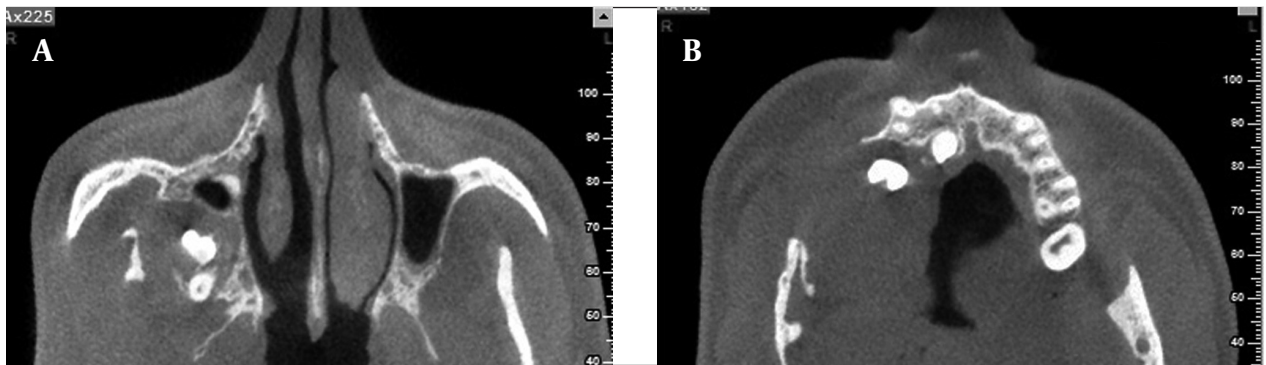
Deformity of the zygomatic bone and lateral bowing and thinning of the ramus were observed. Due to preau-

Figure 1. A 16-year-old male presenting with maxillary, mandibular and orbital neurofibroma



Panoramic view shows multiple tooth impactions, bone loss on the right side of the maxilla and elevation of the antral floor without a gross well-defined lesion. In the mandible, an elongated condylar neck and coronoid process, deep sigmoid notch, and oval lucency in the upper portion of the mandibular ramus are observed.

Figure 2. CBCT findings



A and B, Axial CBCT views indicate impacted teeth, mass effect on the posterior and lateral walls of the right maxillary sinus toward the antral cavity and involvement of the mandibular ramus.

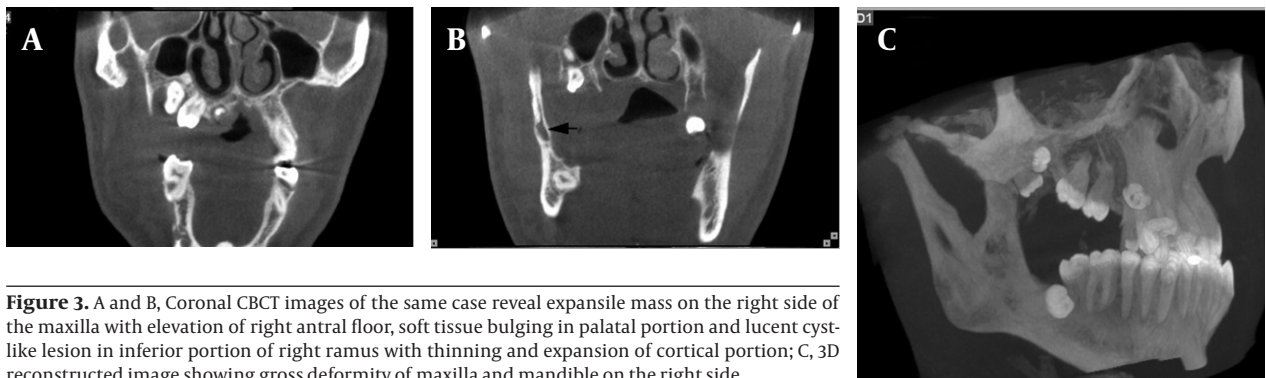
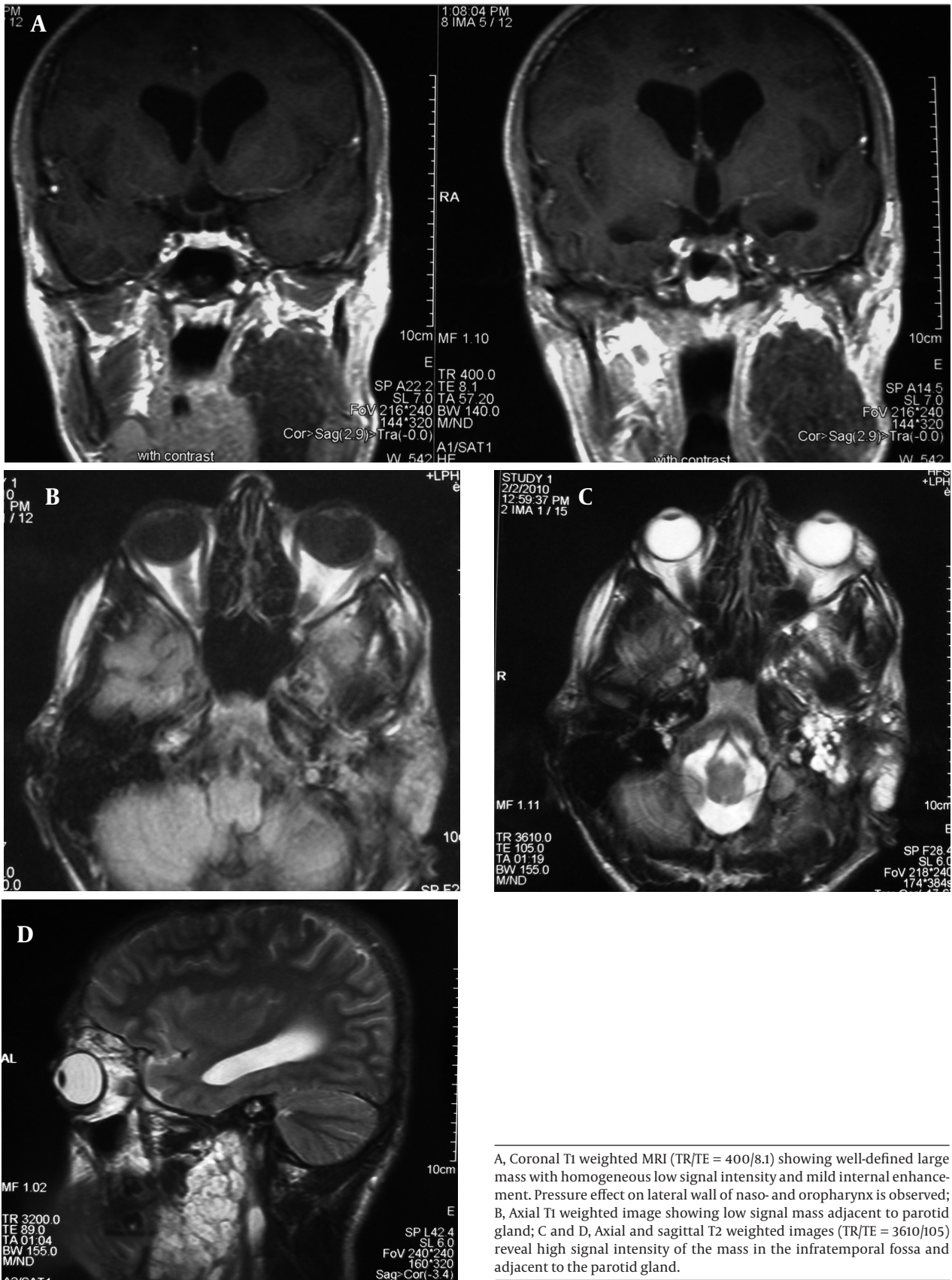


Figure 3. A and B, Coronal CBCT images of the same case reveal expansile mass on the right side of the maxilla with elevation of right antral floor, soft tissue bulging in palatal portion and lucent cyst-like lesion in inferior portion of right ramus with thinning and expansion of cortical portion; C, 3D reconstructed image showing gross deformity of maxilla and mandible on the right side.

Figure 4. MRI findings of the infratemporal mass



A, Coronal T1 weighted MRI (TR/TE = 400/8.1) showing well-defined large mass with homogeneous low signal intensity and mild internal enhancement. Pressure effect on lateral wall of naso- and oropharynx is observed; B, Axial T1 weighted image showing low signal mass adjacent to parotid gland; C and D, Axial and sagittal T2 weighted images (TR/TE = 3610/105) reveal high signal intensity of the mass in the infratemporal fossa and adjacent to the parotid gland.

ricular soft tissue swelling and a previous history of soft tissue mass in the left infratemporal fossa, MRI was performed for re-evaluation of the left infratemporal fossa. In MRI, a huge sized tumor was seen adjacent to the parotid gland which involved the infratemporal fossa (Figure 4).

In the evaluation of the patient's past medical history, we found that he was a known case of intraorbital neurofibroma when he was 3 years old. Multislice CT without contrast enhancement revealed proptosis of the left eye, thick optic nerve, preseptal soft tissue density with swelling of the upper and lower eyelids and bony defect of the greater wing of the sphenoid bone (Figure 5).

Incisional biopsy of the maxillary lesion was performed. In the histopathological examination, a neoplastic structure was found in the connective tissue of the gingival mucosa, composed of spindle and ovoid cells in the fairly loose stroma and some of them had wavy nuclei (Figure 6). Methylene blue staining revealed numerous mast cells, especially near to the vessels. Histopathological findings

and positive reaction for S100 protein confirmed the diagnosis of neurofibroma.

3. Discussion

Intraosseous neurofibroma is relatively rare in the head and neck, with the most common site being in the mandible. Neurofibroma has been reported infrequently in the maxilla. In this case, involvement of the maxilla accompanying the mandible is the prominent point. The higher occurrence of this lesion in the mandible may be related to the long thick bundle of the inferior alveolar nerve (1). In addition to the major criteria, axillary freckles, iris hamartoma, bone dysplasia; nervous system tumor (shwannoma) must be considered as the minor criteria (8). Systemic involvements such as involvement of the cardiovascular, gastrointestinal and central nervous systems have been explained in the literature (9).

In the mandible, neurofibroma is accompanied with fusiform enlargement of the foramen and the inferior ca-

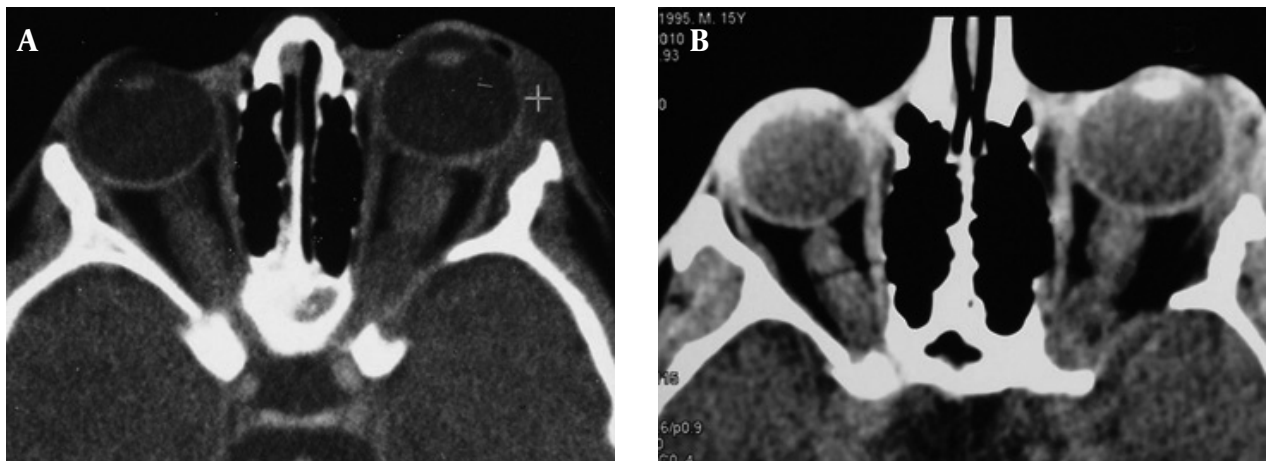


Figure 5. A, CT scans of the orbit at the age of 3 years and; B, The age of 15 years show soft tissue density in supralateral portion of left orbit adjacent to the globe. Thick optic nerve and bony defect in the left posterior and lateral wall of the orbit are observed.

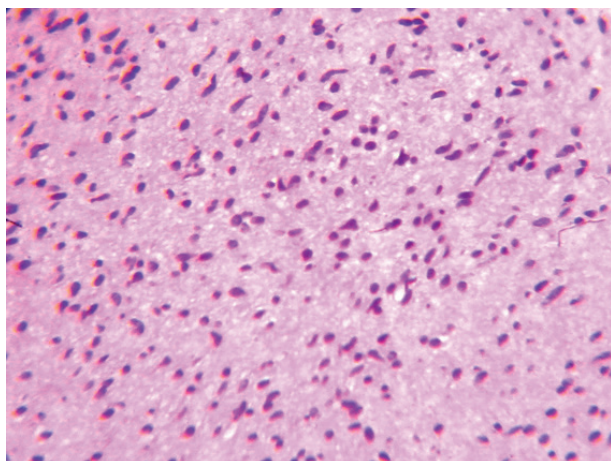


Figure 6. Photomicrograph shows spindle and ovoid cells in the fairly loose stroma. Wavy nuclei are observed in some of them (Hematoxyline and Eosin: magnification $\times 400$).

nal, a branched mandibular canal, a deep sigmoid notch, a decreased mandibular angle, a deformed condyle, non-eruption of the teeth and a cyst like lesion (10-13). The stated findings were found in our case. Hypo- or hyperplasia of the mandible, maxilla, zygoma and the temporomandibular joints were also reported in these patients (1). We also detected these findings in this case.

In the differential diagnosis of neurofibroma, shwannoma, hemangioma, lymphangioma and rhabdomyosarcoma should be considered. Orbital neurofibroma must be discriminated from optic sheath meningioma, orbital pseudotumor and granulomatous disease (14).

The simultaneous occurrence of neurofibroma and intratumor bleeding may happen which is the result of vessel hyperplasia and aneurysm (15, 16).

Low platelet sensitivity to collagen fibers in cases with neurofibroma is the rational explanation for intratumor

hemorrhage and excessive bleeding during surgery (12, 16-18). Neurological deficits and hemorrhage are the most common complications of surgery which have been encountered (18, 19).

Totally, concurrent involvement of the mandible, maxilla and orbit is not common. In this case, CBCT is required to evaluate the exact extension of the maxillary lesion and the pattern of tooth impaction in the lesion site. As a result of extension of this lesion to the posterior portion of the maxilla, exact evaluation of the pterygomaxillary fissure in order to rule out its involvement is necessary.

Acknowledgments

We would like to thank Dr. Fatemeh Shahsavari for reporting the histopathology findings.

Financial Disclosure

There was no financial support.

Funding/Support

None declared.

References

- Vivek N, Manikandhan R, James PC, Rajeev R. Solitary intraosseous neurofibroma of mandible. *Indian J Dent Res.* 2006;**17**(3):135-8.
- Shapiro SD, Abramovitch K, Van Dis ML, Skoczylas LJ, Langlais RP, Jorgenson RJ, et al. Neurofibromatosis: oral and radiographic manifestations. *Oral Surg Oral Med Oral Pathol.* 1984;**58**(4):493-8.
- White SC, Pharoah J. *Oral Radiology: Principles and Interpretation.* St. Louis, Mo.: Mosby/Elsevier; 2009.
- Mori H, Kakuta S, Yamaguchi A, Nagumo M. Solitary intraosseous neurofibroma of the maxilla: report of a case. *J Oral Maxillofac Surg.* 1993;**51**(6):688-90.
- Friedman JM. Epidemiology of neurofibromatosis type 1. *Am J Med Genet.* 1999;**89**(1):1-6.
- Kottler UB, Conway RM, Schlotzer-Schrehardt U, Holbach LM. Isolated neurofibroma of the orbit with extensive myxoid changes: a clinicopathologic study including MRI and electron microscopic findings. *Orbit.* 2004;**23**(1):59-64.
- Jacquemin C, Bosley TM, Svedberg H. Orbit deformities in craniofacial neurofibromatosis type 1. *AJNR Am J Neuroradiol.* 2003;**24**(8):1678-82.
- Sakai A. [Characterization of the neurofibromatosis type 1 gene and neurofibromin's role in cells]. *Nihon Rinsho.* 2000;**58**(7):1426-9.
- Geist JR, Gander DL, Stefanac SJ. Oral manifestations of neurofibromatosis types I and II. *Oral Surg Oral Med Oral Pathol.* 1992;**73**(3):376-82.
- Lee L, Yan YH, Pharoah MJ. Radiographic features of the mandible in neurofibromatosis: a report of 10 cases and review of the literature. *Oral Surg Oral Med Oral Pathol Oral Radiol Endod.* 1996;**81**(3):361-7.
- Hisatomi M, Asaumi J, Konouchi H, Yanagi Y, Kishi K. Bone deformity showing a deep coronoid notch of the mandible in a patient with neurofibromatosis type 1. *Dentomaxillofac Radiol.* 2005;**34**(6):380-3.
- Sun ZJ, Zhao YF, Wang SP, He SG. Giant facial haematoma in neurofibromatosis type 1. *Dentomaxillofac Radiol.* 2008;**37**(1):52-7.
- Friedrich RE, Giese M, Schmelzle R, Mautner VF, Scheuer HA. Jaw malformations plus displacement and numerical aberrations of teeth in neurofibromatosis type 1: a descriptive analysis of 48 patients based on panoramic radiographs and oral findings. *J Craniomaxillofac Surg.* 2003;**31**(1):1-9.
- Harnsberger HR. *Diagnostic imaging: Head and neck.* Salt Lake City, UT: Amirsys; 2004.
- Nopajaroonsri C, Lurie AA. Venous aneurysm, arterial dysplasia, and near-fatal hemorrhages in neurofibromatosis type 1. *Hum Pathol.* 1996;**27**(9):982-5.
- Hamilton SJ, Friedman JM. Insights into the pathogenesis of neurofibromatosis 1 vasculopathy. *Clin Genet.* 2000;**58**(5):341-4.
- Rasko JE, North KN, Favaloro EJ, Crispo L, Berndt MC. Attenuated platelet sensitivity to collagen in patients with neurofibromatosis type 1. *Br J Haematol.* 1995;**89**(3):582-8.
- Apostolidis C, Anterriotis D, Ravidis AD, Angelopoulos AP. Solitary intraosseous neurofibroma of the inferior alveolar nerve: report of a case. *J Oral Maxillofac Surg.* 2001;**59**(2):232-5.
- White AK, Smith RJ, Bigler CR, Brooke WF, Schauer PR. Head and neck manifestations of neurofibromatosis. *Laryngoscope.* 1986;**96**(7):732-7.