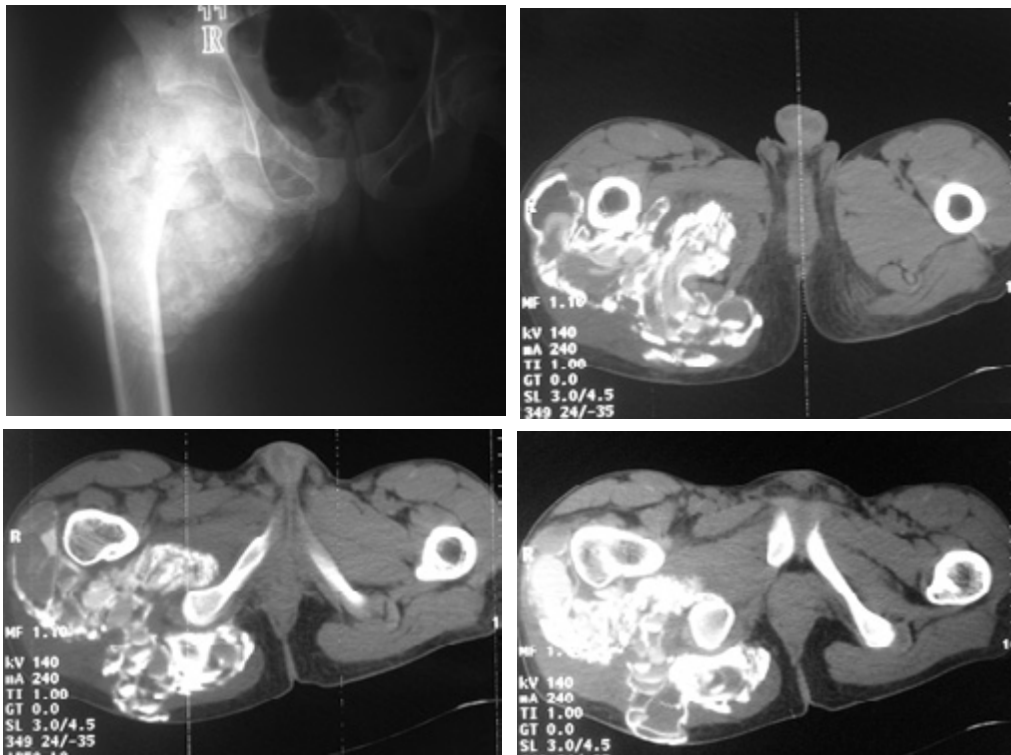


PHOTO QUIZ

What is your diagnosis?

A 17-year-old man was referred for evaluation of a hip mass. He had history of local swelling with limitation of the movements of the right hip. There was no history of trauma or renal disorder. After CT scanning, the mass was removed for pathological evaluation.



Figs 1-4. Plain x-ray and CT scan of the hip mass

What is your diagnosis?

Diagnosis: Tumoral calcinosis

Prepared by: Sh. Shirani MD

Assistant professor, Department of Radiology, Tehran Heart Center, Tehran, Iran.

Tumoral calcinosis is a rare disease characterized by calcified soft tissue masses near the large joints. Approximately one third of the cases have familial inheritance. Nearly 80% of reported cases are black.¹

An inborn error in phosphorus metabolism is accepted as its etiology. Abnormal reabsorption of phosphorus in the proximal renal tubules stimulates extra cellular deposition of hydroxyapatite crystals in synovial bursae, marrow, dental pulp, vessels, skin, and perhaps the retina.² The serum calcium, parathyroid hormone, and alkaline phosphatase levels are normal in spite of increased phosphorus and 1, 25-dihydroxyvitamin D levels.³

It may occur at any age, but mostly it is seen in 1st or 2nd decades of life.⁴

Soft tissue masses are the best-known components of the disease and characteristically occur in par-articular regions, mostly the hip. Generally, they are painless and grow slowly over a period of years. Limitation of the adjacent joint movements happens by large masses. They may compress nearby nerves or ulcerate the skin and form sinus track with chalky milk-like drainage.

The radiographic hallmark of tumoral calcinosis is large multiglobular calcified deposition in par-articular areas, usually along the extensor surface of joints. This calcified material may be paste-like and have a homogeneously dense radiographic appearance or it may be a semi-fluid-milk of calcium and shows sedimentation in the standing radiograph.⁵

CT precisely shows the extension of the lesion. It also reveals milk of calcium as fluid-fluid levels very

well.¹

Tumoral calcinosis on ultrasound appears as cystic masses with multiple septation with layers of echogenic calcium debris.

Despite the limitations of MRI for the evaluation of calcified lesions, it may reveal bone marrow edema in the adjacent bones (high signal on T2 WI). The calcified lesions may be discriminated by high signal (on T2) areas due to granulation tissue. MRI also reveals fluid fluid levels.

Dental pulp calcification (pulp stone), vascular, cutaneous and dural calcification are other manifestation of tumoral calcinosis.²

The main differential diagnoses are periarticular calcium deposition in pseudoxanthoma elasticum and renal osteodystrophy.⁶

Surgical resection is the best treatment if the lesion can be removed en block, otherwise there will be a high chance of recurrence.

References

1. Senol U, Karaali K, Cevikol C, Dincer A. MR imaging findings of recurrent tumoral calcinosis. *J Clin Imaging* 2000 ; 24: 154-156
2. Martinez S, Vogler J, Harrelson J, Lyles K. Imaging of tumoral calcinosis: new observations. *Radiology* 1990; 174:215-222
3. Juhl J.P and Juhl S. *Essentials of radiologic imaging*. Lippincott Williams and Wilkins;1998:341-342
4. Sutton D. *Textbook of radiology and imaging*. 6th ed. Churchill Livingstone; 1998:1403
5. Kakish M, Ghatashah M, Etawi L. Imaging of tumoral calcinosis. *Eastern Mediterranean Health Journal* 2001; 7:846-851
6. Grainger R. *Grainger & Allison's Diagnostic radiology: a textbook of medical imaging*. 3th ed. Churchill Livingstone;1997:1821-1822