

M. Bakhshayesh Karam MD<sup>1</sup>.  
S. Zahirifard MD<sup>1</sup>.  
M.O. Tahbaz MD<sup>1</sup>.  
K. Kaynama MD<sup>2</sup>.  
F. Tolou MD<sup>2</sup>.  
H. Jabari Darjani MD<sup>3</sup>.

## Bronchial Carcinoid Tumors: Clinical and Radiological Findings in 21 Patients

**Background/Objectives:** Bronchial carcinoid tumors are neoplasms that range from typical carcinoids to the more aggressive atypical ones with similar imaging features. Considering the low prevalence of the tumor, we reviewed 21 patients.

**Patients and Methods:** In this retrospective observational study, we reviewed the clinical, pathological and imaging findings in 21 patients diagnosed with bronchial carcinoid tumors who were admitted to National Research Institute of Tuberculosis and Lung Disease (NRITLD) in a 6 years period. Plain radiography and CT scan of patients were reviewed.

**Results:** 52.4% of the patients were male and 47.6% female. The mean age of patients was 39.1 years. The most frequent clinical symptoms were cough (n=15; 71.4%), hemoptysis (n=13; 61.9%), dyspnea (n=12; 57.1%), and pleuritic chest pain (n=7; 19%). Most of the lesions (68%) were in the right lung, 24% in the left lung, 8% in the trachea, and 19% were bilateral. Right upper lobe and right intermediate bronchus (24% and 32%, respectively) were the most frequent sites of tumor. In radiologic examination, two cases (9.5%) had normal CXRs. Pulmonary collapse (52.4%) and mass (23.8%) were the most frequent findings. Reviewing CT scans showed endobronchial lesion in three (15%) and mass in 11 (55%) patients. The mass was well defined in 8 cases (72%) and ill-defined in 3 (28%). Other findings were: mediastinal invasion (45%), atelectasis (55%), post obstructive pneumonitis (20%) and eccentric calcification (15%). Pathological examination revealed typical (n=18; 86%) and atypical (n=3; 14%) carcinoid tumors.

**Conclusion:** Although rare, bronchial carcinoid tumors should be considered a differential diagnosis in adult patients with cough, hemoptysis, dyspnea, and pleuritic chest pain. Chest x-ray and CT scan can help with diagnosis. Major imaging findings are central, round or ovoid well-defined mass, and obstruction signs like atelectasis. Diagnosis and classification should be confirmed by pathological examination on sample taken by bronchoscopy or surgery.

**Keywords:** carcinoid tumor, bronchus, clinical, pathological, imaging

### Introduction

Bronchial carcinoid tumors are neuroendocrine neoplasms that range from low-grade typical carcinoids (90% of tumors) to more aggressive atypical carcinoids (10%), and therefore demonstrate a wide spectrum of clinical behaviors and histologic features.<sup>1</sup> Carcinoids occur most frequently in the gastrointestinal tract (90% of the patients).<sup>2</sup> They can also occur in the lungs, thymus, biliary tract, and ovaries. Bronchial carcinoids are uncommon, comprising only 1-2% of all lung tumors.<sup>3-5</sup> They affect males and females equally over a wide range of age, with a mean of 45 years.<sup>5,6</sup> Patients with bronchial carcinoids are often symptomatic and present with cough and recurrent pulmonary infections. Hemoptysis is frequent.<sup>7-9</sup> Chest pain, shortness of breath, and constitutional symptoms also occur. Cough, hemoptysis, fever, dyspnea, chest pain and obstructive pneumonia may occur as isolated symptoms or in combination. Typical, atypical and metastatic carcinoids have been all reported to cause Cushing's syndrome.<sup>9</sup> Typical and atypical bronchial carcinoids have similar radiologic features, which depend largely on tumor location. About 80% of bronchial

1. Assistant professor, Department of Radiology  
2. Department of Radiology  
3. Assistant professor, Department of Pulmonology

National Research Institute of Tuberculosis and Lung Disease (NRITLD), Maseeh Daneshvay Hospital, Shaheed Beheshti University of Medical Sciences.

**Corresponding Author:**

Mehrdad Bakhshayesh Karam  
Address: Department of Radiology, Maseeh Daneshvay Hospital, Shaheed Bahonar Ave., Darabad, Tehran, Iran  
PO Box: 19575/154  
Tel: 0098-21 22282111  
Fax: 0098-21 22285777  
E-mail: mehrdadbakhshayesh@yahoo.com

Received September 6, 2004;  
Accepted after revision April 24, 2005.

June 2005; 2:111-116

carcinoids arise centrally in the main, lobar and segmental bronchi and demonstrate no specific lobar distribution.<sup>10</sup> Radiological findings include hilar or perihilar masses, endobronchial nodules, findings related to bronchial obstruction, and peripheral nodules.<sup>1</sup> Regarding the low prevalence of bronchial carcinoid tumors, in this paper we reviewed clinical, pathological, and imaging findings of 21 patients.

## Patients and Methods

In this retrospective observational study we reviewed patients records in a 6-year period from 1996 to 2002 in NRITLD, which included personal and clinical data, chest radiographs, and a chest CT scan. All patients were pathologically diagnosed with samples from surgery or bronchoscopy (washing, brushing, and biopsy).

Patients' records were reviewed. Chest radiographs had been obtained at 80 KVp using CGR 1000 mA. Conventional 10 mm collimation CT had been performed from apex to the base of the lungs (Siemens Somatom Plus; Elinger, Germany). Two radiologists independently reviewed all images. Morphologically the removed were divided in two types: Typical (benign neuroendocrine tumors) and atypical (well-differentiated neuroendocrine carcinoma) carcinoid tumors. Diagnostic criteria for typical carcinoids were well-differentiated tumors with rare mitoses, pleomorphism and necrosis. Histological criteria for the diagnosis of atypical carcinoids were increased mitotic activity, nuclear pleomorphism, and disorganized matrix.

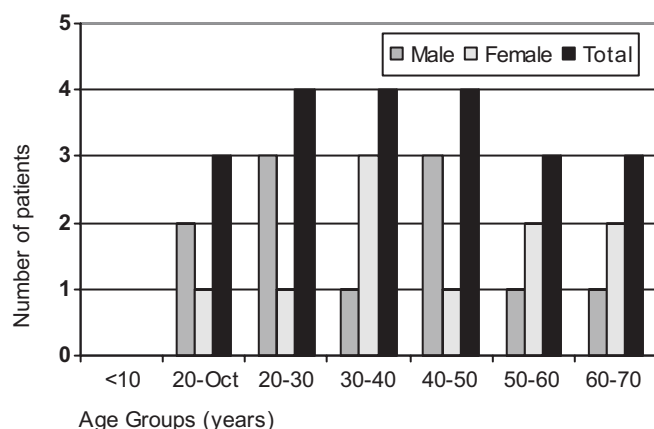


Fig 1. Distribution of age and gender of patients with bronchial carcinoid tumor. None of the cases were >70 years old.

## Results

Of 21 diagnosed patients, 11 cases (52.4%) were male and 10 (47.6%) were female. The mean age of the patients in this study was 39.1 years. Distribution of the age groups with regard to their gender is shown in (Figure 1).

## Presenting Symptoms

Patients in our study presented with cough, hemoptysis, dyspnea, pleuritic chest pain, night sweats, weight loss, weakness, and nausea; one patient was asymptomatic. Results have been shown in Table 1. Only one patient presented with symptoms related to Cushing's syndrome. Of 15 patients with dyspnea, 11 had productive cough and sputum.

## Tumor Location

In our study, the neoplasm was located in the right lung in 17 patients (68%), the left lung in 6 (24%) (4 patients had bilateral lesions), and in the trachea in only 2 patients (8%). Different tumor locations are

Table 1. Frequency of the presenting symptoms.

Symptoms	No.*	%
Cough	15	71.4
Hemoptysis	13	61.9
Dyspnea	12	57.1
Pleuritic chest pain	7	33.3
Night sweats	4	19.0
Weight loss	3	14.2
Fever	3	14.2
Weakness	2	9.2
Nausea	1	4.7
Asymptomatic	1	4.7

\* Number of patients

Table 2. Site of bronchial carcinoid.

Site	%	Total**	No.*
Right	Main bronchus		1 4
	Intermediate bronchus		6 24
	Upper lobe	17	8 32
	Middle lobe	(68%)	2 8
Lower lobe	0 0		
Left	Main bronchus		1 4
	Upper lobe	6	2 8
	Lingula	(24%)	1 4
Lower lobe	2 8		
Trachea		2 8	2 (8%)

\* Data are presented as No (Numbers).

\*\* 4 patients had bilateral involvement.

shown in Table 2.

### Diagnostic Confirmation

The diagnosis of the disease in this study was confirmed by pathological examination of bronchoscopy samples. Tissue from one patient was taken by thoracoscopy.

Pathological diagnoses were typical carcinoids in 18 (86%) and atypical carcinoids in 3 (14%) of the patients.

### Chest x-ray Findings

Chest x-ray was normal in 2 patients (9.5%), and had at least one finding in the rest (90.5%). CXR features included collapse (the most common), mass, pleural effusion, infiltration, lymphadenopathy, bronchiectasis, and nodule (the least common) (Table 3), (Fig 2a).

### CT scan Findings

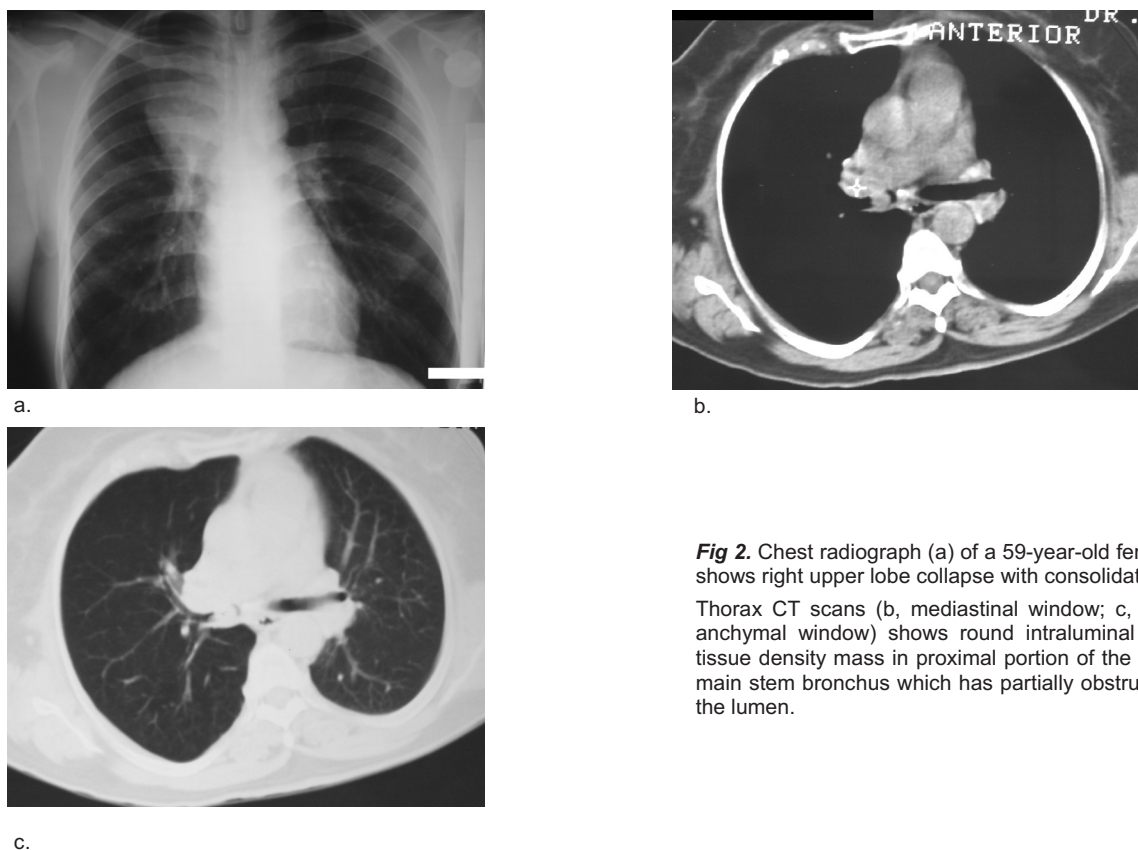
One patient had no CT scan. Other findings included: endobronchial lesions, mass, lymphadenopathy, atelectasis, hyperaeration, post-obstructive pneumonitis, and calcification. Other features were bronchiectasis, pleural effusion, pleural thickening, pneumothorax, and mucoid impaction. The most

common findings were mass and atelectasis and the least common was hyperaeration (Table 4), (Fig 2b&c).

## Discussion

### Demographics

In this study, as mentioned before, there were fewer female patients than males (47.6 % females compare to 52.4 % males). Contrary to our results, in an extensive literature review and analysis of 2,837 patients with carcinoid tumors performed by Godwin, 52% of the patients were female and 48% were male.<sup>5</sup> Melissa et al. 1999, in an article entitled "Thoracic carcinoids: radiologic-pathologic correlation" noted that affected population had significantly lower male-to-female ratio.<sup>9</sup> The average age of our patients was 39.1 years. In 1992, Schreus et al. and in 1996 Dusmet et al. in two separated studies concluded that affected individuals display a wide age range, with average age of 45.5 years at presentation.<sup>7, 11</sup> There are five articles in the literature showing female: male ratio >1 (F: M). Analysis of these 5 articles by Fink G et al. showed female/male ratio of 1.1:1<sup>12-17</sup>. Results of a study by Descovich P et al. in 2000 showed the M: F ratio of 0.6 and the average age of 42.5 years.<sup>18</sup>



**Fig 2.** Chest radiograph (a) of a 59-year-old female shows right upper lobe collapse with consolidation. Thorax CT scans (b, mediastinal window; c, paranchymal window) shows round intraluminal soft tissue density mass in proximal portion of the right main stem bronchus which has partially obstructed the lumen.

**Table 3.** Frequency of different CXR findings in the patients.

Imaging findings in CXR	Frequency of findings	Percent
Normal	2	9.5
Collapse	11	52.4
Mass	5	23.8
Pleural effusion	3	14.3
Infiltration	2	9.5
Lymphadenopathy	2	9.5
Bronchiectasis	2	9.5
Nodule	1	4.8

**Table 4.** CT findings of bronchial carcinoid tumor.

CT findings	No.*	%
Endobronchial lesion	3	15
Mass	11	55
Central	9	82
Peripheral	2	18
Well-defined	8	72
Round	6	
Ovoid	2	
Slightly lobulated	0	
Ill-defined (irregular)	3	28
Unifocal	11	100
Multifocal	0	0
Mediastinal invasion	5	45
Ipsilateral	8	40
Lymphadenopathy		
Bilateral	0	0
Atelectasis	11	55
Hyper-airiation	2	10
Post-obstructive pneumonitis	4	20
Eccentric	3	15
Calcification		
Diffuse	0	0

\* No: Number of finding

### Histology

Bronchial carcinoids are categorized into two major groups. About 90% are typical carcinoid tumors.<sup>19</sup> The remaining 10% of the lesions are atypical carcinoid tumors, which tend to have a higher rate of metastasis and are larger at the time of diagnosis.<sup>1, 20</sup> Our study shows typical and atypical carcinoids in respectively 86% and 14% of the patients. Fink G et al. in 2001, in another study reviewed 640 cases from the literature. Their final results showed that 81% of bronchial carcinoids were typical and 19% were

atypical.<sup>12</sup>

### Clinical data

Our study showed the most frequent symptoms to be cough (76%), hemoptysis (67%), and dyspnea (57%). It has been noted in the literature that patients with bronchial carcinoids are often symptomatic and their presenting symptoms include cough, fever, expectoration, wheezing, hemoptysis and chest pain<sup>21</sup>. Hemoptysis occurs in at least 50% of the patients, reflecting the highly vascular nature of these neoplasms.<sup>9, 22</sup> However, about 19-51% of the patients are asymptomatic and bronchial carcinoid is diagnosed because of their abnormal findings on chest radiographs.<sup>3, 7, 23</sup> Most frequent symptoms in a study by Montresor et al. in 1994 performed on 27 patients with carcinoid tumor were cough (51.8%) and recurrent bronchitis (37%).<sup>24</sup> Results of a study by Malatani TS et al. in 1997 showed that cough, hemoptysis and recurrent chest infection were the most frequent symptoms.<sup>25</sup> Parej E et al. in 1998 in a retrospective study on 18 patients of bronchial carcinoids in Spain showed that the symptoms most often reported were recurring infection (44.5%) and chest pain (33.3%). At last, presenting symptom in Fink's study was the evidence of bronchial obstruction (n=58; 41%); including obstructive pneumonitis, pleuritic chest pain, atelectasis, and dyspnea. This was followed by cough in 50 patients (35%), hemoptysis in 33 patients (23%), and a variety of other sign/symptoms including weakness, neuralgia, hyperparathyroidism, and Cushing's syndrome all occurred in 22 (15%) of the patients, while 30% were asymptomatic.<sup>12</sup>

One patient in our study had symptoms related to Cushing's syndrome; nevertheless, a small number of patients presented with symptoms related to Cushing's syndrome, seen in approximately 2% of cases with bronchial carcinoids.<sup>9</sup> Approximately 1% of cases of Cushing's syndrome are secondary to bronchial carcinoids through secretion of ectopic ACTH or ACTH-releasing hormone. In fact, bronchial carcinoids represent the most common source of ectopic ACTH production.<sup>8, 9</sup>

### Tumor Size and Location

Average tumor size in our study was 5\*3.33cm. The tumors ranging 2 to 5cm in size have been reported.<sup>1,</sup>

According to our results, neoplasms were located more in the right lung compared to the left (68% and 24% respectively). In a study by Descovich P et al. in 2000, the amount of right lung carcinoids was 48.5%.<sup>18</sup> In 2001, a study on 142 patients with pulmonary carcinoids by Fink G et al. showed the neoplasm to be located in the right lung in 60% of patients and in the left lung in 40%; the most common sites in decreasing order of frequency were right middle lobe, right upper lobe, right lower lobe, left upper lobe, and left lower lobe.<sup>12</sup> In our study most common sites were right upper lobe, right intermediate bronchus, right middle lobe, left upper lobe, and left lower lobe in decreasing order of frequency.

### Radiology

Axial CT scans remain the technique of choice in detecting and categorizing benign abnormalities of the airways.<sup>28</sup> More than 75% of bronchial carcinoids are detected on conventional postero-anterior chest roentgenograms. Computed tomography may help disclose small neoplasms that are occult on conventional roentgenograms.<sup>29</sup> CT scans are more sensitive than conventional radiography, especially in detecting small lesions, calcifications and enlarged lymph nodes.<sup>30</sup>

Most prevalent CXR findings in our study were atelectasis (52.4%) and mass lesions (23.8%). However, in a study by Paerje E et al. in 1998, on 621 bronchial carcinoid patients, the most prevalent radiographic finding was a single nodule of the lung.<sup>31</sup>

Review of CT scans in our study revealed the most frequent finding to be a mass with well-defined and round border (72%). Also, atelectasis (55%), mediastinal invasion by tumor (25%), and eccentric calcifications (15%) were other frequent findings.

Central bronchial carcinoids most frequently manifest as a hilar or perihilar mass. The mass is usually a well-defined round or ovoid lesion and may be slightly lobulated on radiographs and CT scans. The tumors 2 to 5cm in size.<sup>1, 10</sup> Multifocal tumors are rarely observed.<sup>1, 10, 32</sup> Eccentric calcifications are common, especially in central carcinoids, with foci of calcification or even ossification seen at histologic analysis in up to 30% of the cases.<sup>1</sup> Central carcinoids often demonstrate radiologic evidence of an endo-

bronchial component. Although most carcinoids are primarily endobronchial lesions, they may only extend into the adjacent parenchyma. Such tumors may display a dominant extra-luminal component with a very small endobronchial portion ("iceberg" lesion).<sup>33</sup> CT provides anatomic localization of both intra- and extra-luminal components.<sup>34</sup> Findings related to bronchial obstruction such as atelectasis, air trapping, obstructing pneumonitis, and mucoid impaction may also be seen. In about 20% of the cases, a bronchial carcinoid manifests as a solitary pulmonary nodule in the lung periphery distal to the segmental bronchi. CT scan can depict small peripheral tumors 5mm or less in diameter; such tumors are rarely detected at conventional radiography.<sup>1</sup> In a retrospective study by Garcia-río FJ et al. performed on 20 cases of lung carcinoids, their radiological results showed lobar or segmental atelectasis (40%), nodule/mass (30%), lobar or segmental consolidation (20%), obstructive pneumonitis (5%), and atypical pleural effusion (5%).<sup>35</sup> CT scan findings in a study by Marty-Ane C et al. in 1994, following CXR screening, showed a nodular peripheral mass in 65% of patients and central mass or atelectasis in the rest (35%).<sup>36</sup> In a study by Nessi R et al. on 49 cases, carcinoids appeared most frequently (77%) as round or oval opacities with sharp and often notched margins. They often induced airway compression with pulmonary atelectasis; enlarged hilar lymph nodes from metastasis were rare.<sup>10</sup> Squerrzanti A et al. in 2002 studied 20 patients with bronchial carcinoid; in central tumors, a round well-circumscribed hilar mass was noted with lobulated or bumpy margins. Central cavitation was not included. Peripheral bronchial carcinoids appear as a solitary nodule, smaller than 3cm in size, marinated, surrounded by normal pulmonary tissue.<sup>30</sup> Mentioning previous studies, Jeung My et al. in 2002 in an article suggested that the diagnosis of bronchial carcinoid should be made if there was a well-defined, centrally located tumor that narrows, deforms, or obstructs an adjacent airway and contained diffuse or punctuate calcifications.<sup>1, 26, 34</sup>

### Conclusion

No current clinical or laboratory procedures are useful in confirming the diagnosis; particularly, none

of the imaging modalities are able to differentiate between bronchial carcinoid tumors and other pulmonary tumors. For this reason, a clinical, radiologic, endoscopic, and histopathologic approach is necessary.

According to our results, it is suggested that bronchial carcinoid tumors be considered a differential diagnosis in adult patients presented with cough, hemoptysis, dyspnea, and pleuritic chest pain. Chest x-rays and CT scans can aid in the diagnosis. Major imaging findings are central, round or ovoid, and well-defined masses and also findings related to obstruction like atelectasis. Diagnosis and tissue typing should be confirmed by pathological examination on sample taken in bronchoscopy or surgery.

## References

- Jeung MY, Gasser B, Gangi A, Charneau D, Ducrocq X, Kessler R et al. Bronchial carcinoid tumors of the thorax: spectrum of radiologic findings. *Radiographics*. 2002; 22(2): 351-365.
- Buck JL, Sobin LH. Carcinoids of the gastrointestinal tract. *Radiographics* 1990; 10: 1081-1095.
- Colby TV, Koss MN, Travis WD. Carcinoid and other neuroendocrine tumors. In: Colby TV, Koss MN, Travis WD, eds. *Atlas of tumor pathology: tumors of the lower respiratory tract, fasc 13, ser 3*. Washington, DC: Armed Forces Institute of pathology, 1995; 287-317.
- Paladugu RR, Benfield JR, Pak HY, Ross PK, Teplitz RL. Bronchopulmonary kulchitzky cell carcinoma: a new classification scheme for typical and atypical carcinoids. *Cancer* 1985; 55: 1303-1311.
- Godwin JD. Cracinoid tumors: an analysis of 2837 cases. *Cancer* 1975; 36: 560-569.
- Arrigoni MG, Woolner LB, Bernatz PE. Atypical carcinoid tumors of the lung. *J Thorac Cardiovasc Surg* 1972; 64:413-421.
- Dusmet ME, Mckneally MF. Pulmonary and thymic carcinoid tumors. *Wrld J Surg*; 20: 189-195.
- Engelbreth-Holm J. Gited by: Davila DG, Dunn WF, Tazelaar HD, Pairolero PC. Bronchial Carcinoid tumors. *Mayoclin proc* 1993; 68: 795-803.
- Rosado de Christenson ML, Abbott GF, Kirejczyk WM, Galvin JR, Travis WD. Thoracic carcinoids: Radiologic-Pathologic correlation. *Radiographics* 1999; 19(3); 707-36.
- Nessi R, Basso Ricci P, Basso Ricci S, Bosco M,Blanc M,Uslenghi C et al.Bronchial carcinoid tumors: radiologic observations in 49 cases. *J Thorac Imaging*. 1991; 6(2): 47-53.
- Schreurs AJM, Westermann CJJ, Vanden Bosch J, Vanderschueren RGJRA,. A twenty-five-year follow-up of ninety-three resected typical tumors of the lung. *J Thorac Cardiovasc Surg* 1992; 104: 1470-1475.
- Fink G, Krelbaum T, Yellin A, Bendayan D, Saute M, Glazer M, Kramer MR. Pulmonary carcinoid: presentation, diagnosis, and outcome in 142 cases in Israel and review of 640 cases from the literature. *Chest*. 2001; 119(6):1647-1651.
- Hurt R, Bates M. Carcinoid tumors of the bronchus: a 33-year experience. *Thorax* 1984; 39: 617-623.
- McCaughan BC, Martini N, Bains MS. Bronchial carcinoids; review of 124 cases . *Thorac Cardiovasc Surg* 1985; 89: 8-17.
- Bertelson C, Austed A, Lund C. Bronchial carcinoid tumors: a clinicopathological study of 82 cases. *Scand Thorac Cardiovasc Surg* 1985; 19: 105-111.
- Harpole DH, Feldman JM, Buchanan S. Bronchial carcinoid tumors: a retrospective analysis of 126 patients. *Am Thorac Surg* 1992; 54: 50-55
- Gould PM, Bonner Ja, Sawyer TE, Deschamps C, Lange CM, Li H. Bronchial carcinoid tumors: importance of prognostic factors that influence patterns of recurrence and overall survival. *Radiology* 1998;208 :181-185
- Descovich P ,Ansaloni L, Grazia M, Bazzocchi R.Bronchial carcinoids.Our experience with 35cases.*MineruaChir*.2000 ;55(3) :1313-1319
- Hamperl H. U"ber gutartige bronchialtumoren (cylindrome und carcinoid). *Virchows Arch Pathol Anat* 1937; 300:46-88
- Arrigoni MG, Woolner LB, Bernatz PE. Atypical carcinoid tumors of the ung. *J Thorac Cardiovasc Surg* 1972; 64: 413-421
- Todd TR, Cooper JD, Weissberg D, Delarue NC, Pearson FG. Bronchial carcinoid tumors: twenty year's experience. *J Thorac Cardiovasc Surg* 1980; 79: 532-536.
- Fraser RG, Pare' JAP, Pare' PD, Fraser Rs, Genereux GP. Neoplasms of pulmonary neuroendocrine cells. In: Fraser RG, Pare' JAP, Pare' PD, Fraser RS , Genereux GD, eds. *Diagnosis of disease of the chest*. 3rd ed. Philadelphia, Pa: Saunders, 1991; 1476-1497.
- Giustra PE, Stassa G. The multiple presentations of bronchial adenomas. *Radiology* 1969; 93:1013-1019
- Montresor E, Lupi A, Gorla A, Modenas, Caneva A. Pulmonary carcinoid tumors. *Chir Ital*. 1994; 46 (3): 29-36.
- Malatani TS, Batouk A, Teklu B, Irani C,Dewan M, Softah AH et al. bronchial carcinoid tumors in southern Saudi Arabia.*Indian J Chest Allied Sci*. 1997; 39 (4) 221-227.
- Magid D, Seigelman SS, Eggleston JC, Fishman EK, Zerhouni EA.Pulmonary carcinoid tumors: CT assessment. *J Comput Assist Tomogr* 989; 13: 244-247.
- Zwiebel BR, Austin JHM, Grimes MM. Bronchial carcinoid tumors: assessment with CT of location and intra tumoral calcification in 31 patients. *Radiology* .1991; 179: 483-486.
- Ferretti GR, Thony F, Bosson JL, Pison C, Arbib F,Coulomb M. Benign abnormalities and carcinoid tumors of the central airways: diagnostic impact of CT bronchography.*AJR*. 2000; 174 (5): 1307-1313
- Davila DG, Dunn WF, Tazelaar HD, Pairolero PC. Bronchial carcinoid tumors. *Mayo Clin Proc*. 1993; 68 (8): 795-803.
- Squerzanti A, Basteri V, Antinolfi G, D'agostino F, Scutellari PN, Ravenna F et al. Bronchial carcinoid tumors: clinical and radiological correlation. *Radiol Med (Torino)*. 2002; 104 (4): 273-284.
- Pareja E, Amau A, Artigues E, Peiro F, Hostalet E,Canto A. Bronchial carcinoid tumors: a prospective study. *Arch Bronconemol* 1998; 34(2): 71-75.
- Ducrocq X, Thomas P, Massard G, Barsotti P, Giudicelli R, Fuentes P, Wihlm JM. Operative risk and prognostic factors of typical bronchial carcinoid tumors.*Ann Thorac Surg*. 1998; 65(5):1410-1414.
- Muller NL, Miller RR. Neuroendocrine carcinomas of the lung. *Semin Roentgenol*. 1990; 25(1):96-104.
- Naidich DP. CT/MR correlation in the evaluation of tracheobronchial neoplasia. *Radiol Clin North AM*. 1990; 28: 555-571
- Garcia-Rio FJ, Talavera IG, Rubio BG, Prados C, Rodriguez P. Clinical study of 20 cases of bronchial carcinoid. *An Med Interna*. 1992; 9(1):9-13.
- Marty-Ane C, Alauzen M, Costes V, Serres-Cousine O, Mary H. Heterogeneity of bronchial carcinoid tumors: Place of atypical forms. *Ann Chir*. 1994; 48(3):253-258.