

M.T. Meamarzadeh MD¹.
G.H. Shahrzad MD².

Hysterosalpingography in Unsuspected Pregnancy : Report of 6 Cases and 2 Relevant Cases

Here are the reports on evaluation and hysterosalpingographic (HSG) findings of 6 unsuspected pregnancies. Besides, two relevant cases of importance in the authors' 30 years of radiology practice are included.

Two important radiologic features found on HSG in unsuspected pregnancies are double outlined uterine cavity (DOUC) and filling defect features.

Despite the irradiation exposure of the fetuses in their early life, 4 ended up in normal infant deliveries, one of them being a twin delivery. One case of miscarriage occurred due to an intrauterine device. One case refused the follow-up sessions.

It seems when performed by mistake throughout early pregnancy, the HSG will not necessitate termination of the pregnancy.

Keyword: hysterosalpingography, unsuspected pregnancy

Introduction

Hysterosalpingography (HSG) is a commonly used diagnostic technique in the infertility workup to assess the size and contour of the uterine cavity and determine the tubal patency. Most of the patients do not use contraception and some may have irregular cycles.

Historically, HSG was originally used for diagnosis of pregnancy. Hauser reported the first clinical HSG application for diagnosis of early pregnancy.¹ Miller and Martinz reported their results on HSG in 15 pregnant women, performed by intrauterine injection of 10-15 milliliters of iodized oil (lipiodol) with three miscarriages, so that they discouraged the procedure.²

Although HSG is no longer used to diagnose pregnancy, it may be performed accidentally on pregnant women. Few reports regarding unexpected pregnancy have been published. The prevalence reported by Justesen et al was 0.6%, reporting four cases of pregnancy out of 6,225 inpatient HSGs.³ Jongen et al and Cheung respectively reported one and 3 such cases.^{4,5}

We report 6 cases of HSG in pregnancy, observed during the authors' 30-year practice in spite of taking safety measures such as, performing the procedure 3 days after menstruation had ceased and obtaining a negative pregnancy test.

The current report has the advantage of recruiting more cases than the previous similar studies, and also the HSGs of all cases are available.

Case 1

The patient was a 26-year-old nulliparous woman with irregular menses and oligomenorrhea, undergoing HSG as a workup for the primary infertility of four years. Her previous menstruation was 1 month prior to the investigation and a pregnancy test was carried out on the same day as the HSG, which proved to be

1. Associate professor, Department of Gynecology Akbarabadi Maternity Hospital, Iran University of Medical Sciences, Tehran, Iran.

2. Associate professor, Department of Radiology, Mirza Kochak Khan Hospital, Tehran University of Medical Sciences, Tehran, Iran.

Corresponding Author:

Mohammad Taghi Meamarzadeh
Address: Department of Gynecology,
Akbarabadi Maternity Hospital, Iran
University of Medical Sciences, Tehran,
Iran.

Tel: 009821-55638558

Fax: 009821-55608012

E-mail: meamarzadeh@yahoo.com

Received November 3, 2004;

Accepted after revision April 25, 2005

June 2005; 2:147-151

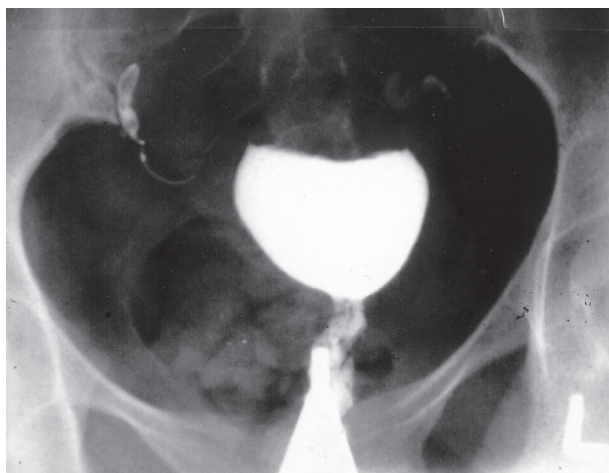


Fig 1. HSG of case 1 . A slightly enlarged uterine cavity with round smooth contour . inspite of pregnancy, feature of HSG in pregnancy was not seen .

negative.

The hysterosalpingogram showed a slightly enlarged uterine cavity with a round smooth contour without filling defect and a double outlined uterine cavity (DOUC).

However, the repeat pregnancy test turned out to be positive.

The patient delivered a normal infant 8 months later (Figure 1).

Case 2

The 26-year-old woman who was not aware of being pregnant, due to the vaginal bleeding resembling menstrual bleeding ten days before referral. She had a history of primary infertility and irregular menses

for 6 years.

Her HSG showed an enlarged uterine cavity with DOUC, showing no filling defects.

The patient delivered a normal infant 8 months later .(Figure 2)

Case 3

The patient was a 32-year-old multiparous woman with history of 4 years' secondary infertility and irregular menses. Her last menstruation was 7 days before she underwent HSG for infertility workup. She reported the use of the intra-uterine device (IUD) that had been removed 4 years prior by her practitioner. During the HSG, the tail of the IUD was not visible.

HSG demonstrated a large intrauterine filling defect due to gestational sac together with a missed retention safe T-coil intra uterine device (IUD).

This patient aborted her fetus 5 days after HSG probably because of the IUD (Figure 3).

Case 4

A 25-year-old nulliparous woman with oligomenorrhea and 5 years' infertility was referred for HSG based on a negative pregnancy test result despite a missed menstrual cycle.

HSG showed both the filling defect (i.e. the gestational sac) and double uterine contour (DOUC).

Since the patient refused the follow-up visits, the outcome of her pregnancy is not known (Figure 4).

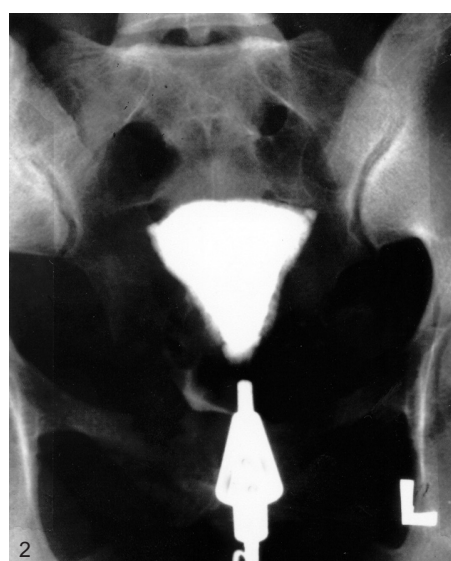

Fig 2. Enlarged uterine cavity with double outline cavity (DOUC) , without filling defect

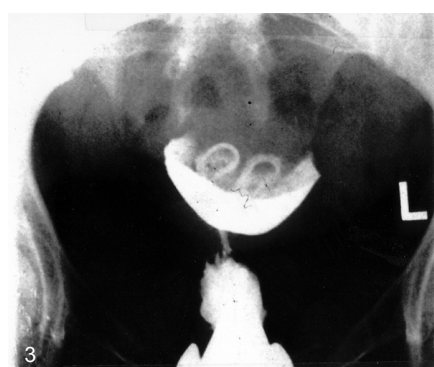


Fig 3. Filling defects from pregnancy and Safe-T-coil IUD.

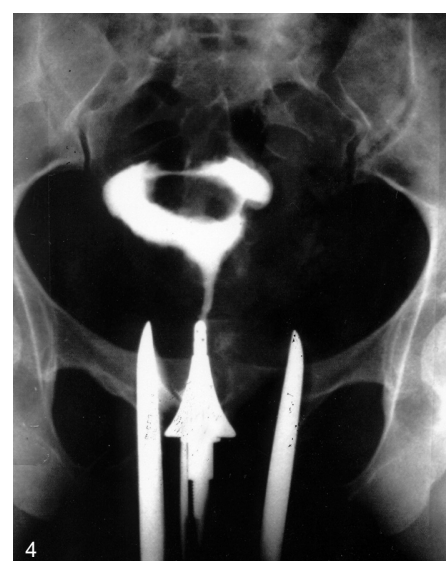


Fig 4. DOUC together with filling defect

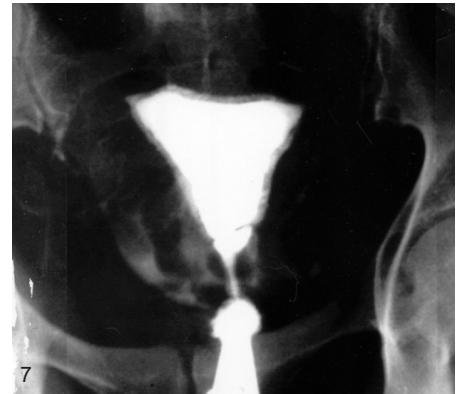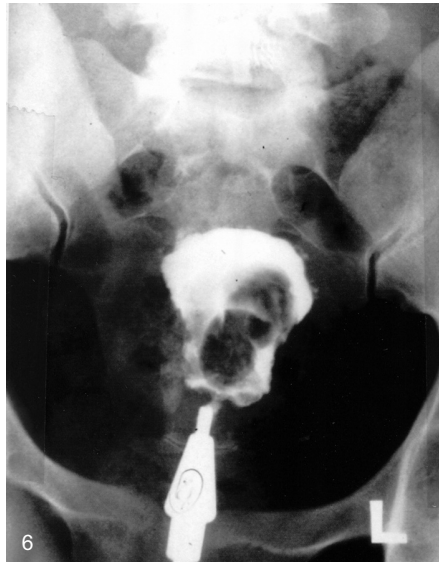
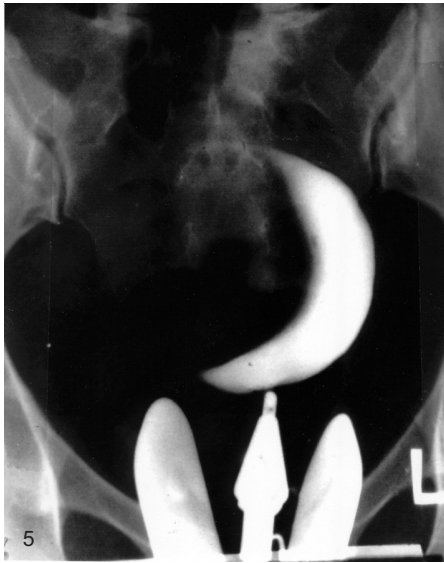


Fig 5. The crescent sign of a 20 weeks' pregnancy.

Fig 6. HSG of case 6 double filling defects due to twin pregnancy.

Fig 7. DOUC in a secretory endometrium, a normal finding.

Case 5

A 23-year-old nulliparous woman with a 3-year history of infertility and irregular menses.

Her last vaginal bleeding together with a negative pregnancy test led to the assumption that she was not pregnant.

A radio-opaque crescent was seen in the left uterine cavity after the HSG was performed.

After two spot films, the HSG examination was stopped, for pregnancy was suspected.

Four months later, she gave birth to a normal infant (Figure 5).

Case 6

A 35-year-old woman with a 5-year history of infertility, and irregular menses referred for HSG. She reported her last vaginal bleeding was 10 days before, so performing HSG appeared to be safe.

Surprisingly, on HSG we observed uterine enlargement and elongation with double irregular filling defects in the uterine cavity (twin pregnancy).

She delivered two normal infants (Figure 6).

Two relevant cases

Case 7

Secretory endometrium may show DOUC

A 25-year-old woman presented with 10-year infertility and amenorrhea.

HSG showed a slightly enlarged uterine cavity with DOUC. This is a normal HSG finding in patients at

the late secretory phase. In this patient, it also could be because of proliferative hyperplastic endometrium.

Case 8

Abdominal pregnancy

In 1962 when no ultrasound device was available, a patient with an abdominal mass was referred for imaging investigations. A plain abdominal film showed a dead 32-week-old fetus with signs of mummification.

On vaginal examination, the uterus was normal in size; so, as the ultimate diagnostic mean HSG was done. On HSG, the uterine cavity was normal with external pressure (Figure 8).

Discussion

Inadvertant HSG on a pregnant uterus is almost inevitable in a busy radiology clinic that performs a large number of hysterosalpingographies. In our radiology clinic 7 HSGs are done per day, and over 30 years of practice, more than 63,000 HSGs have been carried out, and these 6 cases are from such a huge number. HSG is routinely done in the follicular phase, usually on days 6-10 of the menstrual cycle, and before ovulation. Water soluble contrast medium is the only contrast medium we used.

There are two features of HSG during unsuspected pregnancy:

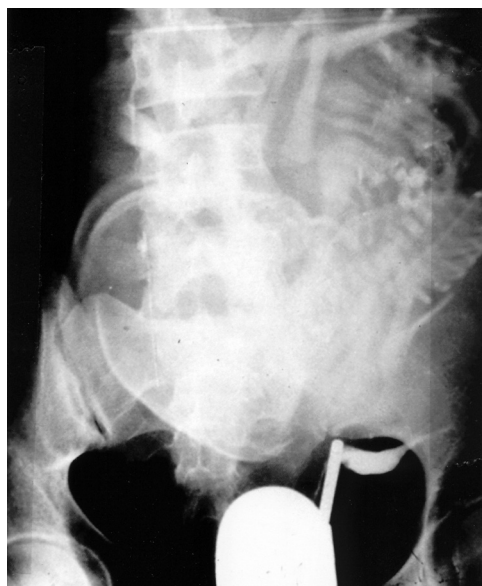


Fig 8. a normal uterine cavity and a 30 weeks' abdominal pregnancy .

1. Double-outlined uterine cavity (DOUC)

Within the first few weeks of conception, a double-outlined uterine cavity is the earliest specific sign of pregnancy. First, a thin line of water soluble contrast medium surrounds the wall of the uterine cavity and the opacification associated with infiltrating decidual lining produces the double-contrast image, hence the term double-outlined cavity (DOUC) .^{6,7}

This feature is not specific for pregnancy and can also be seen elsewhere on HSG, especially in late secretory endometrium (Figure 7).⁶

The absence of double-outline, however, does not exclude a very early intrauterine pregnancy which may present as a nonspecific sign of slight enlargement of the uterine cavity with a nondistinct or fuzzy wall.

2- Filling defects

Three to four weeks after conception, a gestational sac becomes evident as a smooth intrauterine filling defect that if accompanied by a double contour, will be the pathognomonic sign of pregnancy. As pregnancy progresses, the gestational sac appears as a large intrauterine filling defect, difficult to distinguish from endometrial polyps and submucosal myomas or synechiae except by history or ultrasound examination.⁸

The HSG of case 7 showing the double-outline was probably due to the secretory endometrium or hyperplasia of endometrium(Figure 7). The HSG

findings in case 8 were a normal appearing uterine cavity in abdominal pregnancy, which can be seen in Figure 8.

The dangers of HSG in unsuspected pregnancy are disruption of pregnancy, displacement of the fertilized ovum into the uterine tube (ectopic pregnancy) or peritoneal cavity, and mutative effects of radiation on the developing fetus .⁹

Only few cases of successful term pregnancies had been reported in the literature. Ten cases of HSG in pregnancy reported by Willson et al. all lead to normal term infants, and 26 cases in the Goldenberg study were all healthy and free of any congenital defects.^{10,11}

In our series, 4 cases out of 6 resulted in normal term births that were followed up for another 2 years after birth. In one of the patients HSG was taken twice by mistake; one of these 4 cases delivered two healthy infants; and the miscarriage in one of the cases could be due to the missed IUD.

Genetic hazards associated with hysterosalpingography are associated with the irradiation. The amount of ovarian radiation from an HSG depends upon the technical equipment, the number of films obtained, the duration of fluoroscopy, the distance of the tube from the film, and size of the patient.

Using a two-film technique without fluoroscopy, Shirley found that a posterior fornix dosimeter recorded a mean of 129 mrad , which would increase to 1053 mrad when fluoroscopy was used .¹² The calculated radiation exposure during HSG by

Jongen et al. was 3.7 mGy. The teratogenic risk, as Jogen et al. suggested, is too low to justify termination of pregnancy .⁴

In 1962 when no ultrasound device was available, a patient with an abdominal mass was referred for imaging investigations. A plain abdominal film showed a dead 32-week-old fetus with signs of mummification.

On vaginal examination, the uterus was normal in size; so, as the ultimate diagnosis HSG was done. On HSG, the uterine cavity was normal with external pressure (Figure 8).

References

1. Hauser C. Lipiodol in the diagnosis of pregnancy. Lancet. 1925; 2 : 1111.
2. Miller HA, Martinz DB. Iodized oil in diagnosis of pregnancy. Radiology .1928; 11: 191

3. Justesen P, Rammsen F, Andersen PE. Inadvertently performed hysterosalpingography during early pregnancy. *Acta Diagn.*1986;27:711-713
4. Jongen VH, Collins JM, Lubbers JA, Vanelm M. Unsuspected early pregnancy at hysterosalpingography. *Fertil Steril.*2001;76:610-611
5. Cheung GW, Lok I H, Wang A, Yip SK. Unsuspected pregnancy at hysterosalpingography: a report of three cases with different outcome. *Human reproduction.*2003;18(12):2608-2609.
6. Issacs I. Hystero-graphic double outlined uterine cavity: A sign of unsuspected pregnancy. *AJR.*1978;131:305-306
7. Slezak p, Tillinger K. The occurrence and significance of a double outlined uterine cavity (DOUC) in the hystero-graphic picture. *Radiology.*1968; 90(4):756-760
8. Stadtmauer L, Grunfeld L. The significance of endometrial filling defects detected on routine transvaginal sonography. *J ultrasound Med.* 1995; 14(3):169-172
9. Tiesen H, Christensen L, Albertsen j. Normal hysterosalpingography in tubal pregnancy. *Acta*
10. Willson RV, Lee RA, Jensen PA. Inadvertent infertility investigation in pregnant women. *Fertil Steril.*1966;17:126
11. Golenberg RI, White R, Magendantz HC. Pregnancy during the hystero-gram cycle. *Fertil Steril.*1976;27 (11):1274
12. Shirley RL. Ovarian radiation dosage during hysterosalpingography. *Fertil Steril.*1971;22:83.

