

K. Ghandehari MD FLSP¹,
A. Shuaib MD FRCPC FAHA²

Prevalence of Patent Foramen Ovale Detected by Transcranial Color Coded Duplex Sonography in Cryptogenic Stroke Patients

Background/Objectives: Contrast transcranial doppler has been used for detection of right-to-left shunts, such as the patent foramen ovale (PFO).

Materials and Methods: All consecutive patients with cryptogenic brain infarction admitted to the Walter Mackenzie Hospital, Canada, during 2003-2004, enrolled in a prospective study. Cryptogenic stroke was determined using a standard battery of diagnostic investigations. Transcranial color coded duplex sonography (TCCDS) with saline contrast was performed with an HP Sono 5500, USA device and a 4MHz linear probe. The middle cerebral artery was insonated at a 50-55 mm depth through a transtemporal window. Microbubble signals were recorded during normal respiration and Valsalva maneuver.

Results: 114 patients (70 females, 44 males) with cryptogenic stroke had contrast TCCDS done. PFO was detected in 41 patients (30 females, 11 males; 35.9%). In the overall study group, females were more preponderant to have PFO, however the difference was not significant (P=0.053). The frequency of PFO was not significantly different between age groups ≤ 45 years and > 45 years (P = 0.96).

Conclusion: PFO detected by TCCD is an age independent factor in cryptogenic stroke, and its detection is more feasible with Valsalva maneuver.

Keywords: Patent foramen ovale, transcranial doppler

Introduction

Emboli entering the systemic circulation through right-to-left shunts (RLS) are frequently detected due to performing more extensive cardiac investigations of stroke patients. By far, the most common potential RLS is a residual patent foramen ovale (PFO), which is a hemodynamically insignificant interatrial communication present in over 25% of the adult population.¹ In this group, by maintaining a direct communication between the right and left side circulation, PFO can serve as a conduit for paradoxical embolism causing stroke. In PFO, the defect is much like a flap valve, sealed closed by the higher pressure in the left atrium. However at times of elevated right atrial pressure, blood may pass from the right to left atrium and thence into the systemic circulation.¹ Several studies have shown a significant association between PFO and cryptogenic strokes.²

Transesophageal echocardiography (TEE) with intravenous injection of agitated saline is the gold standard test for detection of RLS cases such as PFO.² Transcranial doppler examination of basal cerebral vessels during intravenous injection of saline contrast media has been shown to be a reliable technique to confirm RLS by documenting microbubbles reaching the brain.³ It is a relatively simple bedside procedure and well tolerated by most patients when compared to TEE, which is relatively invasive and may not be appropriate in acute stroke patients.

1. Department of Neurology, Vali-Asr Hospital, Southern Khorasan University of Medical Sciences, Birjand, Iran.

2. Department of Neurology, University of Alberta, Edmonton, Canada.

Corresponding author:
K. Ghandehari, Division of Neurology, Valie Asr Hospital, Ghaffari Street, Birjand, Khorasan, Iran

Tel: +98 651 4433733

Fax: +98 651 4430076

E-mail:

kavianghandehari@yahoo.com

Transcranial color coded duplex sonography (TCCDS) with saline contrast is an advanced technology, and few studies have been conducted by using contrast TCCDS for detection of RLS.³ We prospectively evaluated the frequency of RLS in patients with cryptogenic stroke, using TCCDS with saline contrast.

Materials and Methods

The study population consisted of all consecutive patients with cryptogenic brain infarction admitted to the Walter Mackenzie Hospital, Canada, during April 2003 to April 2004. The diagnosis and etiologic investigation of stroke was made by neurologists. Brain infarction was defined as an ischemic focal neurological deficit that persisted for at least 24 hours.⁴ Cryptogenic brain infarction was defined whenever an identifiable cause of stroke was not revealed by diagnostic investigations. Exclusion criteria included impaired consciousness for more than 7 days, respiratory failure, hemorrhage on brain CT scan, inability to perform Valsalva maneuver, inability or refusal to give informed consent, and technical failure on insonation of the middle cerebral artery. All stroke patients underwent a standard battery of diagnostic investigations.⁴ This included brain CT, ECG, blood electrolytes, blood count and differential, coagulation profile, fasting blood sugar and lipid profile, carotid duplex, and transthoracic echocardiography. Twenty-four hour Holter monitoring was obtained in patients with history of syncope and/or palpitations with non-diagnostic ECG. The TCCDS examinations were performed within 7 days of the patient's admission using an HP Sono 5500, USA device and a 4 MHz linear probe. The study was initiated with the patient lying in the supine position and with head straight. The entire circle of Willis was displayed with color/power doppler technology through the transtemporal window.⁵ The sample volume was placed on the middle cerebral artery at a depth of 50-55 mm and doppler flow image was monitored simultaneously with color/power imaging (duplex) of the artery.⁵ Microcavitation saline was generated by agitating a mixture of 9 mL of normal saline and 1 mL of air between two 10 mL syringes connected by a three-way stopcock.³ Once the contrast was prepared, it was injected directly into the cubital vein. Appearance of microbubbles in the cerebral circulation was indicated by a characteristic chirping or popping sound and a corresponding video spike.⁶ These spikes are of much higher amplitude than the background doppler flow signal.⁶ Figure 1 shows microbubble contrast signals detected by TCCDS technology during intravenous injection of agitated saline.

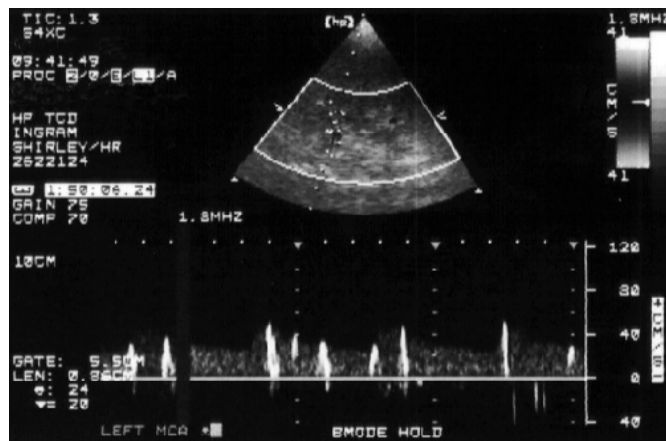


Figure 1: Microbubble contrast signals detected by TCCDS

A 5 minute baseline TCCDS recording of the artery was followed by two saline contrast injections performed during normal respiration and Valsalva maneuver for 5 seconds.² When at least one spike appeared less than 20 seconds after contrast injection, we considered TCCDS positive and assumed direct passage through the PFO.^{2,7} The signals were recorded onto a videotape linked to a computer for analysis. All data were collected prospectively. In our study group, transthoracic echocardiography was used for exclusion of atrial and ventricular septal defects. The odds ratios, T test and Fisher exact test served for statistical analysis, and $P < 0.05$ was declared as significant. The results were compared based on gender and age groups ≤ 45 years and > 45 years.

Results

A total of 114 cryptogenic stroke patients (70 females, 44 males) had contrast TCCDS done during the project period. PFO was detected in 41 patients (30 females, 11 males; 35.9%) and the age difference was insignificant between the genders ($P = 0.96$). In the age group of >45 years, there was a preponderance of PFO in females, as compared to males (45% versus 20%), but the difference was not significant. [OR = 3.29; 95% CI (0.89-12.1); $P = 0.08$]. In the age group of ≤ 45 years, males were more preponderant to having PFO than females (71% versus 59%), but the difference was not significant. [OR = 0.59; 95% CI (0.2-1.75); $P = 0.42$]. In the whole study group, preponderance of PFO in females approached very close to the level of significance. [OR = 2.25; 95% CI (0.98-5.16); $P = 0.053$]. In the age groups of ≤ 45 and > 45 years, respectively 36.5% and 35.3% of the patients had a positive contrast TCCDS exam without statistical significant difference. [OR = 1.05; 95% CI (0.48-2.27); $P = 0.96$]. Tables 1 and 2 show the frequency of PFO detection by TCCDS based on gender and age groups, respectively.

Table 1: Frequency of PFO detection by TCCDS in both genders

Sex \ PFO	PFO Present	PFO Absent
Male	11	33
Female	30	40

Table 2: Frequency of PFO detection by TCCDS in the age groups ≤ 45 years and >45 years

Age \ PFO	PFO Present	PFO Absent
>45 y	18	33
≤ 45 y	23	40

PFO was detected spontaneously in 25 patients, whereas the Valsalva maneuver was required to reveal its presence in 16 other patients (16/41; 39%).

Discussion

TCCDS with saline contrast revealed a 35.9% frequency of PFO in our patients with cryptogenic stroke. Lechat et al.⁸ in a study of 70 stroke patients and 115 controls had found PFO in 11% of controls, 21% in those with an identifiable cause for the stroke, and 54% in those with cryptogenic stroke. Di Tullino et al performed contrast TEE simultaneously with transcranial doppler in 146 consecutive patients with ischemic stroke.⁹ Among these, 45 patients had cryptogenic stroke. PFO was detected in 42% of their patients with cryptogenic stroke, compared with 7% of those with a known cause for stroke. This was observed both in ≤ 45 years (46% versus 4%) and in > 45 years (38% versus 8%) age groups.⁹ We did not perform contrast TEE simultaneously with contrast TCCDS because in previous studies, contrast transcranial doppler results correlated well with those of contrast TEE (which was assumed as a gold standard). The sensitivity was 93% and the specificity was 100% when a standard procedure was performed with the Valsalva maneuver.^{7,9} This pilot study was designed to determine the usefulness of contrast TCCDS in the detection of RLS, but not as a validation study of TCCDS versus TEE. We performed contrast TCCDS only in patients with cryptogenic stroke due to ethical considerations. In medical literature, stroke patients are usually divided into ≤ 45 years and > 45 years age groups due to etiologic differences. We did not find a significant difference in two age groups based on positive PFO test results. Other studies have shown that PFO is more clearly associated with cryptogenic stroke in young adults ≤ 45 years than in the older age group, probably because the importance of PFO as a risk factor is weakened by the preponderance of other stroke mechanisms in the older age group.^{10,11}

Valsalva maneuver was required to reveal PFO in 39% of our patients with positive contrast TCCDS results. In patients with isolated PFO that show transient shunting during the Valsalva, only a minute fraction of the cardiac output is diverted and the likelihood of such PFOs resulting in cerebral embolism seems remote.¹² In about half of young adults with PFO associated stroke, PFO and stroke simply coincide by chance. Even among young patients with cryptogenic stroke, an isolated PFO may still be coincidental.¹² Although contrast TEE is the most sensitive test for detection of RLS, such as PFO, it is relatively invasive and more expensive than contrast TCCDS study.¹⁰ Detection of microbubble signals in the cerebral circulation is not limited to PFO. Any RLS, e.g. atrial or ventricular septal defects, may result in delivery of microbubbles to the cerebral circulation and thus detection by TCCDS. As a result, TCCDS does not identify the site of RLS whereas TEE studies do.

Acknowledgment

The first author was funded by a sabbatical grant from the Research Deputy of the Ministry of Health and Medical Education of Iran.

We are grateful to AR Sa'adatjoo for the statistical analysis.

References

1. Caplan LR. Stroke; A clinical approach. 2nd ed, Boston: Butterworth-Heinemann, 2000: 267-269.
2. Homma S, Di Tullio MR, Sacco RL. Patent foramen ovale and ischemic stroke. In: Barnett HJM, Mohr JP, eds. Stroke. 3rd ed. Philadelphia: Churchill Livingstone, 1998: 1013-1017.
3. Mears SO, Hennerici M. Cerebrovascular Ultrasound. In: Ginsberg MD, Bogousslavsky J, eds: Cerebrovascular Diseases. Vol. 2. Massachusetts: Blackwell Sciences, 1998: 1328.
4. Toole J. Cerebrovascular Disorders. 5th ed. Philadelphia: Lippincott Williams&Wilkins, 1999: 210-211.
5. Bogdahn U, Schlachetzki F, Holscher T. Transcranial color coded duplex ultrasonography. In: Babikian VL, Wechsler LR, eds. Transcranial Doppler Ultrasonography. 2nd ed. Massachusetts: Butterworth-Heinemann, 1999: 285-291.
6. Ghandehari K. Microembolic signal monitoring in patients with acute stroke. Arch Iranian Med 2002; 4: 66-68.
7. Klotzsch E, Janben G, Berlitz P. Transesophageal echocardiography and contrast transcranial doppler in the detection of patent foramen ovale in 111 patients. Neurology 1994; 44: 1603-1606.
8. Lechat P, Mas JL, Lascault G. Prevalence of patent foramen ovale in patients with stroke. N Engl J Med 1998; 318: 1148-1152.
9. Di Tullio MR, Sacco RL, Gopal A. Patent foramen ovale as a risk factor for cryptogenic stroke. Ann Intern Med 1992; 117: 461-462.
10. Job FP, Ringelstein EB, Grafen Y. Comparison of transcranial contrast doppler sonography and contrast transesophageal echocardiography for detection of patent foramen ovale in young stroke patients. Am J Cardiol 1994; 74: 381-384.
11. McGaw D, Harper R. Patent foramen ovale and cryptogenic cerebral infarction. Intern Med J 2001; 31: 42-47.

12. Hankey GJ. Stroke; Your Questions Answered. 1st ed. London: Churchill Livingstone, 2002: 113.