

Z. Soroosh MD¹,
H. Ghanaati MD²,
M. Ayati MD³.

Testicular Microlithiasis

Is it a pre-cancerous state?

Background: Testicular microlithiasis (TM) is an uncommon condition characterized by calcium deposits in the lumina of seminiferous tubules. These intratesticular calcifications appear as bright 2-3-mm echogenic foci on testicular ultrasound. Cumulated experience points to an association between TM, intratubular germ cell neoplasia and other testicular tumors.

Objective: To assess the prevalence of TM revealed on sonography in referred population and its association with the concurrent testicular tumors.

Patients and Method: Over a 129-month period (August 1991-May 2002), 2165 high resolution (7.5 MHz) scrotal sonographies were performed in the Imaging Department of Mehr Hospital, a referral center in Tehran. Cases of testicular tumor and TM were selected. The diagnosis and histologic typing of tumors were made by histopathologic studies.

Results: A total of 15 cases of TM were discovered, giving a prevalence of 0.7%. Concurrent TM and testicular neoplasia were detected in four patients (27% cases of TM).

Conclusion: It is strongly suggested to follow those with TM with physical examination and ultrasonography at least annually and to encourage self-examination.

Keywords: Testicular Neoplasms, Ultrasound, Calculi

Introduction

Testicular microlithiasis (TM) is an uncommon condition. Prior to the advent of high-resolution ultrasonography, the diagnosis of TM was based on testicular biopsy or orchiectomy specimens.¹⁻³ The widespread use of ultrasound to survey scrotal conditions has resulted in the increased incidental discovery of TM. It has been shown that several benign and malignant conditions are associated with TM including cryptorchidism, ischemic injury, hypogonadism, carcinoma in situ and germ cell tumors.⁴⁻⁸

The true prevalence of TM in a normal population is still unknown. Previous studies have reported different values for the prevalence of TM which ranges from 0.6% to 9% in patients referred for scrotal sonography.⁹⁻¹¹

So far, the association of TM and testicular tumors has been well established. However, no exact relationship has been already declared. The coexistence of TM with testicular tumors has raised a justified concern that TM might be a premalignant condition.^{2,12,13}

To address this issue, this study assessed both the prevalence of TM revealed on sonography and the relative risk of concurrent testicular tumors in an outpatient population.

Patients and Methods

Over a 129-month period, from August 1991 to May 2002, 2165 scrotal ultrasonographies were performed in the Imaging Department of Mehr Hospital, a private multi-specialty clinic in Central Tehran.

Regardless of the cause of referral, all patients were included in the study. There was an age range of 3 months to 78 years with a mean of 31 years. The patients underwent high-resolution ultrasonography (Hitachi EUB 525 & Q2000, Siemens, Germany).

From

1. Imaging Department, Mehr General Hospital, Tehran, IRAN
2. Tehran University of Medical Sciences, Department of Radiology, Imam Hospital, Tehran IRAN.
3. Tehran University of Medical Sciences, Department of Urology, Imam Hospital, Tehran Iran.
Corresponding Author:
Dr Z. Soroosh.
Tel: +9821 896-0710
Fax: +9821 896-9155
e-mail: dr_zsoroosh@yahoo.com

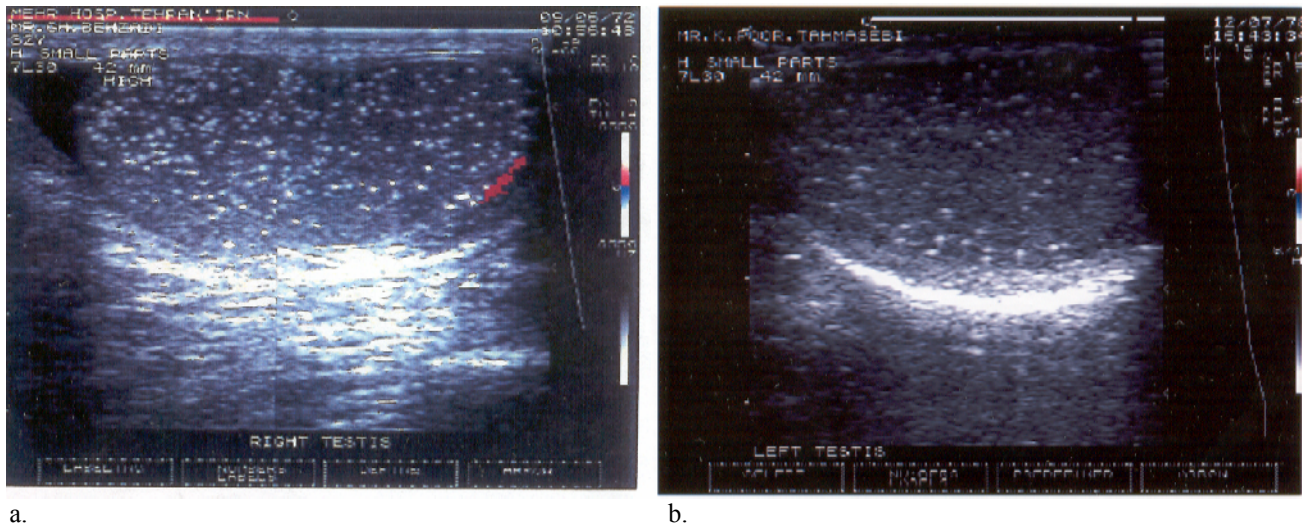


Figure 1: Typical sonographic appearance of testicular microlithiasis in different patients. Note more profuse microliths in figure 'a' in a patient with azoospermia

The presence of TM was based on consensus reports of two abdominal radiologists, using accepted typical sonographic criteria for the diagnosis of TM as described by Backus et al.¹⁴

Those sonographically suspected of testicular tumors were evaluated by histopathologic studies.

The prevalence of TM and the relative risk of concurrent testicular tumors were then calculated in the study population.

Result

TM was detected in 15 patients, a value that translates into a prevalence of 0.7%. Four (27%) of these 15 patients were found to have testicular tumors; one had seminoma and three had mixed germ cell tumors (Figure 2).

The age range of patients with concurrent TM and tumor was 21–43 (mean: 34) years.

Discussion

TM was first reported by Priebe and Garret² in 1970 in a healthy 4-year-old boy. Later on, Doherty *et al*, gave the first description of sonographic description of TM in 1987.⁵ The exact cause of TM, however, remains undetermined. The microliths are believed to originate from degenerated intra-tubular cells and are composed of two main zones; a central calcified core and a multilayered covering of collagen fibers. Microlithiasis is thought to result from defective phagocytosis of degenerated tubular cells by Sertoli cells.³

The questions remain as to whether the presence of microliths indicates abnormal tubular epithelium and

Sertoli cell dysfunction, or that their presence provokes epithelial changes.

TM occurs within the testicular parenchyma and may be distributed peripherally or segmentally. Microliths usually occur bilaterally. However, unilateral cases have also been reported.¹² Currently, TM is most commonly diagnosed by high-frequency (5 to 10 MHz) testicular ultrasound.⁴ In one reported series, the histopathologic confirmation was not possible in one half of the patients with TM.¹⁴

On sonography, testicular microlithiasis appears as multiple tiny (2 to 3 mm), non-shadowing echogenic foci that are randomly scattered throughout the testicular parenchyma (Figure 1). The number of microliths required to define TM has been arbitrary. Nevertheless, the current consensus is to accept five or more on a single sonogram as the cut-off value.¹⁴⁻¹⁵

When a patient has fewer than five microliths, the condition is referred to as "limited TM."¹⁶ Doppler studies revealed no specific findings in those with TM.

Small localized areas of calcification have long been recognized in benign processes of the testis such as inflammatory scars, granulomata, infection and hemorrhage.¹⁴ Similarly, variable testicular calcifications are often sonographically evident in testicular tumors. However, they do not tend to show the characteristic configuration of TM as previously described.¹¹ So far, several associations have been reported with TM including Klinefelter's syndrome, cryptorchidism, Down's syndrome, male pseudohermaphroditism, pulmonary alveolar microlithiasis, previous radiotherapy and subfertility state.⁴⁻⁸

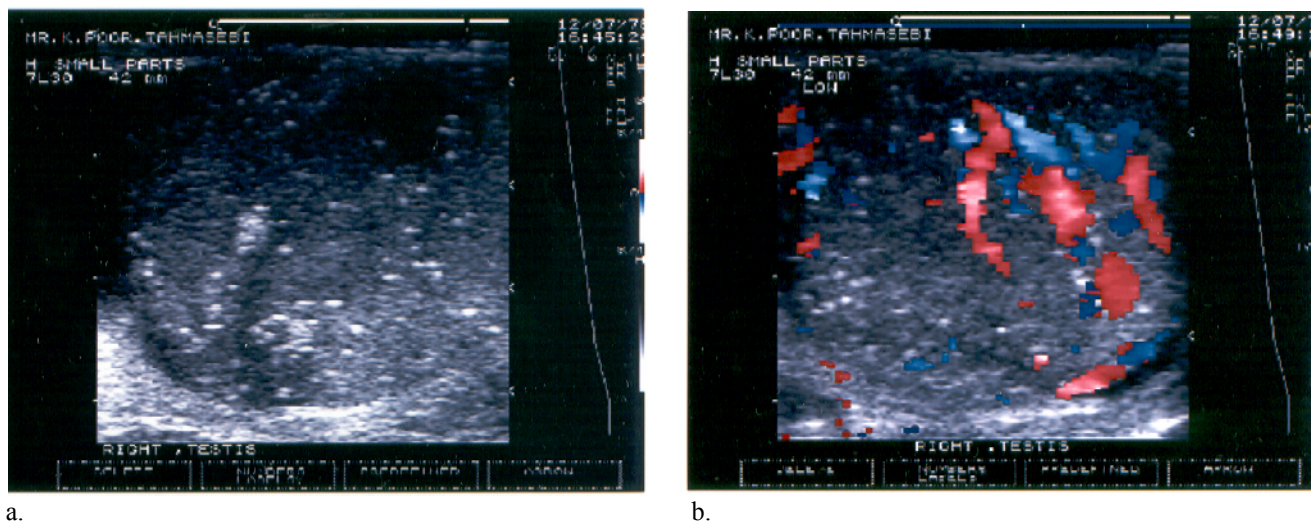


Figure 2: Scrotal sonography in a 40-year-old man who presented with a right testicular mass. Sonographic study showed TM associated with a hypoechoic mass lesion in the right testicle (Figure 'a'). Color Doppler examination revealed hypervascularity in testis (Figure 'b'). Histopathologic study revealed mixed germ cell tumor.

Nonetheless, the most important association reported is that with testicular neoplasm.^{14,17} Backus and Hobart *et al*,^{9,14} reported as much as 40% to 45% occurrence of germ cell tumors with TM at the time of tumor diagnosis. Of particular importance is the report of one series consisting of 21 patients with testicular tumor and intra-tubular germ cell neoplasia in which 14 (67%) were found to have sonographically identifiable TM in the ipsilateral testis.¹³

Despite a compelling association between tumor, intra-tubular germ cell neoplasia and TM, there are few reports of tumor developing in the setting of testicular microlithiasis. This subject was recently reviewed by Ganem *et al*,¹⁸ who followed five patients with TM in whom tumor had arisen between 10 months and 11 years after the diagnosis of microlithiasis.^{15,16,19-21}

Previous reports have indicated a 0.68% prevalence of TM in the population referred for scrotal sonography.¹¹ In our referred population, we found testicular microlithiasis in 0.7% of patients. The mean age of our patients presenting with TM alone (34 yrs) was higher than that previously reported (22.3 yrs)²². In this study, the mean age of patients with concurrent TM and testicular tumor was 34 years (Range: 21–43 yrs).

Conclusions

Since it is strongly probable that TM may be associated with certain testicular neoplasms, a hypothesis supported by recent literature, it is strongly suggested to follow those with TM with physical examination and ultrasonography at least annually and to encourage self-examination.

References

1. Patel MD, Olcott EW, Kerschmann RL, Callen PW et al. Sonographically detected testicular microlithiasis and testicular carcinoma. *J Clin Ultrasound* 1993;21:447-452.
2. Priebe CJ Jr, Garret R: Testicular calcification in a 4-year-old boy. *Pediatrics* 1970; 46:785-786
3. Vegni-Talluri M, Bigliardi E, Vanni MG, Tota J: Testicular microlithiasis: their origin and structures. *J Urol* 1980;124:105-107
4. Janzen DL, Mathieson JR, Marsh JI, et al: Testicular microlithiasis: Sonographic and clinical features. *AJR* 1992;158:1057-1060
5. Doherty FL, Mullins TL, Sant GR, et al: Testicular microlithiasis : a unique sonographic appearance. *J Ultrasound Med* 1987;6:389-3929.
6. Hobarth K, Szabo N, Klingler Hc, Kratzik C: Sonographic appearance of testicular microlithiasis . *Eur Urol* 1993;24:251-255
7. Coetzee T: Pulmonary alveolar microlithiasis with involvement of the sympathetic nervous system and gonads. *Thorax* 1970;25:637-642
8. Nistal M, Paniagua R, Diez-pardo JA: Testicular microlithiasis in 2 children with bilateral cryptorchidism . *J Urol* 1979;121: 535-537
9. Hobarth K, Susani M, Szabo N, Kratzik C: Incidence of testicular microlithiasis. *Urology* 1992;40:464-467
10. Emberton P. Moody AR: Testicular microlithiasis . (letter) *AJR* 1994; 162:1002-1003
11. James E.I., cast, William M. Nelson, Alan S. Early, et al: Testicular Microlithiasis: Prevalence and Tumor Risk a Population Referred for Scrotal Sonography. *AJR* 2000;175:1703-1706
12. Furness P.D, Husmann D.A, Brock J.W et al: Multi-institutional study of testicular microlithiasis in childhood: A benign or premalignant condition. *J Urol* 1998;160:1151-1154
13. Song FL, Middleton WD, Winter TC III ,et al: Association between intratubular germ cell neoplasia and testicular microlithiasis .(abstr) *Radiology* 1993;189(p):156
14. Backus ML, Mack LA; Middleton WD, et al: Testicular microlithiasis: imaging appearances and pathologic correlation. *Radiology* 1994;192:781-785
15. Frush DP, Kliever MA, Madden JF: testicular microlithiasis and subsequent development of metastatic germ cell tumor. *AJR* 1996;167:889-890

16. Winter TC, Zunkel DE, Mack LA: Testicular carcinoma in a patient with a previously demonstrated testicular microlithiasis . J Urol 1996;155:648
17. Roberts ISD , Lougharn CF: Case report; the ultrasound appearances of testicular microlithiasis (" snow storm" testis) : a case complicated by testicular seminoma. Clin Radiol 1993;47:65-67
18. Ganem JP Workman KR, Shaban SF: Testicular microlithiasis is associated with testicular pathology . Urology 1999;53:209-213
19. McEniff N, Doherty F, Katz J, et al: Yolk sac tumor discovered on a routine annual sonogram in a boy with testicular microlithiasis. AJR 1995;164:971-972
20. Salisz JA Goldman KA: Testicular calcifications and neoplasia in patient treated for subfertility. Urology 1990; 36:557-560
21. Gooding GA: Detection of testicular microlithiasis by sonography. (letter) AJR 1997;168:281-282
22. Miller RI, Wissman R, White S, Ragosin R: Testicular microlithiasis : a benign condition with a malignant association. J. Clin Ultrasound 1996;24:197-202