

R. Malek MD,  
A. Padidar MD.

## Uterine Fibroid Embolization

**Abstract:** Uterine fibroids are commonly asymptomatic. They often cause pelvic pain, abnormal and increased vaginal bleeding, etc. Traditional treatment of symptomatic uterine fibroids was trans-abdominal hysterectomy. Nowadays, uterine artery embolization (UAE), also called uterine fibroid embolization, is considered as a safe and highly-effective non-surgical treatment for women with symptomatic uterine fibroid tumors. Advantages of UAE over conventional hormonal suppression and surgical procedures include avoidance of the side effects of drug therapy and surgery-related physical and psychological trauma. These patients commonly resume their normal activities within a week after the procedure; weeks earlier than that for trans-abdominal hysterectomy. Over the past 30 years, interventional radiologists have done UAE for treatment of emergency uterine bleeding. Since 1995, interventional radiologists have turned their attention to treatment of uterine fibroids with a similar procedure. The first fibroid embolization in Iran was done approximately three years ago. So far, more than 100 cases have been treated by this method and it is going to be quickly accepted as a safe alternate for surgery.

**Keywords:** Leiomyoma; Radiology, Interventional, Embolization, therapeutic

### Introduction

Uterine fibroids are commonly asymptomatic. They often cause pelvic pain, abnormal and increased vaginal bleeding, infertility and pressure-related symptoms like low back pain, urinary frequency and constipation. In most countries, more than 50% of trans-abdominal hysterectomies are done for treatment of symptomatic uterine fibroids. Nowadays, as an alternative to hysterectomy, uterine artery embolization (UAE) is used. It avoids the surgery-related complications and side effects that include a six-week recovery period, a 2% risk of developing postoperative bleeding and a 15% to 38% risk of developing a postoperative febrile illness.<sup>2</sup> A decrease in sexual function, depression and an increased incidence of cardiovascular disease have also been reported following hysterectomy.<sup>2</sup>

Alternative uterine-sparing treatments in women include myomectomy, myolysis hysteroscopic resection and endometrial ablation have been already performed by gynecologists. Table 1 shows different aspects of UAE with other uterine-sparing therapies.

### Patient Selection

The ideal candidate for UAE is a premenopausal woman with symptomatic uterine fibroids who strongly desires to avoid hysterectomy. Patients with a contraindication to general anesthesia might also benefit from UAE. Although there is no fixed size limitation, patients with pedunculated subserosal fibroids are not considered as ideal candidates. UAE is particularly a good therapeutic option for patients who wish to avoid the possibility of blood transfusions for health or religious reasons.<sup>24</sup>

From  
Minimally Invasive Surgical  
Solutions, 455 O'Connor Drive,  
Suite 390, San Jose, CA, USA.  
Corresponding Author:  
Dr. Reza Malek, Minimally Invasive  
Surgical Solutions, 455 O'Connor  
Drive, Suite 390, San Jose CA  
95128.  
E-mail:  
malek@endovascularsugery.com

## Uterine Fibroid Embolization

**Table 1:** Uterine-Sparing Treatment Options for Patients with Symptomatic Uterine Fibroids

Treatment	Description	Advantages	Disadvantages
GnRH therapy	Medical therapy to suppress estrogen production and shrink uterine fibroids	Shrinkage of uterine fibroids may allow removal with less blood loss, or removal by laparoscope or hysteroscope	Induces premature menopause-like symptoms; associated with premature bone mineral loss <sup>3</sup> ; rapid regrowth of fibroids when therapy is discontinued
Abdominal myomectomy	Open abdominal surgery to resect symptomatic uterine fibroids	Allows uterine conservation, usually in women who desire fertility	Postoperative recovery period of six weeks; general anesthesia required; transfusion rate of 3 to 20 percent <sup>3,4</sup> ; adhesions may cause problems <sup>5</sup> ; recurrence rate of 10 to 27 percent <sup>5,6</sup>
Laparoscopic myomectomy	Laparoscopic removal of uterine fibroids	Much shorter recovery period than with abdominal myomectomy; best suited for pedunculated and subserosal fibroids or smaller intramural fibroids <sup>7,8</sup>	Large, multiple or deep uterine fibroids are problematic; procedure-related adhesion formation may be significant; general anesthesia required <sup>7,8</sup>
Laparoscopic myolysis	Laser probe used to heat coagulate uterine fibroids	Treated uterine fibroids may shrink up to 40 percent by 6-month follow-up <sup>7</sup>	"Dense and fibrous adhesions" noted at second-look laparoscopy <sup>7*</sup>
Hysteroscopic resection and/or endometrial ablation	Hysteroscope is inserted into endometrial cavity, guiding the resection of submucous fibroids; endometrium is scraped and burned to create amenorrhea	Outpatient procedure for bleeding patients; short recovery period	Mortality from fluid overload and infection reported but rare; a 32 percent failure rate reported at 2 years post-ablation <sup>9</sup> with a high rate (52 percent) of adenomyosis, possibly caused by ablation <sup>10</sup> ; destroys fertility potential; a 13 percent rate of synechiae formation following hysteroscopic resection without ablation <sup>10</sup>
Abdominal Hysterectomy	Open abdominal surgery to remove the entire uterus with or without ovaries	No recurrence of fibroids, removal of ovaries potentially beneficial in patients close to menopause, removes potentially cancerous tissue	Six weeks recovery period, 2% risk of post operative bleeding, 15% to 38% risk of post operative febrile illness <sup>2</sup>
Uterine fibroid embolization	An arteriographic catheter is passed through the femoral artery into the uterine arteries; tiny particles are injected that block blood flow inside the fibroids and cause infarct; other uterine structures are spared; uterine fibroids shrink, relieving symptoms	Abnormal bleeding and "bulk symptoms" improved in about 80 to 90 percent of patients <sup>11,12</sup> ; surgical incision and general anesthesia not required; no blood loss; all fibroids treated at once <sup>13</sup> ; no recurrences noted <sup>14†</sup> ; return to normal activities in 7 to 10 days	As expensive as hysterectomy; effect on fertility uncertain; delayed infection may occur in a small percentage of patients; availability to all patients may be limited‡; long-term follow-up data unavailable; some HMOs may not cover procedure cost

GnRH = Gonadotropin-releasing hormone; HMOs = health maintenance organizations.

\*--The results from one study revealed that these adhesions occurred between uterine fibroids and the small bowel.

†--The results from one study revealed no recurrence of uterine fibroids over 6-year period; however, further studies are needed to determine if this procedure is as durable as other uterine-conserving procedures.

‡--The availability of this procedure may be limited.

Information from references 3 through 14.

Myomectomy has been the traditional treatment for women desiring future pregnancy. Effect of UAE on future pregnancy is currently under investigation however, pregnancies that have occurred after UAE appear to have been uneventful. Depending on the size and number of uterine fibroids, a myomectomy procedure may not be feasible. In these patients, uterine fibroid embolization will allow uterine preservation.

## Preoperative Evaluation

Before performing UAE, a thorough gynecologic evaluation is needed to determine if the uterine fibroids are the direct cause responsible for the patient's symptoms.

A pelvic ultrasound or MRI is needed to evaluate the uterus and to exclude other pathologies. Most patients with menorrhagia need to undergo an endometrial biopsy to exclude endometrial carcinoma, unless MRI or ultrasound unequivocally excludes any endometrial pathologies. UAE is contraindicated in patients with active pelvic infection, renal insufficiency or a history of severe allergy to iodinated contrast material.

## UAE Technique

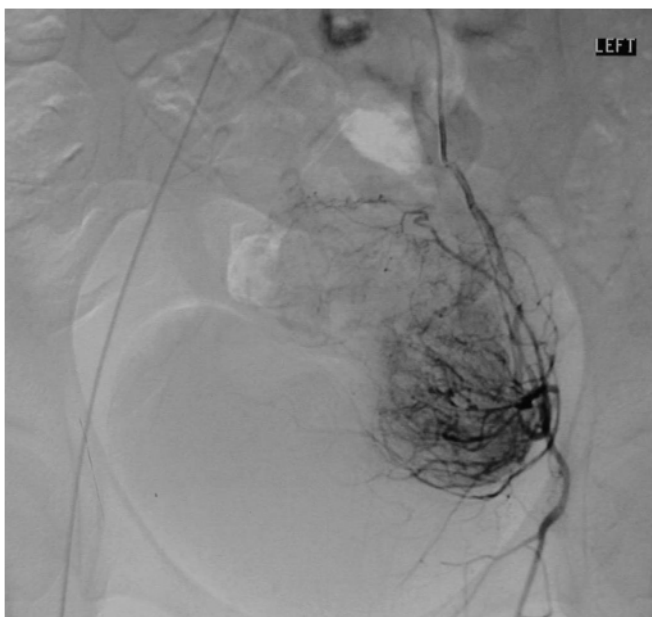### Pain Management

Patient is usually admitted on morning of the procedure to the hospital. Mild intravenous sedation with versed and fentanyl is usually used during the

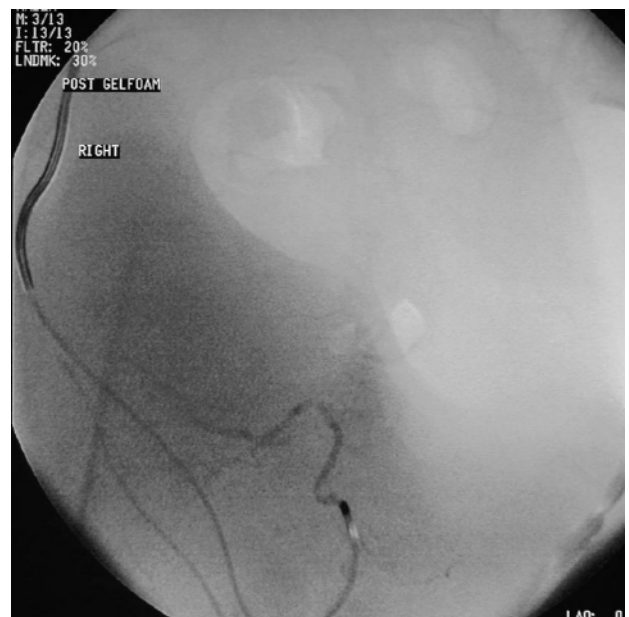
procedure. Anti-inflammatory medications are started in the angiography suite or prior to the procedure and continued for 2 weeks (e.g. 400-600 mg Motrin, TID). A morphine pump is set up during the procedure and started towards the end of the procedure. Alternatively, regular regiment of IV medication should be written for the next 12 hrs. It is much easier to stay ahead of pain than to try to catch up after patient is uncomfortable and in pain. PRN or anticipatory anti-emetics should also be written as patients commonly become nauseated at termination of the embolization.

### Catheter Technique:

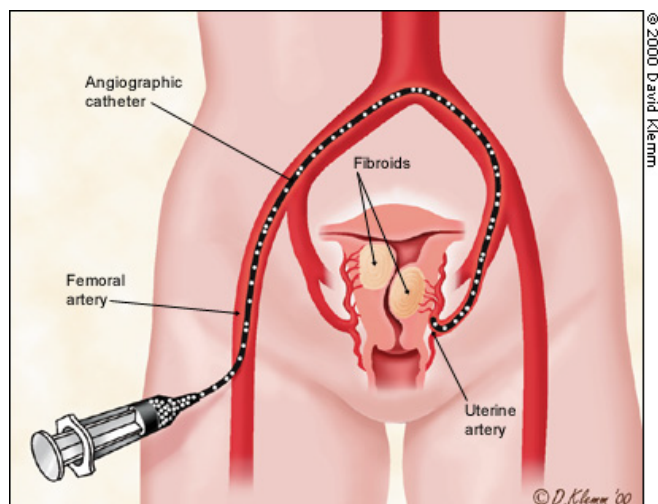
Right common femoral access is obtained. A 5 or a 6 French sheath is placed. Four or 5 French curved Levine or Cobra catheter is placed over a wire. This catheter is used to gently get access to the origin of contra-lateral internal iliac artery (Figure 1) over a guide wire. A large inner diameter micro-catheter is inserted via this catheter, through a side-angle which is used to catheterize the ovarian artery (Figure 2a). Few practitioners use a 4 or 5 French catheter to gain access to the uterine artery which runs the risk of vasospasm during the treatment and hence, treatment failure. Delay of approximately 20 minutes and possible use of vessel dilators may prove useful. Tiny particles of polyvinyl alcohol (PVA), or embosphere (Biosphere Medical, Rockland, MA USA) approximately 500  $\mu$ m in diameter, are injected in slurry into the artery (Figure 2b).



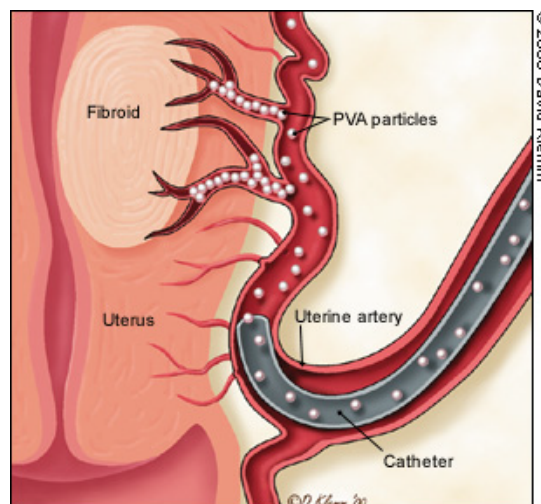
**Figure 1:** Digital subtraction arteriogram of the left uterine artery showing the hypervascular arterial supply of a large fibroid.



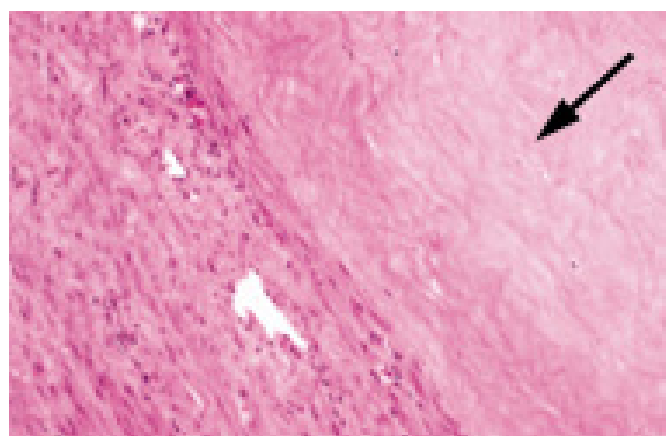
**Figure 2a.** Micro-catheter noted coaxially through a 5 French Cobra catheter in the ipsilateral uterine artery during injection of PVA particles.



**Figure 2b.** Embolization preparation. A tiny angiographic catheter is maneuvered into the uterine artery in preparation for embolization. Photo courtesy of SIR



**Figure 2c.** Injection. Polyvinyl alcohol particles of 500 µm in diameter are injected and enter the abnormal arteries in the uterus. Photo courtesy of SIR



**Figure 3:** H and E preparation of the post-embolization uterus (hysterectomy was performed for another diagnosis). Intact viable myometrium is shown adjacent to an embolized fibroid. The fibroid shows complete hyaline degeneration (arrow).

The process is repeated for the right uterine artery. PVA or microspheres flow into the hypervascular uterine fibroids (Figure 2c), block small arteries and cause ischemic necrosis. Normal myometrium is unharmed because it is supplied by multiple collateral arteries. A pathology section showing the effect of embolization on a fibroid and on a normal myometrium is shown in Figure 3. After the right and left uterine arteries are embolized, the catheter is removed, and the patient undergoes standard post-arteriographic monitoring and recovery.(Figure 4)

### Radiation Exposure

Radiation dose is an obvious concern. It falls within acceptable limits in experienced hands. Having state of the art angiographic equipments with road mapping and pulse fluoroscopy would significantly reduce the radiation exposure. Techniques like field conning, use of pulse fluoroscopy, bilateral

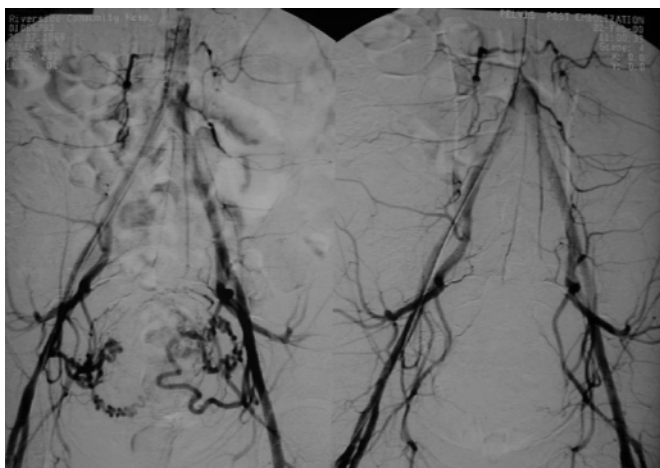
catheter placement with simultaneous embolization and not using magnification imaging, can reduce the radiation significantly.(bb) Operator experience is also an important factor. Mean radiation exposure during fibroid embolization is approximately that of pelvic radiation dose of 6000 cGy.cm<sup>2</sup> for a barium enema in the UK1.25.

## Results

### Short-Term Results

Total uterine volume decreases an average of 50%.<sup>11,12</sup> Infarcted uterine fibroids undergo variable shrinkage that averages 48% to 78% in volume.<sup>11</sup> At six-month follow-up, the size of the uterus has decreased by 50%. Between 81% and 92% of patients with fibroid-related menorrhagia who were treated with UAE reported a significant improvement or resolution of abnormal uterine bleeding, while 79% to 92% of patients with bulk symptoms reported significant improvement.<sup>11,12</sup> Resumption of normal activities within four days was reported in 80% of patients, and 90% of patients reported a resumption of normal activities within 10 days.<sup>12,19</sup> In one series<sup>12</sup> of 305 patients treated with UAE, 86% indicated satisfaction with the results of the procedure.

Effect of UAE on pregnancy is not well-studied. However, patients who have got pregnant have carried out an uneventful pregnancy. One group of 27 women who underwent UAE for emergency hemorrhage reported no adverse effects on menses or fertility on follow-up evaluation.<sup>20</sup> However, premature menopause induced by the procedure has been reported.



**Figure 4:** DSA of both iliac arteries before and after uterine artery embolization.

### Long-Term Results

The long-term effectiveness of UAE is still unknown. However, we know that patients who have undergone a surgical myomectomy for uterine fibroids face a 10% to 27% recurrence rate.<sup>5,6</sup> Recently, the results of a study on 184 patients who had undergone UAE over a six-year period were presented.<sup>14</sup> No recurrences were noted in this group of patients. More follow-up is needed to determine whether UAE will prove to be more durable than myomectomy or any other uterine-conserving surgical procedures.

### Side Effects and Complications

Immediate pain after the procedure is expected and should be treated as a sign of success rather than a complication. In fact, I will review the images more carefully and look for collateral vessels in patients who do not experience any pains after completion of embolization of both uterine arteries. Morphine pumps or a regular IV regimen of narcotics has become the preferred method of pain control for many practitioners. Over night observation for pain management is common but not a must. The pain diminishes during the first week following UAE, and patients can be maintained on oral analgesics. Approximately 15% to 30% of patients may experience a variable "post-embolization syndrome," with fever and malaise occurring during the first few weeks. This syndrome, that may be attributed to the release of tissue-breakdown products from degenerating uterine fibroids, however, resolves spontaneously.<sup>17</sup>

Serious infections are uncommon. A review of four series with a total of 751 patients reveals that 0.7% of patients developed infection or severe ischemia requiring hysterectomy.<sup>3,11,12,21</sup> Less severe infections may occur more commonly and may be managed without hysterectomy.<sup>21</sup> One death of sepsis has been

reported in the literature out of approximately 6,500 procedures performed worldwide.<sup>22</sup> Occasionally, submucosal fibroids become necrotic and may be expelled from the uterus following UAE.

Amenorrhea and post-procedure menopause occurs in 2% to 15% of patients.<sup>3,19</sup> Risk of menopause is increased by increasing age of the patient. Radiation exposure to the ovaries may be as high as 20 cGy with the use of continuous fluoroscopy.<sup>23</sup> This amount is equivalent to approximately five computed tomographic (CT) scans of the pelvis. Using modern intermittent fluoroscopy, however, much lower doses would be expected.<sup>23</sup> Non-target embolization is another potential complication. This complication has not yet been reported in association with UAEs performed in the United States.

### Advantages of UAE

UAE has several potential advantages over hysterectomy, myomectomy and hormonal suppression. Unlike myomectomy or hysterectomy, UAE involves virtually no blood loss or risk of blood transfusion.<sup>2,4,5</sup> General anesthesia and surgical incisions are avoided. Recovery is weeks shorter than recovery from hysterectomy or open myomectomy (seven to 10 days vs six weeks),<sup>2,5,19</sup> and early menopause-like symptoms that are often seen in treatment with gonadotropin-releasing hormone (GnRh) are rarely observed with UAE. All fibroids are treated at once, which is not the case with myomectomy.<sup>13</sup> Recurrence appears to be lower in UAE than myomectomy.<sup>14</sup>

### Availability in Iran

UAE is rapidly becoming a viable option for women with symptomatic fibroids and who desire to keep their uterus and limiting their surgical risk. Results on rate and risks of pregnancy should become available soon. Proper interventional training courses are scarce and not readily available in Iran. Obviously, with lack of appropriate training, risks of these seemingly minimally-invasive procedures might increase. Organized and supervised training sites need to be formed in the country for interventional radiology training. Conferences with emphasis on interventional radiology with detailed workshops and visiting professors from abroad would also certainly aid in training our physicians.

Another stumbling block for interventional radiologists associated with UAE is that it is currently somewhat difficult for women to learn about the procedure. Some gynecologists may be unfamiliar with it or may counsel patients to stay with the tried and true surgical procedures due to lack of knowledge, expertise of interventionalist or monitoring

reasons. Currently, UAE is being performed widely in the United States, Canada and Europe. A directory of physicians who can do this procedure in Iran should be available to consumers. Interventional radiologists traditionally do not admit patients to the hospital and do not keep patient charts and records. As practice of interventional radiology grows, adjustments in the practice need to be made so that the interventionalist is more clinically inclined and involved with the patients care. For more information about this and other interventional procedures you can visit our web site at <http://www.endovascularsurgery.com>.

## Acknowledgments

The authors thank Ana Avila aid in preparation of the manuscript.

1. Broder MS, Kanouse DE, Mittman BS, Bernstein SJ. The appropriateness of recommendations for hysterectomy. *Obstet Gynecol* 2000;95:199-205.
2. Greenberg MD, Kazamel TI. Medical and socioeconomic impact of uterine fibroids. *Obstet Gynecol Clin North Am* 1995; 22:625-36.
3. Ravina JH, Bouret JM, Ciraru-Vigneron N, Repiquet D, Herbreteau D, Aymard A, et al. [Recourse to particular arterial embolization in the treatment of some uterine leiomyoma.] *Bull Acad Natl Med* 1997; 181:233-436.
4. LaMorte AI, Lalwani S, Diamond MP. Morbidity associated with abdominal myomectomy. *Obstet Gynecol* 1993;82; 897-900.
5. Hutchins FL. Abdominal myomectomy as a treatment for symptomatic uterine fibroids. *Obstet Gynecol Clin North Am* 1995; 22:781-9.
6. Candiani GB, Fedele L, Parazzini F, Villa L. Risk of recurrence after myomectomy. *Br J Obstet Gynaecol* 1991; 98:385-9.
7. Donnez J, Mathieu PE, Bassil S, Smets M, Nisolle M, Berliere M. Laparoscopic myomectomy today. *Fibroids: management and treatment: the state of the art. Hum Reprod* 1996; 11:1837-40.
8. Dicker D, Dekel A, Orvieto R, Bar-Hava I, Peleg D, Ben-Rafael Z. The controversy of laparoscopic myomectomy: *Hum Reprod* 1996; 11:935-7.
9. A Scottish audit of hysteroscopic surgery for menorrhagia: complications and follow-up. *Scottish Hysteroscopy Audit Group. Br J Obstet Gynaecol* 1995; 102:249-54.
10. Hallez JP. Myomectomies by endo-uterine resection. *Curr Opin Obstet Gynecol* 1996;8:250-6.
11. Spies JB, Scialli AR, Jha RC, Imaoka I, Ascher SM, Fraga VM, et al. Initial results from uterine fibroid embolization for symptomatic leiomyomata. *J Vasc Interv Radiol* 1999; 10:1149-57.
12. Hutchins FL, Worthington-Kirsch R, Berkowitz RP. Selective uterine artery embolization as primary treatment for symptomatic leiomyomata uteri. *J Am Assoc Gynecol Laparosc* 1999; 6:279-84.
13. Smith SJ, Sewall LE, Handelsman A. A clinical failure of uterine fibroid embolization due to adenomyosis. *J Vasc Interv Radiol* 1999; 10:1171-4.
14. Ravina J, Ciraru-Vigneron N, Aymard A, Ledreff O, Herbreteau D, Merland J. Arterial embolization of uterine myomata: results of 184 cases. Presentation at 10th Anniversary International Conference for the Society for Minimally Invasive Therapy; September 4, 1998; London, England. *MITAT* 1998;7 (suppl):26-27 Abstract.
15. Heaston DK, Mineau DE, Brown BJ, Miller FJ. Transcatheter arterial embolization for control of persistent massive puerperal hemorrhage after bilateral surgical hypogastric artery ligation. *Am J Roentgenol* 1979; 133:152-4.
16. Ravina JH, Herbreteau D, Ciraru-Vigneron, Bouret JM, Houdart E, Aymard A, et al. Arterial embolisation to treat uterine myomata. *Lancet* 1995; 346:671-2.
17. Goodwin SC, Vedantham S, McLucas B, Forno AE, Perrella R. Preliminary experience with uterine artery embolization for uterine fibroids. *J Vasc Interv Radiol* 1997;8:517-26 [Published erratum appears in *J Vasc Interv Radiol* 1999;10:991].
18. Castaneda-Zuniga WR, Sanchez R, Amplatz K. Experimental observations on short and long-term effects of arterial occlusion with Ivalon. *Radiology* 1978; 126:783-5.
19. Worthington-Kirsch RL, Popky GL, Hutchins FL. Uterine arterial embolization for the management of leiomyomas: quality-of-life assessment and clinical response. *Radiology* 1998; 208:625-9.
20. Stancato-Pasik A, Mitty HA, Richard HM 3d, Eshkar N. Obstetric embolotherapy: effect on menses and pregnancy. *Radiology* 1997; 204:791-3.
21. Walker W, Green A, Sutton C. Bilateral uterine artery embolization for myomata results, complications and failures. *Mitat* 1999;8.
22. Vashisht A, Studd J, Carey A, Burn P. Fatal septicaemia after fibroid embolisation. [Letter] *Lancet* 1999; 354:307-8.
23. Awa AA, Honda T, Neriishi S, Sufuni T, Shimba H, Ohtaki K, et al. Cytogenetic study of the offspring of atomic bomb survivors. Hiroshima and Nagasaki. In: Obe G, Basler A, eds. *Cytogenetics: basic and applied aspects*. New York: Springer-Verlag, 1987:166-83.
24. Goodwin SC, Walker WJ. Uterine artery embolization for the treatment of uterine fibroids. *Curr Opin Obstet Gynecol* 1998;10:315-320
25. Nikolic B., Spies JB, Campbell L, Walsh SM, Abbara S, Lundsten MJ. Uterine artery embolization: reduced radiation with refined technique. *J Vasc Interv Radiol* 2001;12:39-44