

Aliakbar Ameri, MD^a
Mohammad Hadi Bagheri, MD^b
Jalal Jalal Shokouhi, MD,^c
Farrokh Habibzadeh, MD^d

Spinal Cord Compression Secondary to Extramedullary Hematopoiesis in Thalassemia

Background/Objective: Extramedullary hematopoiesis (EMH) is a physiological response to chronic anemia and may rarely cause spinal cord compression. Herein, we describe 9 thalassemic patients presenting with signs and symptoms of cord compression either due to epidural mass or spinal canal stenosis secondary to bone widening. Since this emergency condition can be readily diagnosed by MRI and has medical rather than surgical treatment, i.e., blood transfusion and/or low dose radiation therapy, physicians should also be aware of EMH in patients with signs and symptoms of spinal cord compression, particularly in areas endemic for thalassemia.

Results: 7 patients with thalassemia intermedia are treated medically and only by oral folic acid and symptoms disappeared within 2-3 weeks. "None of the seven patients were diagnosed before from point of thalassemia." Two patients were diagnosed as major thalassemia.

Conclusion: About young patient in endemic areas for thalassemia who have cord compression signs and symptoms, thalassemia variants or undiagnosed minor thalassemia should be evaluated.

Keywords: Thalassemia, Extramedullary Hematopoiesis, Spinal cord compression, Paraplegia, MRI

Introduction

Thalassemia is the most common monogenic autosomal hereditary disease affecting tens of thousands of people worldwide.^{1,2} Individuals heterozygous for the diseased gene, usually have a normal life span and do not have any major problem with their daily activities. Homozygous individuals, on the other hand, develop severe life-threatening anemia starting from early childhood. To stay alive, these patients should receive regular blood transfusion, lifelong. Almost 15% of homozygous patients, however, have milder degrees of anemia and do not require regular blood transfusion.³ This clinical presentation, the so-called thalassemia intermedia, among other mechanisms is usually the result of co-inheritance of two different diseased genes.

Thalassemias, are heterogenous at the molecular level. To date, more than 150 different mutations for β -gene, and around 23 mutations for α -gene have been identified. Compound heterozygosity of these different genes may cause a spectrum of defects in hematopoiesis machinery and clinical presentations. Those with thalassemia intermedia, although not bound to regular blood transfusion, must receive special medical attention. Extramedullary hematopoiesis (EMH) is frequent in these patients and once thalassemia is suspected clinically, the diagnosis can be made by imaging modalities especially MRI.¹

EMH is a physiological response to chronic anemia.⁴ In most instances, it remains asymptomatic, infrequently it can be manifested by compression of adjacent organs.⁵ EMH commonly occurs in liver and spleen, Rarely, however spinal cord compression may be encountered. To date, only 75 cases of spinal cord compression by EMH has been described in medical literature.^{4,6,7} The condition is reasonably, more often observed in regions where thalassemia is

From

a. Shahid Beheshti Medical
University, Tehran, IRAN

b. Nemazee Hospital, Shiraz
University of Medical Sciences,
Shiraz, IRAN

c. Iranian Society of Radiology,
Tehran, IRAN

d. NIOC Medical Education and
Research Center, Shiraz, IRAN

Correspondance:

M.H. Bagheri MD

Department of Radiology

Nemazee Hospital

PO Box 71345-1339

Shiraz, Iran

Tel: +98-711-6263233

Fax: +98-711-6261000

E-mail: dr_shokouhi@yahoo.com

more prevalent. Thalassemia is found in some 60 countries with the highest prevalence in the Mediterranean basin, parts of North and West Africa, the Middle East, the Indian subcontinent, southern Far East and southeastern Asia.

Altogether they composing the so-called "thalassemia belt." In western countries, thalassemia affects mostly individuals whose ancestries are traceable to a high prevalence area.¹

Distribution of the disease is not uniform even in the thalassemia belt. Almost 150 million people worldwide carry β -thalassemia genes which are particularly prevalent in Italy and Greece.¹

Iran, located in the center of the Middle East, and on the route of that ancient *Road*, has been the meeting place of the Eastern and Western civilizations, and like many other countries in the region, harbors a large number of patients with major thalassemia.^{1,2} The Silk Road has helped dissemination of the diseased gene through its path from the East to the West. This hypothesis appears more plausible when we consider that the disease gene frequency drops when from east to west along that commercial road.

During its long history, Iran has been colonized several times, with an ultimate result of emergence of an unexpectedly high number of different mutations that account for β -thalassemia in this country.¹ Considering the diversity of gene mutations responsible for β -thalassemia in Iran, the chance of co-inheritance of two different diseased genes and hence the development of individuals with thalassemia intermedia has risen in the region.

In this report, we describe our experience with nine cases of spinal cord compression by EMH from Iran.

Case Presentations

Case 1: A 22-year-old man presented with paraplegia which has started a few days before. Dorsal MRI disclosed widening of the medullary canal and decreased bone marrow signal both in T1 and T2 weighted images, accompanied by a large epidural mass (Figure 1). The patient was found to have thalassemia intermedia. He showed a good response to folic acid therapy alone.

Case 2: A 15-year-old female was brought into the Emergency Department complaining of paraplegia of 3 days duration. She underwent a dorsolumbar MRI. The study revealed a paravertebral mass in upper thoracic region (Figure 2-A), a presacral mass, an epidural sacral mass and low signal of vertebral bodies on T2-weighted images (Figure 2-B). She was found to have thalassemia intermedia.

Case 3: A 27-year-old man with thalassemia major presented with abnormal densities on chest x-ray.

On chest CT he had thoracic canal stenosis along with widening of the bony structures, particularly of his ribs.

Case 4-9: These patients were between 11 and 23 years of age, with thalassemia, either major or intermedia, all presented with extradural spinal canal masses apparent on their dorsolumbar MRI. The masses were compatible with extramedullary hematopoiesis with or without canal stenosis.

Discussion

EMH occurs in a variety of hematologic disorders. Although EMH is a rare cause of epidural mass, it should be considered in those regions where thalassemia is endemic.⁷

The development of symptoms in patients with EMH and epidural mass depends on the duration of disease and that is why most of the reported cases have become symptomatic in their third or fourth decades of life, while cases 2, 4, 5, 6, 8, and 9 of our series, presented with neurologic symptoms in their second decade of life.

In 1954, Gatto *et al* reported the first case of cord compression caused by EMH in a patient with heterozygous β -thalassemia.⁸ In that case, the diagnosis was made after histopathologic study of the surgically excised specimen. The surgical decompression was then followed by radiation therapy because there was incomplete relief of symptoms.

Thereafter, other cases of EMH have been reported using different diagnostic methods and therapeutic modalities.^{9, 10} Numerous mechanisms have been proposed for the genesis of epidural EMH including direct extension from vertebral body bone marrow, embolic phenomena, and stimulation of embryonic pluripotential hematopoietic stem cells.¹¹

Although, there are several reports of spinal cord compression by EMH from Iran,^{6,7,9} the current report is the second largest series of such cases in the literature.^{12,13}

Most of our patients were in their second decade of life and were from regions where thalassemia is prevalent,^{1,2} Most of them belonged to low socio-economic class, and had both delayed referral and delayed diagnosis (Table 1).

Spinal cord compression is a medical emergency and needs prompt attention. In case of the development of cord compression by EMH, early diagnosis and treatment is crucial for prevention of severe irreversible neurologic complications. Early diagnosis will affect the course of management and may reduce the incidence of irreversible neurologic damage that would otherwise occur with prolonged undiagnosed cord compression. Imaging studies

Case	Age (y), Sex	Clinical findings	Imaging findings
1	22, M	Paraplegia	MRI: Cervical & dorsal epidural mass
2	15, F	Lower limb weakness	MRI: Presacral and paravertebral mass
3	27, M	Anemia, abnormal CXR	Chest CT: Dorsal canal stenosis
4	11, M	Lower limb numbness and paresthesia	MRI: Epidural mass
5	15, M	Lower limb paresthesia, disability in walking	MRI: Epidural mass in dorsolumbar area
6	17, F	Lumbago	MRI: Epidural mass in dorsolumbar area
7	23, M	Urinary incontinence, paresthesia of lower limb and perineum	MRI: Epidural mass in dorsolumbar and compression of conus medullaris
8	18, M	Low back pain	MRI: Epidural infiltration
9	14, M	Lower limb paresthesia and numbness	MRI: Mid-thoracic epidural mass

Table 1: Summary of clinical and imaging findings in 9 thalassemic patients with spinal involvement

are mandatory for establishing the diagnosis, treatment, and follow-up evaluation.

Prior to the advent of cross-sectional imaging, the diagnosis of intrathoracic EMH in patients with thalassemia was suspected from the typical osseous abnormalities seen on the patient's chest radiograph.^{14,15} Alternatively, it was confirmed after surgical removal of the mass.¹⁶ However, the plain radiograph shows only bony changes. The introduction of computed tomography (CT) scan helped in establishing the diagnosis, particularly when combined with myelography. In the early

1980's, several reports revealed CT as the diagnostic imaging method of choice.

Nowadays, MRI is considered the preferred imaging modality for the diagnosis and follow-up evaluation of patients with cord compression secondary to EMH.¹⁷⁻¹⁹ MRI has two main advantages over other radiologic modalities. First, unlike myelography, there is no need to use any contrast medium. Second, the extent of meningeal and epidural involvement can be well delineated, and MRI is ideal for determining the extent of intraspinal masses in EMH.^{15, 20}

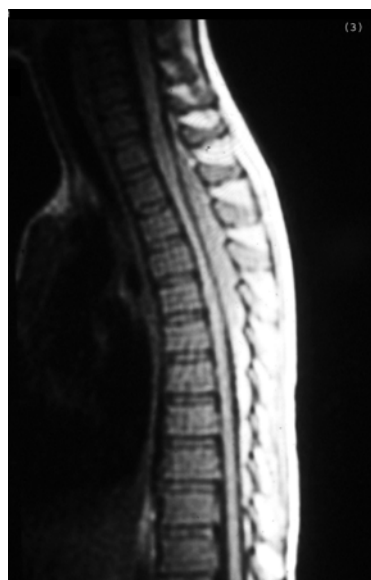


Figure 1: Sagittal T1-weighted MR image of the thoracic vertebrae showing an elongated epidural mass, compressing the thoracic spinal cord.

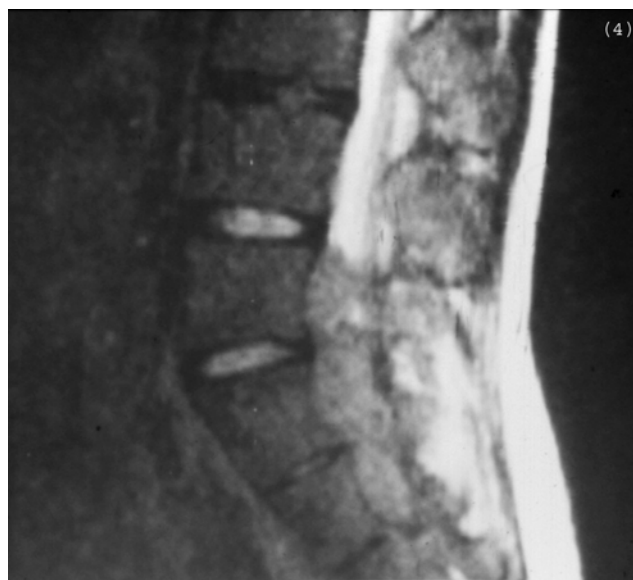

Figure 2: A) Mid-sagittal T2-weighted MR image of the sacral spine showing a presacral mass and an intraspinal epidural mass. B) Axial MR image of the lower thorax showing spinal canal stenosis due to epidural mass

The mainstay of an optimal therapeutic method for patient with cord compression due to EMH has remained controversial. A variety of therapeutic methods for such EMH tissue has been reported including surgical excision and decompression, radiotherapy, hypertransfusion, or a combination of two or more of these modalities.¹¹

Currently, surgical decompression is the method of choice for the management and diagnosis of the disease since histologic diagnosis can be established, and immediate decompression of the mass can be achieved. Nonetheless, surgery has several drawbacks including the risk of major bleeding due to the high vascularity of the mass in question, possibility of incomplete resection of the mass and the high incidence of recurrence after surgical resection. Furthermore, immediate total resection of EMH can lead to clinical decompensation and deterioration since these masses play a crucial role in maintaining an adequate hemoglobin level.²¹ To prevent this from occurring, incomplete resection of the mass can be attempted, to be followed by low-dose radiation, as reported by Shin *et al.*²² Studies have shown that EMH tissue is very sensitive to radiation, and will show a good response to radiotherapy. Moreover, recovery usually is complete after radiation therapy. The major disadvantage of radiation therapy is the lack of histologic diagnosis for documentation and the reduction in the bone marrow activity secondary to the procedure itself.^{19,23} Another approach for treating this complication is the use of hydroxyurea which plays an important myelosuppressive role and can be successfully used in the treatment of EMH in patients who are not transfusion-dependent.²⁴ Another non-surgical approach for diagnosis and treatment of EMH is to correct the anemia with recurrent blood transfusions. This therapeutic modality eliminates the risks of general anesthesia, surgery, and irradiation. Since EMH is only a compensatory mechanism for the chronic anemia existed in these patients, correction of the anemia by recurrent blood transfusions can decrease the need for activity of the EMH tissues and therefore, can result in relative inactivity of these tissues, leading to the shrinkage of the mass, decompression of the spinal cord, and improvement of neurologic symptoms.

Hypertransfusion therapy can be used both for diagnosis and treatment of the condition at the same time since only edema and cord compression secondary to EMH respond to this therapy.¹⁶

The diagnosis of EMH in our cases was solely based on clinical presentation and imaging modalities. Although biopsy remains the gold standard for establishing a tissue diagnosis, we believe that this invasive procedure should be reserved for older

patients and for those in whom the clinical picture is not as clear as in the cases reported herein. Furthermore, in our patients the masses regressed and completely disappeared after non-surgical treatment. This would not have occurred if the masses had been neoplastic in origin. Neurologic improvement was noted shortly after the beginning of the treatment and continued after therapy.

Extradural mass effect over the spinal cord was evident in 8 of 9 patients. In case 3, however, only a thoracic spinal canal stenosis could be detected. On MRI, the EMH mass is slightly more intense relative to the adjacent marrow in T1-weighted images, hyper-intense in T2-weighted images, and possesses enhancement after contrast injection.^{25,26}

In older patients, the differential diagnosis of an epidural mass on MRI includes lymphoma, myeloma, and metastatic malignant disease.

Conclusion

In the regions where thalassemia is prevalent, EMH may cause spinal cord compression and neurologic impairment. This condition, however, can be readily treated by blood transfusion and/or radiotherapy. MRI is an excellent imaging modality for the diagnosis of EMH. In any thalassemic patient with chronic anemia, neurologic symptoms, and signs of spinal cord compression, EMH should rank very high in the differential diagnosis. Therefore, in assessment of patients with signs and symptoms of spinal cord compression, one should pay attention to thalassemia intermedia and EMH, a condition that can be treated medically rather than surgically.

References

1. Habibzadeh F, Yadollahie M, Merat A, Haghshenas M. Thalassemia in Iran; an overview. *Arch Iran Med* 1998;**1**(1):27-33.
2. Habibzadeh F, Haghshenas M. [Thalassemia]. In: Azizi F, Hatami H, Janghorbani M, eds. *[Epidemiology and control of common diseases of Iran]*. 2nd ed. Tehran: Eshtiyagh Publishing Co, 2001:254-64. [in Persian]
3. Pearson HA, Cohen AR, Giardina PJ, Kazazian HH. The changing profile of homozygous beta-thalassemia: demography, ethnicity, and age distribution of current North American patients and changes in two decades. *Pediatrics* 1996;**97**(3):352-6.
4. Rey J, Gagliano R, Christides C, et al. [Spinal cord compression caused by extramedullary hematopoiesis foci in the course of thalassemia]. *Presse Med* 2001;**30**(27):1351-3. [Article in French]
5. Haghshenas M, Habibzadeh F, Vessal K. Extramedullary hematopoiesis in the thorax of a patient with β -thalassemia intermedia. *Arch Iran Med* 1998;**1**(1):45-6.
6. Abbassioun K, Aarabi B, Haghshenas M, et al. Spinal cord compression due to extradural extramedullary hematopoiesis in chronic anemias. *Iran J Med Sci* 1986;**13**(1):21-7.
7. Rasekhi AR, Omidvari Sh, Rasekhi AR. Cord compression secondary to epidural extramedullary hematopoiesis in beta-thalassemia. *Iran J Med Sci* 1998;**23**:138-41.

8. Jackson DV, Randall ME, Richards F. Spinal cord compression due to extramedullary hematopoiesis in thalassemia: long-term follow-up after radiotherapy. *Surg Neurol* 1988;**29**:389-92.
9. Amirjamshidi A, Abbassioun K, Ketabchi SE. Spinal extramedullary hematopoiesis in adolescents with thalassemia: report of two cases and a review of the literature. *Childs Nerv Syst* 1991;**7**:223-5.
10. Lau SR, Chan O, Chow Y. Cord compression due to extramedullary hematopoiesis in a patient with thalassemia. *Spine* 1994;**19**:2467-70.
11. Cardia E, Toscano S, La Rosa G, et al. Spinal cord compression in homozygous beta thalassemia intermedia. *Pediatr Neurosurg* 1994;**20**:186-9.
12. Issaragrisil S, Piankjjagum A, Wasi P: spinal cord compression in thalassemia: report of 12 cases and recommendations for treatment. *Arch Intern Med* 1981;**141**:1033-6.
13. Khandelwal N, Malik N, Khosla VK, et al. Spinal cord compression due to epidural extramedullary hematopoiesis in thalassemia. *Pediatr Radiol* 1992;**22**(1): 70-1.
14. Papavassiliou C. Tumor simulating intrathoracic extramedullary hematopoiesis. *AJR Am J Roentgenol* 1965;**93**:695-700.
15. Sorsdahl O, Taylor PE, Noyes WD. Extramedullary hematopoiesis, mediastinal masses and spinal cord compression. *JAMA* 1964;**189**:343-7.
16. Parsa K, Oreizy A. Nonsurgical approach to paraparesis due to extramedullary hematopoiesis. *J Neurosurg* 1995;**82**:657-60.
17. Singounas EG, Sakas DE, Hadley DM, et al. Paraplegia in a pregnant thalassemic woman due to extramedullary hematopoiesis: successful management with transfusions. *Surg Neurol* 1991;**36**:210-5.
18. Hassoun H, Lawn-Tsao L, Langevin ER, et al. Spinal cord compression secondary to extramedullary hematopoiesis: a non invasive management based on MRI. *Am J Hematol* 1991;**37**:201-3.
19. Qatanani M, Taher A, Koussa S, et al. Beta thalassemia intermedia in Lebanon. *Eur J Haematol* 2000;**64**:237-44.
20. Chaljub G, Guinto F, Crow W, et al. MRI diagnosis of spinal cord compression in beta thalassemia. *Spine* 1991;**16**:583-4.
21. Jackson DV, Randall ME, Richards F. Spinal cord compression due to extramedullary hematopoiesis in thalassemia: long-term follow-up after radiotherapy. *Surg Neurol* 1988;**29**:389-92.
22. Shin KH, Sharma S, Gregoritch SJ, et al. Combined radiotherapeutic and surgical management of a spinal cord compression by extramedullary hematopoiesis in a patient with hemoglobin E beta thalassemia. *Acta Haematol* 1994;**91**:154-7.
23. Singhal S, Sharma S, Dixit S, et al. The role of radiation therapy in the management of spinal cord compression due to extramedullary hematopoiesis in thalassemia. *J Neurol Neurosurg Psychiatry* 1992;**55**:310-2.
24. Cianculli P, Di Torritto TC, Sorrentino F, et al. Hydroxyurea therapy in paraparesis and cauda equina syndrome due to extramedullary haematopoiesis in thalassemia: improvement of clinical and haematological parameters. *Eur J Haematol* 2000;**64**:426-9.
25. Papavassiliou C, Gouliamos L, Vlahos S, et al. CT and MRI of symptomatic spinal involvement by extramedullary hematopoiesis. *Clinical Radiology* 1990;**42**:91-2.
26. Aloriani IA, Al-Asmi AR, Del-Carpio R. MRI features of epidural extramedullary hematopoiesis. *Eur J Radiol* 2000;**35**(1):8-11.