

M.S. Fazeli MD¹
A.R. Kazemeini MD²
A.H. Lebaschi MD³
H. Ghanaati MD⁴
A. Keshvari MD¹

1. Associate Professor, Department of General Surgery, Imam Khomeini Hospital, Tehran University of Medical Sciences, Tehran, Iran.
2. Assistant Professor, Department of General Surgery, Imam Khomeini Hospital, Tehran University of Medical Sciences, Tehran, Iran.
3. Department of General Surgery, Imam Khomeini Hospital, Tehran University of Medical Sciences, Tehran, Iran.
4. Associate Professor of Radiology, Advanced Diagnostic and Interventional Radiology Research Center (ADIR), Tehran University of Medical Sciences, Tehran, Iran.

Corresponding Author:
Mohammad Sadegh Fazeli
Address: Department of General Surgery, Imam Khomeini Hospital, Keshavarz Blvd., Tehran, Iran.
P.O.Box: 13145-158
Tel/Fax: +9821-6693-7185
Email: mhfazeli@sina.tums.ac.ir

Received December 30, 2009;
Accepted after revision March 2, 2010.

Iran J Radiol 2009;6(4):191-194

Evaluation of Hydrogen Peroxide-Enhanced Endoanal Ultrasound in Detecting the Internal Orifice and Type of Fistula-in-Ano

Background/Objective: Accurate delineation of the fistula tract anatomy is necessary for surgical management of anal fistulas. Among different ways to do this, endoanal ultrasound (EUS) is being increasingly used to evaluate patients with anal fistula. In this study we assessed the accuracy of hydrogen peroxide-enhanced EUS in detecting the internal orifice and the type of the fistula.

Patients and Methods: Patients with history and physical examination compatible with fistula-in-ano underwent an injection of 1 ml hydrogen peroxide into the external orifice and then EUS with a 7.5 MHz probe was carried out prior to surgery. The location of the internal orifice, presence of the abscess and the type of the fistula were examined and the results were compared with surgical findings.

Results: Thirty-two patients entered the study. The fistula type could be identified in 29 patients (90.6%). Twenty-two (75.8%) of these patients had trans-sphincteric and seven (24.2%) had inter-sphincteric fistulas. In 11 (34.3%) patients, an abscess was found using EUS. The fistula type was identified surgically in 29 patients, in which 26 were trans-sphincteric (89.8%), two were inter-sphincteric (6.8%), and one was extra-sphincteric (3.4%). There was a difference between detected sites of internal orifices during EUS and surgery (p value < 0.001). Hydrogen peroxide-enhanced EUS had an appropriate agreement in detecting trans-sphincteric fistulas with surgery.

Conclusion: Hydrogen peroxide-enhanced EUS is a suitable method for detecting the internal orifice of anal fistulas. It can be used for detecting trans-sphincteric fistulas, which are the most common type.

Keywords: Endoanal Ultrasound, Anal Fistula

Introduction

Anal fistulas represent the chronic phase of acute perianal abscesses. Treatment of fistulas typically involves surgical management, which may be associated with recurrence and postoperative incontinence.¹

In order to keep these complications down to a minimum, it is imperative to accurately delineate the anatomy of the fistula preoperatively. This will result in better surgical planning and possibly better fistula tract ablation and lesser degree of sphincter damage.^{2,3}

Apart from physical examination, which has been the main method of fistula delineation, imaging modalities, such as endoanal sonography and magnetic resonance imaging, have been used increasingly. Of these, endoanal ultrasound scanning has been most commonly used.¹⁻⁴ Use of hydrogen peroxide has been reported to enhance ultrasound imaging.^{5,6}

In this study, we report our experience with hydrogen peroxide-enhanced endoanal ultrasound (EUS) in more than 30 patients with fistula-in-ano and we will compare the results with those obtained by surgery.

Patients and Methods

Between April 2004 and February 2006, 32 consecutive patients with anal fistula who were referred to the colo-rectal laboratory of Imam Khomeini Hospital were considered for this prospective study. All patients had history and physical examination findings compatible with anal fistula. The exclusion criteria were refusal to undergo EUS, suspected malignancy, suspected inflammatory bowel disease, suspected special infections and inability to identify the external orifice.

Since EUS was advised as a routine diagnostic procedure—very much like other endoscopic procedures—implied consents were deemed sufficient and no written consents were obtained. Patients' data were recorded in a standard data form. For all patients, preoperative EUS with hydrogen peroxide as the contrast was performed routinely.

In the colo-rectal laboratory, patients were examined in the lithotomy position and the external orifice(s) was identified. Then one ml of 2% hydrogen peroxide was injected into the external orifice, and endoanal ultrasound scanning was performed using a 7.5 MHz probe. During EUS scanning, the type of the fistula, the number and the route of the tracts and their type, and the internal orifice(s) was recorded (Fig. 1). If more than one orifice was detected in any patient, the procedure was repeated for any additional orifices. After completion of the EUS examination, the surgery was scheduled. Surgeries were performed by two surgeons with sufficient experience in the domain of anorectal diseases and were not aware of the EUS exam results. These two surge-

ons performed every surgery together. Hydrogen peroxide 2% was injected by a probe into the external orifice(s) and the discovered tracts. Intra-operative findings concerning the number of external and internal orifices, the type of the fistula, and the number of tracts were noted in the corresponding part of the data form.

Multi-rater kappa statistics was computed for agreement between US and surgery. The difference between the two methods was investigated by McNemar test. P value < 0.05 was considered significant.

Results

Thirty two patients were enrolled in the study. The mean age was 39.39 years (range: 14 - 65). There were 27 (81.8%) men and 6 (18.2%) women. No complications were noted in patients undergoing EUS.

One patient had two external orifices, and no other patient had more than one external orifice. The most common locations for external orifices were at 2, 5, and 8 o'clock in the lithotomy position (15.2% for each location). The least common locations for external orifices were 9, 10, and 12 o'clock in the lithotomy position (3% for each location).

After injection of hydrogen peroxide, the internal orifice could not be clearly detected in nine (27.3%) patients. In the remaining 23 patients, the most common location for the internal orifice was 6 o'clock in the lithotomy position (seven patients, 30.4%). In 29 patients (90.6%) the fistula type could

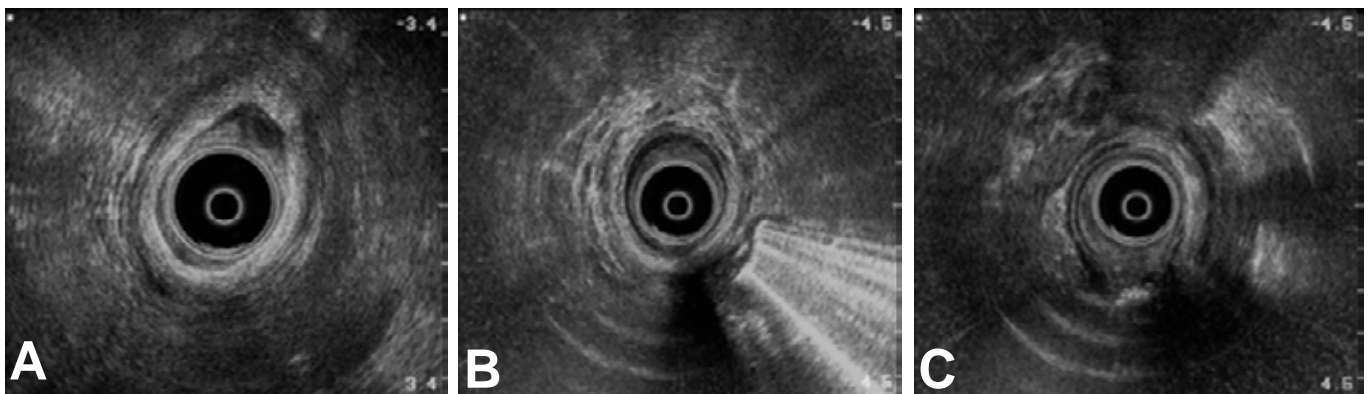


Fig. 1. EUS images in a 30-year-old man with complex anal fistula.

A. EUS image prior to H₂O₂ injection. The external orifice was at 1 o'clock. The internal orifice was not found.

B & C. EUS images of an inter-sphincteric fistula after injection of H₂O₂. The internal orifice could not be found, but the tract was identified.

Table 1. Cross-Tabulation of Detection of Abscess During EUS Examination and Surgery

		Detection of abscess during EUS ¹ examination		
		Yes	No	Total
Detection of abscess during surgery	Yes	6	1	7
	No	5	20	25
Total		11	21	32

1. EUS: Endoanal Ultrasound. P-value=0.001

Table 2. Cross-Tabulation of Fistula Types Identified During EUS Examination and Surgery.

		Fistula type detected during EUS ¹ examination		
		Trans-sphincteric	Inter-sphincteric	Total
Fistula type detected during surgery	Trans-sphincteric	19	7	26
	Inter-sphincteric	2	0	2
	Extra-sphincteric	1	0	1
Total		22	7	29

1. EUS: Endoanal Ultrasound. P-value=0.34

be identified: 22 trans-sphincteric (75.8%) and seven (24.2%) inter-sphincteric fistulas. No accessory tract could be detected in any patient. In 11 (34.3%) patients, an abscess was found during EUS examination.

During the course of surgery, in four (12.5%) of the patients, the disease was in fact a sinus and no internal orifice could be identified. These patients were among the nine patients in whom the internal orifice could not be detected during EUS scanning. In 16 (50%) patients, the internal orifice was located at 6 o'clock in the lithotomy position. The least common location was at 3 and 10 o'clock (one patient for each location). In seven (21.8%) patients, an abscess could be found. In 29 patients the fistula type could be identified: 26 trans-sphincteric (89.8%), two inter-sphincteric (6.8%), and one (3.4%) extra-sphincteric. In six patients an accessory tract could be found.

There was a significant difference between detected sites of internal orifices during EUS and surgery (p value < 0.001). During EUS examination, it was possible to detect 85.7% of the abscesses, and 20% of the reported abscesses during EUS were proven to be wrong during surgery (Table 1). Table 2 shows the cross-tabulation of fistula type findings during EUS examination and surgery. The McNemar test did not reveal a significant difference (p value=0.22). This table shows that EUS was most effective at detecting trans-sphincteric fistulas and it was possible to recognize 19 (73%) of 26 trans-sphincteric fistulas during EUS examination. On the other hand, only three

(13.6%) of 22 trans-sphincteric fistulas reported during EUS examination were proven wrong.

Multi-rater kappa statistics was computed to show the agreements between the two methods. About the diagnosis of the type of abscess, kappa (SE) was 0.62 (0.14), proposing a substantial agreement between the two methods. For detection of the tracts, kappa (SE) was 0.82 (0.01), showing an almost perfect agreement.

Discussion

In this report, 32 patients were studied. An advantage of this study was that all patients underwent surgery following hydrogen peroxide-enhanced EUS examination, which makes appropriate evaluation of EUS findings possible. The main positive finding of this study concerns high correlation between EUS and surgery in detecting the location of the internal orifice of the fistula, which was found to be more than 95%. In this way, EUS may be regarded as a minimally invasive modality to detect the internal orifice preoperatively. It may also be possible to describe its relation to the levator ani muscle and thereby plan a more effective surgery. If no internal orifice is detected during EUS examination, a supra-levator or extra-sphincteric fistula should be suspected. EUS was also a reasonably useful method for detecting perianal abscesses.

Several other studies have reported the sensitivity

and the specificity of EUS in the detection of the internal orifice. In 1999, Cho operated on 139 patients with anal fistula after preoperative EUS. The reported sensitivity and specificity of EUS in the detection of internal orifice were reported to be 94% and 87%, respectively.⁷ In still another study, 57 patients with anal fistula underwent surgery subsequent to hydrogen peroxide-enhanced EUS. The authors reported a 61.1% correlation between EUS and surgery in detecting an internal orifice.⁸ In 2005, Pascual and his colleagues evaluated hydrogen peroxide-enhanced EUS and reported a 95.8% correlation between EUS and surgery in detecting internal orifice.⁹

We could not find a significant difference between EUS and surgery in the way of identifying the type of the fistula tract. It can be stated that although EUS may not have a high overall accuracy in identifying the type of the fistula, it does detect trans-sphincteric fistulas with reasonable results, and since trans-sphincteric fistulas were the most common in our patients, this may indicate clinical applicability of EUS in this regard. Ortiz and colleagues in 2002 reported an accuracy of 77% for non-enhanced EUS in detecting trans-sphincteric fistulas. They mentioned that EUS has a low accuracy in identifying intra-sphincteric and extra-sphincteric fistulas with the accuracies being 32% and 17%, respectively.¹⁰ In another report, 86 patients with anal fistula underwent EUS and then surgery was subsequently performed. The authors compared EUS and surgery findings and consequently reported that EUS had been able to identify the type of fistula correctly in 86.5% of the patients. In the same report the correlation between EUS and surgery in detecting the internal orifice of the fistula was 81.1%.¹¹

In spite of the operator-dependent nature of EUS, and ultrasound in general, EUS seems to be an appropriate method for detecting the internal orifice of the

anal fistula, and hydrogen-peroxide as a contrast can increase this appropriateness. EUS is probably not as accurate in detecting the type of fistula, being able to identify trans-sphincteric fistulas better than the other types.

We have planned to achieve a larger study with a greater number of patients in order to enhance the power of our study. Till then, we think these results are adequate to make the EUS study a good diagnostic procedure before performing anal fistula surgery, especially for complex cases.

References

1. Ratto C, Gentile E, Merico M, Spinazzola C, Mangini G, Sofo L et al. How can the assessment of fistula-in-ano be improved? *Dis Colon Rectum* 2000;43:1375-82.
2. Kruskal JB, Kane RA, Morrin MM. Peroxide-enhanced anal endosonography: technique, image interpretation, and clinical applications. *Radiographics* 2001;21:S173-89.
3. Morris J, Spencer JA, Ambrose NS. MR imaging classification of perianal fistulas and its implications for patient management. *Radiographics* 2000;20:623-35.
4. Williams JG. Anal ultrasonography in the diagnosis and management of abscess and fistula disease of the anorectum. *Semin Colon rectal Surg* 1995;6:105-13.
5. Poen AC, Felt-Bersma RJ, Eijssbouts QA, Cuesta MA, Meuwissen SG. Hydrogen peroxide-enhanced transanal ultrasound in the assessment of fistula-in-ano. *Dis Colon Rectum* 1998;41:1147-52.
6. Cheong DM, Noguera JJ, Wexner SD, Jagelman DG. Anal endosonography for recurrent anal fistulas: image enhancement with hydrogen peroxide. *Dis Colon Rectum* 1993;36:1158-60.
7. Cho DY. Endosonographic criteria for an internal opening of fistula-in-ano. *Dis Colon Rectum* 1999;42(4):515-8.
8. Moscovitz I, Baig MK, Noguera JJ, Ovalioglu E, Weiss EG, Singh JJ et al. Accuracy of hydrogen peroxide enhanced endoanal ultrasonography in assessment of the internal opening of anal fistula complex. *Tech Coloproctol* 2003;7(3) 133-7.
9. Pascual Miguelanez I, García-Olmo D, Martínez-Puente MC, Pascual Montero JA. Is routine ultrasound useful in anal fistula? *Rev Esp Enferm Dig* 2005;97:323-7.
10. Ortiz H, Marzo J, Jiménez G, DeMiguel M. Accuracy of hydrogen peroxide-enhanced ultrasound in the identification of internal openings of anal fistulas. *Colorectal Dis* 2002;4(4):280-3.
11. Sudol-Szopinska I, Geśła J, Jakubowski W, Noszczyk W, Szczepkowski M, Sarti D. Reliability of endosonography in evaluation of anal fistulae and abscesses. *Acta Radiol* 2002;43(6):599-602.