

a robust and useful algorithm for automatic fetal biometry evaluation that could be extended to nuchal translucency (NT) measurement based on the providing dataset.

• 10.5812/IRANJRADIOL. 99141

A Deep Learning-Based Approach for Breast BI-RADS Prediction on Shear Wave Elastography Images

AliShabanzadeh^{1*}; ShakibaMoradi²; Parvaneh(Masoumeh) Gity³; Mostafa Ghelich Oghli¹

¹Intelligent Imaging Technology Research Center, Med Fanavarn Plus Co., Karaj, Iran

²Sharif University of Technology, Tehran, Iran

³Tehran University of Medical Sciences, Tehran, Iran

*Corresponding author: Intelligent Imaging Technology Research Center, Med Fanavarn Plus Co., Karaj, Iran. Email: shabanzadeh.ali@gmail.com

Abstract

Background: Breast cancer is the most common type of cancer among women. About one of every eight women is diagnosed with breast cancer during her lifetime. Malignant tissue is stiffer than normal and benign tissues. This stiffness could be evaluated by elastography. The American College of Radiology (ACR) has published a quality assurance tool named Breast Imaging-Reporting and Data System (BI-RADS) to standardize breast cancer reporting. Although it was originally designed to use with mammography, it now contains several features for various imaging modalities. Among technologies, shear wave elastography (SWE) has shown promising results in breast lesion classification.

Objectives: In this paper, we present the capability of the convolutional neural network in the prediction of B-RADS using SWE images.

Methods: A comprehensive dataset of SWE images of breast tissue was provided using Esaote MyLab™ 9 and Aupersonic Aixplorer systems. Two hundred images related to breasts with different BI-RADS stages were gathered from the Cancer Institute, Imam Khomeini Medical Center (UICC). The data augmentation with a factor of 10 was applied to the prepared dataset. Some patients had multiple lesions and for each lesion, one or two images were acquired and stored in DICOM standards. The gold standard for the evaluation of the proposed algorithm was a biopsy, which was performed on all the examined lesions. A novel convolutional neural net-

work was applied to the dataset to extract the visual features of images. The architecture was based on Densenet architecture, which was modified for our purpose. We used the network in both pre-training and end-to-end training strategies and the results were compared. The network was pre-trained on the Imagenet dataset due to the lack of a sufficient dataset. On the other hand, with data augmentation, the network underwent a full training strategy. Finally, the classification layer was a softmax layer, which was used to decide on the benignity or malignancy of the lump. The training and testing procedures for tumor classification were employed with five-fold cross-validation. The entire dataset was randomly divided into five equal-sized subsets on the premise that multiple images acquired from the same patient were assigned to the same subset. Four subsets together were used for training and the remaining one for testing and this process was repeated five times such that each subset was used once as the test set.

Results: The processing hardware had a 12 GB RAM, a GPU-based graphics card with 2496 CUDA cores (Tesla K80), and an Intel Xeon CPU. The network implementation was done in the Python environment with Tensorflow r1.12 and Keras 2.2.4. The results of the proposed methods were satisfying in both pre-training and end-to-end training approaches. We used various evaluation metrics including precision, recall, F1-score, ROC curve, and training time for both strategies. The precision, recall, and F1-score were 0.93, 0.95, and 0.94 for the Densenet architecture trained from scratch and 0.97, 0.94, and 0.95 for the transfer learning approach (see Table 1).

Table 1. Performance of the Proposed Methods for SWE Image Classification

Model	Performance			
	Precision (%)	Recall (%)	F1 (%)	AUC
Transfer learning	0.97 ± 0.013	0.94 ± 0.012	0.95 ± 0.01	0.986
Training from scratch	0.93 ± 0.024	0.95 ± 0.01	0.94 ± 0.019	0.941

The ROC curve was plotted for both approaches and the area under the curves (AUCs) were calculated. The transfer learning approach yielded an AUC of 0.98, whereas this parameter was 0.94 for the fully-trained approach (see Figure 1). Finally, the training time of transfer learning approach was one-fifth the time of training from scratch, as it was anticipated.

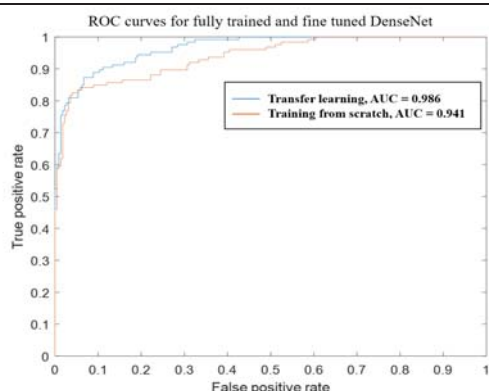


Figure 1. ROC curves for fully trained and fine tuned DenseNet

Conclusion: The results showed the superiority of the transfer learning approach in tumor classification. Higher statistical metrics with lower training time makes this approach more compatible with SWE images.

• 10.5812/IRANJRADIOL.99148

Segmentation of Diabetic Retinopathy Lesions in Retinal Fundus Images Using Multi-View Convolutional Neural Networks

Hassan Khastavaneh^{1, *}; Hossein Ebrahimpour-Komleh¹

¹Department of Computer and Electrical Engineering, University of Kashan, Kashan, Iran

*Corresponding author: Department of Computer and Electrical Engineering, University of Kashan, Kashan, Iran. Email: khastavaneh@hotmail.com

Abstract

Background:Diabetic retinopathy is one of the leading causes of blindness worldwide. Furthermore, it is considered the most important complication of diabetes mellitus, which creates various lesions in the retina at its different stages. Moreover, these lesions appear in different forms of hemorrhages, exudates, and microaneurysms. The count and type of these lesions can determine the severity and progression of the disease. Early detection of these lesions can lead to better treatment and blindness prevention. The accurate segmentation of these lesions is required to detect them and specify their counts and types. Since the manual segmentation of retinal lesions is tedious and time-consuming, automated segmentation is preferred. Furthermore, in screening programs where a large population needs to be considered, automated segmentation is inevitable. Therefore, automatic segmentation of retinal lesions is the first stage of any typical computer-aided diagnosis system for early diagnosis

of the disease. Automated segmentation of retinal lesions is a challenging task due to the shape diversity and inhomogeneity existing in these lesions. Hence, more advanced segmentation techniques capable of modeling lesion complexities are required to tackle difficulties regarding the automated segmentation of diabetic retinopathy lesions in retinal fundus images.

Objectives: In this study, we proposed an automated pixel-based method for the segmentation of different types of lesions on the retinal fundus images.

Methods: This method utilized convolutional neural network with a particular architecture to describe and label the pixels of fundus images as either normal or lesion. The proposed method had four phases of pre-processing, view generation, segmentation, and post-processing. The pre-processing stage attempted to enhance input images for better segmentation. In the view generation phase, multiple views that described a pixel from different perspectives were extracted for all pixels on images. The segmentation phase, which indeed was a convolutional neural network capable of handling multi-view data, received multiple views corresponding to each pixel area and decided if it belonged to a normal or a lesion area. The segmentation network with its unique architecture could handle diversities and complexities existing in the retinal lesions, leading to accurate segmentation. Finally, the post-processing phase refined the segmentation results by reducing false positives. In addition to segmentation, the proposed method detected lesion types in the segmentation process.

Results: The proposed method was implemented and its performance was evaluated using standard performance measures including accuracy, sensitivity, specificity, dice similarity coefficient, and Jaccard coefficient. The segmentation network was trained with 54 images and tested with 27 images. The experimental results were very promising and comparable to the state-of-the-art methods of fundus lesion segmentation.

Conclusion: A method based on convolutional neural networks for the segmentation of retinal lesions on fundus images was proposed. Alongside the promising experimental results, the method could jointly produce different lesion masks for different lesion types as a significant functionality.

• 10.5812/IRANJRADIOL.99144

Abnormality Detection in Musculoskeletal Radiographs by DenseNet and Inception-v3

Zahra Rezaei^{1, *}; Behnaz Eslami²; Hossein Ebrahimpour Komleh¹; Kaveh Daneshmand Jahromi³