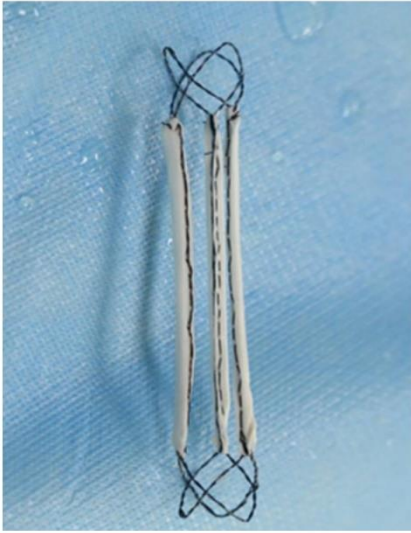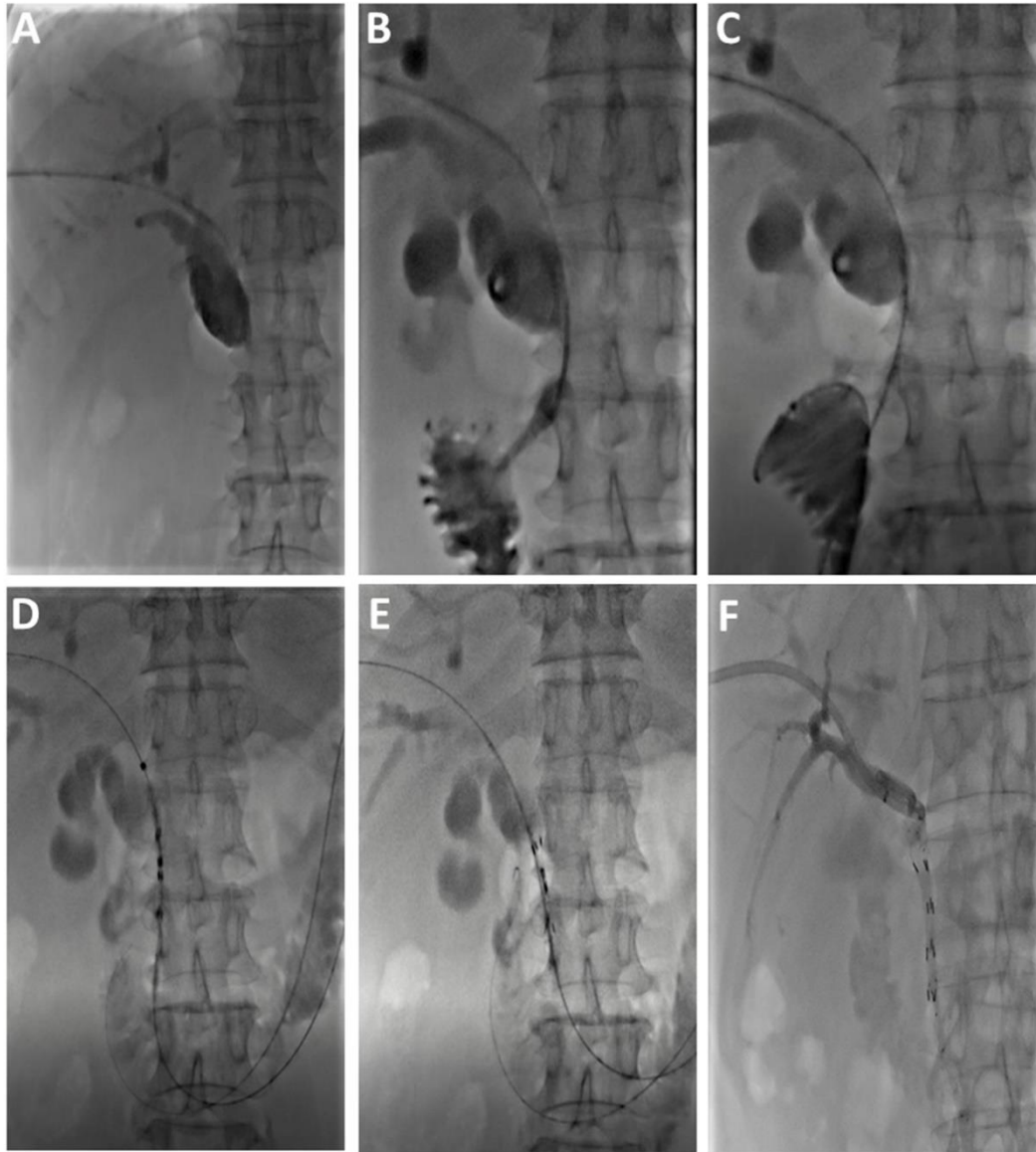


Appendix 1. The photograph of the ^{125}I particles stent



Appendix 2. The procedure of ¹²⁵I particles stent implantation. A, cholangiography before the guide wire passes through the segment of biliary stenosis; B, cholangiography after the guide wire passes through the segment of biliary stenosis; C, implantation of hard and long guide wire; D, implantation of ¹²⁵I particles stent; E, implantation of normal stent on the inner side of ¹²⁵I particles stent; F, implantation of external drainage tube, and the contrast agent smoothly passes through the original obstructed segment.