

F. Ezoddini Ardakani DDS, MS¹
M. Zangouie Booshehri DDS, MS²
A. Navab Azam DDS, MS³
F. Fotoohi Ardakani DDS⁴

1. Associate Professor, Department of Oral and Maxillofacial Radiology, School of Dentistry, Shahid Sadoughi University of Medical Sciences, Yazd, Iran.
2. Assistant Professor, Department of Oral and Maxillofacial Surgery, School of Dentistry, Shahid Sadoughi University of Medical Sciences, Yazd, Iran.
3. Department of Oral and Maxillofacial Radiology, School of Dentistry, Shahid Sadoughi University of Medical Sciences, Yazd, Iran.
4. School of Dentistry, Shahid Sadoughi University of Medical Sciences, Yazd, Iran.

Corresponding Author:
Fatemeh Ezoddini-Ardakani
Address: Department of Oral and Maxillofacial Radiology, School of Dentistry, Daheye Fajr Blvd., Imam Ave, Yazd, Iran.
Tel: +98351 625 5881
Fax: +98351 625 0344
E-mail: ezoddini@gmail.com

Received January 16, 2010;
Accepted after revision July 17, 2010.

Iran J Radiol 2010;7(2):91-96

Diagnostic Accuracy of Panoramic Radiography in Determining the Position of Impacted Third Molars in Relation to the Inferior Dental Canal Compared with Surgery

Background/Objective: Extraction of the third lower molar tooth is one of the common surgical procedures that may lead to the damage of the infra-alveolar nerve. This damage could be related to deep impacted third molar teeth and roots close to the mandibular canal. Therefore, the radiography evaluation of the position of this tooth in relation to the inferior dental canal is important before surgery.

Patients and Methods: In this cross-sectional descriptive study, 59 patients who were referred to maxillofacial surgeons for third molar tooth surgery, and had a panoramic radiography were enrolled into the study. The positions of the impacted teeth in the panoramic radiography were determined according to their relation to the mandibular canal and were reported as five different subgroups (A, B, C, D and E). Cases which were not classified in any of these subgroups were considered as F. The surgeon also determined the position of the impacted teeth after surgery based on the mentioned classification. To assess the correlation of the data, Kappa analysis was used.

Results: Kappa statistics for agreement between radiography and surgery was 0.85 ($p < 0.001$).

Conclusion: According to this study, radiological assessment before third molar tooth surgery can reduce the risk of conceivable damage to the canal and nerve. It is recommended to consider the radiologists opinion before surgery.

Keywords: Panoramic Radiography, Third Molar, Tooth Extraction, Mandibular Nerve

Introduction

Extraction of impacted third molars is one of the most common surgeries in dentistry that may injure the infra-dental canal (IDC) and may cause related complications.¹

Calcification of the bony canal occurs before the root formation of the third molars; therefore, it is possible that the roots get bent on contact with the canal. Sometimes the end of the roots can penetrate the roof of the canal and cause local depression.²

According to Jerjes et al.,³ seven factors are important in evaluating the surgical difficulty of impacted third molars by radiography, "including spatial relationship, depth of impaction, ramus relationship/space available, type of impaction, number and form of roots, form of the apex of the root and relation of the root to the mandibular canal". More factors may be uncovered by collaboration between surgeons and radiologists to help make a more accurate prediction of temporary and permanent paresthesia.

Normally in radiographs, the impacted third molars have roots that are

superimposed on the mandibular canal, even though the canal is usually situated in the buccal region of the teeth.⁴

The anatomy within the inferior alveolar neurovascular bundle is important in surgeries such as dentoalveolar surgery, implant-related surgery and surgery for trauma or pathology, which may involve the inferior alveolar canal.⁵

The aim of this study was comparing the accuracy of panoramic radiography with surgery in determining the position of the third molar teeth and inferior dental canal.

Patients and Methods

A total of 59 panoramic radiographs were obtained of 16 men and 43 women (mean age, 26.5 years; range, 15-63 years) referred to the Dental Faculty for surgical extraction of the third lower molars. All radiographs were taken by one operator at one radiological center. The exclusion criteria was existence of diseases which contra-indicate tooth surgery. The participants were recruited sequentially.

The machine used was Planmeca 2002 EC Proline (Planmeca Company, Helsinki, Finland) with 18 S, 12mA and 80kvp. The film used was made by Kodak, France and measured 15-30 cm. The machine used for developing the films was Extra Velopex made in London (England), and the chemicals used for developing were kept at 27 degrees Celsius for a period of 4 minutes. The relation between the teeth roots and the infra-dental canal was evaluated by using a loop and was classified into groups A to F based on Monaco et al. and Langlias et al. suggestions^{6,7} (Fig. 1).

The classification of groups A, B, C, D and E were as follows:

A: The roots of the third molar cut off the radiolucency of the canal, and the apex of the roots are visible under the canal.

B: The roots of the third molar are in the radiolucency of the canal and have not cut off the lower cortical layer of the mandibular canal.

C: The roots of the third molar are adjacent to the canal, and the superior border of the canal is visible.

D: Usually due to bending of one of the two roots of the third molar, bending of the mandibular canal is also seen.

E: In addition to bending of the canal, diversion of the canal is also visible.

Group F comprised of cases which were unknown and were not in any other group and the surgeon had no explanation for the different root bendings and the abnormal relationship of the teeth with the infra-dental canal. The radiographs were evaluated by the radiologist and classified accordingly. In the next step, all of the surgeries were performed by one oral and maxillofacial surgeon. The surgeon was blinded to the radiological findings of the patients. Ultimately, the relationship between the surgical and radiological findings was analyzed.

To yield better predicting values of radiologic findings, groups A and B were classified as interrupted and groups C, D and E as diverted. The calculations were also done according to these two groups, and Kappa test was used for this purpose. The difference of agreements between gender and the two age groups were compared using Fisher's exact test. Based on the radiologist's opinion, there was one case in group F; whereas, according to the surgeon, there were four cases. Therefore, these cases were not included in the statistical analysis.

Results

In the present study, 59 cases were studied of which 16 were men and 43 were women. Their age range was 15-63 years with a mean age of 26.5 years. Participant recruitment was started in July 2008 and ended in July 2009. None of the participants encountered adverse effects during the study. The distribution of their demographic characteristics is shown in Table 1. The various radiographic diagnoses by the radiologist and by the surgeon are shown in Tables 2 and 3.

Sensitivity of radiology in diagnosing position A and

Table 1. The Distribution of Demographic Characteristics of the Population Under Study (n=59)

Variable		Number	Percentage
Gender	Male	16	27.1
	Female	43	72.9
Age	≤ 25	24	40.6
	> 25	35	59.4
Position of the Tooth (side)	Right	31	52.5
	Left	28	47.5

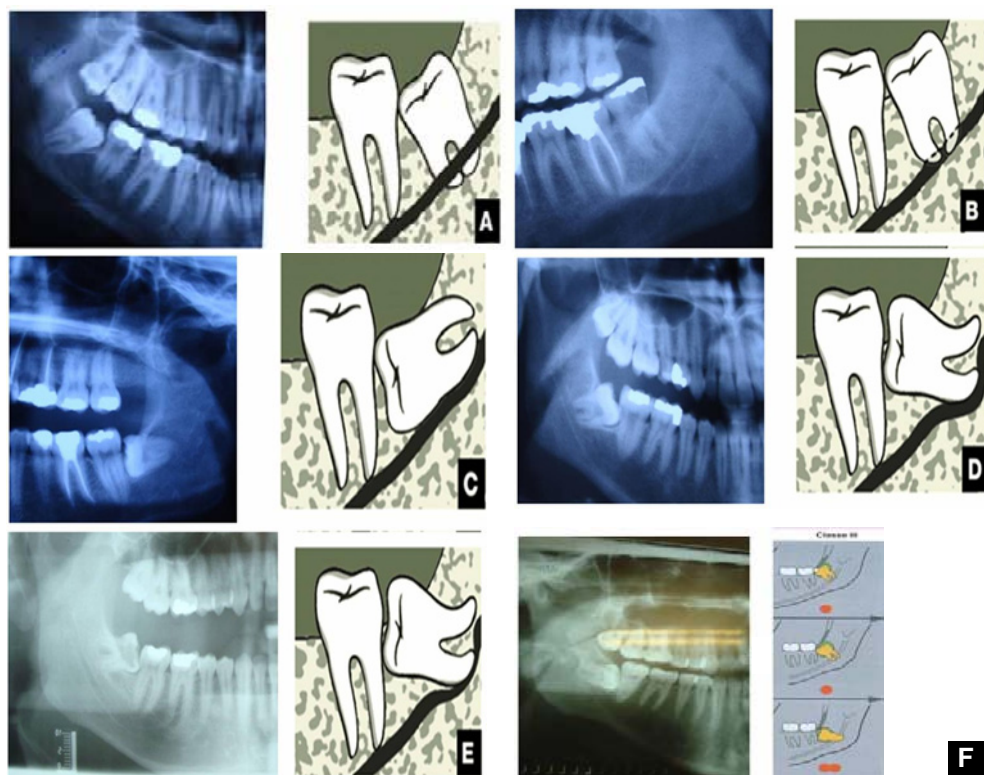


Fig. 1. The classification of the relationship between the third molar tooth roots and the infra-dental canal into groups A to F. Group F is comprised of cases which were unknown and did not fall in any of the other groups (the schematic figures are from ref 11).

B from C, D and E compared with the surgeon's diagnosis is calculated as 91.2%, while the specificity is 95.2%. The agreement of these two approaches is calculated as 92.7% (CI 95%: 85.9%-99.5%).

In this study, agreement between the radiologist and surgeon was determined. On the whole, without considering the various age and sex groups, this agreement was considerable (p value < 0.001) (Table 4).

Kappa was also calculated according to the gender of the patients, and the results showed that the agreement between the surgeon and the radiologist was similar in both male and female subjects (Fisher's exact test, p value > 0.99) (Table 5). Kappa was almost perfect in both genders (0.87 and 0.83) (p value < 0.001 for both).

The comparison of percentage agreement in the two age groups shows that the agreement was similar in the age groups (Fisher's exact test p value > 0.99) (Table 6). In both age groups Kappa was almost perfect (0.86 and 0.82, p value < 0.001 in both groups).

Discussion

Removal of the impacted third lower molars and their proximities is one of the common maxillofacial surgeries. In this procedure, the infra-dental canal

requires accurate and precise investigation before surgery. The aim of the present study was to evaluate the role of panoramic radiography prior to surgery of the third lower molar and to determine the relationship between the surgical findings of the surgeon and the radiological findings of the radiologist.

Bell et al.⁸ studied the accuracy of panoramic radiography of the teeth in determining the morphology of third mandibular molar roots before surgery. Results showed that the sensitivity and specificity of the radiographs regarding roots were 29% ($\pm 10\%$) and 94%, respectively. Sensitivity and specificity of the radiographs in determining the primary relationship between roots and mandibular canal were 66% and 74%, respectively.

In the study by Sedaghatfar and colleagues,⁹ the specificity and sensitivity of panoramic radiological findings before extraction of the third lower molars were evaluated. From the radiologist point of view, four radiological parameters, including darkening and narrowing of dental roots, interception of the canal and deviation of the canal were examined. The results showed that the four parameters had a significant relationship with mandibular canal injury ($p \leq 0.05$), and it was concluded that radiological evaluation before surgery plays a key role in decreasing the risk of injury to the mandibular canal.⁹

The present study was similar to the above-mentioned study as five radiological parameters and a panoramic radiography before injury were examined and the agreement between the radiologist and surgeon was about 85%.

Nakagawa and co workers¹⁰ studied the reliability of panoramic radiography before surgery in 73 patients who were mostly women. It was concluded that panoramic radiography is capable of predicting the relationship between the third molar and the mandibular canal. The radiological parameters were presence or absence of white lines of the canal wall and connection or separation between the teeth roots and the canal.¹⁰

In the present study, it was concluded that panoramic radiography is effective in predicting the position of the teeth and the number of cases were 59 of which 72.9% were women.

The study by Smith et al.¹¹ is similar to the above study with regards to radiological evaluation before surgery of the third molar teeth. Sant Ana and co-

workers¹² did not consider panoramic radiography as a basic diagnostic tool for planning third molar surgery, though they did not reject the primary role of panoramic radiography before such surgeries. In the present study also, in some cases, radiographs of the third molars did not help the surgeon in diagnosis, and therefore, panoramic radiography is not always helpful.

Koong et al.¹³ studied the different methods for determining the relationship between the mandibular canal and third molars. In that study, nine radiographic landmarks were evaluated by the surgeons in the absence of the radiologist. Approximately, 25% of the surgeons considered panoramic radiography adequate for surgery, whereas 61% of the surgeons considered CT scan as the ideal radiography in this field. There was a difference in opinion between different surgeons regarding the nine landmarks such as narrowing of the canal or change in the direction of the canal.¹³

The different conclusion of the above-mentioned study compared to the present study could be due to the presence of the large number of surgeons in that study and their different opinions, while only one surgeon participated in the present study.

Blaeser et al.¹⁴ evaluated the relationship between specific signs of panoramic radiography and infra alveolar nerve injuries during extraction of the third molar teeth. Positive radiographic signs were related with infra-alveolar nerve injuries ($p < 0.0001$). Presence of radiographic signs was with a positive prediction range of 1.4%-2.7% and a 40% increase in injuries to the infra-alveolar nerve. Szalma et al.¹⁵ reported that for predicting inferior alveolar nerve paresthesia after this procedure panoramic radiography is not an adequate screening method. Furthermore, Jerjes et al.³ showed that panoramic radiography is quite effective in predicting the occurrence of temporary or permanent paresthesia.

Gomes and colleagues¹⁶ studied the sensitivity and specificity of panoramic radiography in predicting infra-alveolar nerve injury during third molar teeth extraction. Surgical complications were present in 3.5% of the cases, and according to the study, panoramic radiography did not have a good predictive value for infra-alveolar nerve injuries after third molar teeth surgery. In the present study, the similarity

Table 2. The Distribution of Various Radiographic Diagnoses by the Radiologist and the Surgeon (n=59)

Diagnosis	Radiologist		Surgeon	
	Number	Percentage	Number	Percentage
A	17	28.8	26	44.06
B	16	27.1	8	13.55
C	16	27.1	8	13.55
D	6	10.1	10	16.9
E	3	5.1	3	5.08
F	1	1.7	4	6.77

Table 3. The Distribution of Various Combined Radiographic Diagnoses by the Radiologist and the Surgeon

Diagnosis	Radiologist		Surgeon	
	Number	Percentage	Number	Percentage
Cut off (A,B)	33	56.89	34	61.8
Diverted (C,D,E)	25	43.11	21	38.2
Total	58	100	55	100

Table 4. Agreement Between Radiologist and Surgeon

Radiologist	Surgeon		
	Cut off No. (%)	Diverted No. (%)	Total No. (%)
Cut off	31 (56.3)	1 (1.8)	32 (58.1)
Diverted	3 (5.5)	20 (36.4)	23 (41.9)
Total	34 (61.8)	21 (38.2)	55 (100)

Kappa=0.85; SE=0.073; p value<0.001

Table 5. Agreement Between the Radiologist and Surgeon According to Gender

	Radiologist	Surgeon		
		Cut off No. (%)	Diverted No. (%)	Total No. (%)
Male	Cut off	6 (37.5)	1 (6.3)	7 (43.8)
	Diverted	0 (0)	9 (56.2)	9 (56.2)
	Total	6 (37.5)	10 (62.5)	16 (100)
Kappa=0.87, SE=0.124, p value< .001,				
Female	Cut off	25 (64.1)	0 (0)	25 (64.1)
	Diverted	3 (7.7)	11 (28.2)	14 (35.9)
	Total	28 (71.8)	11 (28.2)	39 (100)
Kappa=0.83, SE=0.096, p value<0.001				

Fisher exact test: p value ~ 1

Table 6. Agreement Between the Radiologist and Surgeon According to Age Groups

	Radiologist	Surgeon		
		Cut off No. (%)	Diverted No. (%)	Total No. (%)
Age ≤25	Cut off	21 (63.6)	0 (0)	21 (63.6)
	Diverted	2 (6.1)	10 (30.3)	12 (36.4)
	Total	23 (69.7)	10 (30.3)	33 (100)
Kappa=0.86, SE=0.092, p value<0.001				
Age >25	Cut off	10 (45.5)	1 (4.5)	11 (50)
	Diverted	1 (4.5)	10 (45.5)	11 (50)
	Total	11 (50)	11 (50)	22 (100)
Kappa=0.82, SE=0.123, p value<0.001				

or level of agreement between the radiologist and the surgeon was higher in the patients older than 25 as compared to the patients bellow 25 years old. The reason could be the increased bone density in older age groups that can cause difficulty in accurate diagnosis.

Furthermore, some cases were observed during surgery that did not fit in any of the five groups. According to the Langland study,⁷ they could be classified as class III (F) group. They included cases like different bending of each of the roots or bending of the tooth around the mandibular canal which are not predictable on panoramic radiography. The prevalence of these variants is related to the different anatomical structures of the third molars and genetic factors. In populations with a high rate of F group, there is a notable decrease in reliability of panoramic radiography. So regarding to the low frequency of F group in panoramic radiography, this group was omitted in statistical analysis and the results are based on groups A-E.

In conclusion, panoramic radiography is a common extra-oral imaging technique that is used by most of the oral maxillofacial surgeons for visualization of impacted third molars and their relationship with the

infra-dental mandibular canal. Panoramic radiography and the radiologist's opinion before surgery can be helpful in preventing unwanted complications of third lower molar teeth surgery.

References

1. Tetsch P, Wagner W. Operative extraction of wisdom teeth. 6th ed. London: Wolf Medical Publications Ltd; 1990.
2. Kilic C, Kamburoglu K, Ozen T, Balcioglu HA, Kurt B, Kutoglu T et al. The position of the mandibular canal and histologic feature of the inferior alveolar nerve. *Clin Anat* 2010;23(1):34-42.
3. Jerjes W, El-Maaytah M, Swinson B, Upile T, Thompson G, Gittelmon S et al. Inferior alveolar nerve injury and surgical difficulty prediction in third molar surgery: the role of dental panoramic tomography. *J Clin Dent* 2006;17(5):122-30.
4. James RH, Edward E, Myron RT. Contemporary oral and maxillofacial surgery. 5th ed. Elsevier Health Sciences; 2008.
5. Pogrel MA, Dorfman D, Fallah H. The anatomic structure of the inferior alveolar neurovascular bundle in the third molar region. *J Oral Maxillofac Surg* 2009;67(11):2452-4.
6. Monaco G, Montevicchi M, Bonetti GA, Gatto MR, Checchi L. Reliability of panoramic radiography in evaluating the topographic relationship between the mandibular canal and impacted third molars. *J Am Dent Assoc* 2004;135(3):312-8.
7. Langlais RP, Langland OE, Nortje CJ. Diagnostic imaging of the jaws. Baltimore: Williams & Wilkins; 1995.
8. Bell GW, Rodgers JM, Grime RJ, Edwards KL, Hahn MR, Dorman ML et al. The accuracy of dental panoramic tomographs in determining the root morphology of mandibular third molar teeth before surgery. *Oral Surg Oral Med Oral Pathol Oral Radiol Endod* 2003;95(1):119-25.

9. Sedaghatfar M, August MA, Dodson TB. Panoramic radiographic findings as predictors of inferior alveolar nerve exposure following third molar extraction. *J Oral Maxillofac Surg* 2005;63(1):3-7.
10. Nakagawa Y, Ishii H, Nomura Y, Watanabe NY, Hoshiba D, Kobayashi K et al. Third molar position: reliability of panoramic radiography. *J Oral Maxillofac Surg* 2007;65(7):1303-8.
11. Smith AC, Barry SE, Chiong AY, Hadzakis D, Kha SL, Mok SC et al. Inferior alveolar nerve damage following removal of mandibular third molar teeth. A prospective study using panoramic radiography. *Aust Dent J* 1997;42(3):149-52.
12. Sant'Ana LF, Giglio FP, Ferreira O Jr, Sant'ana E, Capelozza AL. Clinical evaluation of the effects of radiographic distortion on the position and classification of mandibular third molars. *Dentomaxillofac Radiol* 2005;34(2):96-101.
13. Koong B, Pharoah MJ, Bulsara M, Tennant M. Methods of determining the relationship of the mandibular canal and third molars: a survey of Australian oral and maxillofacial surgeons. *Aust Dent J* 2006;51(1):64-8.
14. Blaeser BF, August MA, Donoff RB, Kaban LB, Dodson TB. Panoramic radiographic risk factors for inferior alveolar nerve injury after third molar extraction. *J Oral Maxillofac Surg* 2003;61(4):417-21.
15. Szalma J, Lempel E, Jeges S, Szabó G, Olasz L. The prognostic value of panoramic radiography of inferior alveolar nerve damage after mandibular third molar removal: retrospective study of 400 cases. *Oral Surg Oral Med Oral Pathol Oral Radiol Endod* 2010;109(2):294-302.
16. Gomes AC, Vasconcelos BC, Silva ED, Caldas Ade F Jr, Pita Neto IC. Sensitivity and specificity of pantomography to predict inferior alveolar nerve damage during extraction of impacted lower third molars. *J Oral Maxillofac Surg* 2008;66(2):256-9.