

M. Pourafkari MD<sup>1</sup>  
 L. Ajori MD<sup>2</sup>  
 M. Fallahian MD, MPH<sup>3</sup>  
 M. Moghimi MD<sup>4</sup>  
 F. Azizi MD<sup>5</sup>

1. Assistant Professor, Department of Radiology, Shahid Beheshti University of Medical Sciences, Tehran, Iran.  
 2. Assistant Professor, Department of Obstetrics and Gynecology, Shahid Beheshti University of Medical Sciences, Tehran, Iran.  
 3. Associate Professor, Department of Infertility and Reproductive Health Research Center, Shahid Beheshti University of Medical Sciences, Tehran, Iran.  
 4. Assistant Professor, Department of Surgery, Shahid Beheshti University of Medical Sciences, Tehran, Iran.  
 5. Professor, Department of Endocrinology and Metabolism, Shahid Beheshti University of Medical Sciences, Tehran, Iran.

Corresponding Author:  
 Marina Pourafkari  
 Address: Department of Radiology,  
 Taleghani Hospital, Parvaneh St., Velen-  
 jak, Tehran, Iran.  
 Tel: +98-21-2243-2571  
 Fax: +98-21-2243-2557  
 E-mail: marina@ams.ac.ir

Received July 1, 2007;  
 Accepted after revision September 15,  
 2007.

Iran J Radiol 2008;5(2):97-100

## Ultrasonographic Findings in a Group of Iranian Patients with Primary Amenorrhea

**Background/Objective:** This study was performed to report the ultrasonographic finding and final diagnosis of a group of primary amenorrhea patients.

**Patients and Methods:** Pelvic ultrasonography (US) was employed as the first diagnostic modality to evaluate primary amenorrhea in 53 patients who were admitted to gynecology or endocrinology clinics at Taleghani hospital from 2002 to 2006. US was based upon the presence or absence of the uterus and ovaries and any other abnormal sonographic findings. Karyotype analysis was also performed for all the patients.

**Results:** The uterus was not visualized in 16 (30%) patients: due to müllerian agenesis in 14 and testicular feminization and true hermaphroditism in two other patients. Müllerian anomalies with hematometrocolpos or hematometra were seen in 5 (9%) patients. Thirty-two (60%) patients had a normal or hypoplastic uterus. Pelvic US showed that ovaries were in normal limits in 39 (73%) patients; they were not visible in 9 patients. The report of pelvic US was not conclusive in 3 patients; 2 had an ovarian tumor or cyst. Irrespective of the presence or absence of the uterus, all patients with visible ovaries (except one) had a normal karyotype.

**Conclusion:** US of the pelvis can be the initial diagnostic modality. Based on US findings, we can make decision for further work ups; there is no need to perform all paraclinical investigations for each patient.

Keywords: Amenorrhea, Ultrasonography, Diagnostic Techniques, Obstetrical and Gynecological

### Introduction

Primary amenorrhea can be diagnosed if a patient has normal secondary sexual characteristics without menarche by the age of 16, or if a patient does not have secondary sexual characteristics and menarche by the age of 14. Complete history and physical examination, as well as laboratory and imaging testing can help narrow the differential diagnosis of amenorrhea. If the patient has normal pubertal development and a uterus, the most common etiology is congenital outflow tract obstruction with a transverse vaginal septum or imperforate hymen. If the patient has abnormal uterine development but normal ovaries, müllerian agenesis is the most likely cause. In the presence of normal uterus, measurement of gonadotropin levels can help to determine the source of the abnormality. Elevated follicle-stimulating hormone (FSH) or luteinizing hormone (LH) levels suggest an ovarian abnormality (*e.g.*, hypergonadotropic hypogonadism). Normal or low FSH or LH levels suggest a pituitary or hypothalamic abnormality with a hypogonadotropic state.<sup>1</sup> Causes of primary amenorrhea can be evaluated by pelvic ultrasound in the context of the presence or absence of the uterus and ovaries. Though most cases of ambiguous genitalia are those with female pseudohermaphroditism due to congenital adrenal hyperplasia, these patients have a normal uterus and ovaries. Sonography may obviate the need for laparoscopy and other imaging modalities.<sup>2</sup>

The objective of this study was to determine sonographic findings in a large

**Table 1.** Clinical, Sonographic and Other Paraclinical Findings

Diagnosis	Number (%)	Sonographic Findings		Karyotype	Treatment
		Uterus	Ovaries		
Rokitansky	14 (26.4%)	Absent or rudimentary	Normal in 13 patients and one ovarian cyst	XX	Created neovagina
Müllerian abnormality	5 (9.4%)	Hematometocolpos or hamatometra	Normal	XX	Surgical correction
Hypothalamic	12 (22.6%)	Hypoplastic	Normal	XX	Hormone
Adrenal	8 (15.1%)	Hypoplastic	Normal	XX	Hormone
Gonadal dysgenesis, streak ovaries	8 (15.1%)	Hypoplastic	Streak or absent in 7 patients and 1 patient not conclusive	5XO, 1XX, one XY (swyer), one xx46delq13	Hormone ± gonadectomy
Testicular feminization	1 (1.9%)	Absent	Absent	XY	Gonadectomy + hormone
True hermaphroditism	1 (1.9%)	Absent	Absent	XY	Gonadectomy + hormone
True hermaphroditism with ootestis	1(1.9%)	Hypoplastic	Not conclusive	XY	Gonadectomy + hormone
Genital tuberculosis	1(1.9%)	Hypoplastic	Not conclusive	XX	Medical treatment
Arrhenoblastoma	1 (1.9%)	Normal	Tumor	XX	Oophorectomy
Undiagnosed	1 (1.9%)	Normal	Normal	XX	Hormone

group of Iranian patients with primary amenorrhea. At the end, we will discuss our proposed new algorithmic approach to primary amenorrhea according to the study.

### Patients and Methods

This study was conducted at Taleghani hospital affiliated to Shahid Beheshti university of medical sciences from 2002 to 2006. Patient's detailed history, general physical examination, presence or absence of secondary sexual characteristics, and abdominal and pelvic examination findings were noted for 53 patients with primary amenorrhea who were referred or admitted to gynecology or endocrinology clinics. Targeted investigations, including ultrasound, hormonal assay and karyotyping results were recorded. The management options were individually tailored with focus on surgical managements in those with hematometocolpos. Finally, all patients' diagnoses were confirmed according to the standard methods by clinical, sonographic, karyotypic and surgical findings. Transabdominal ultrasonography with 3.5 MHz probe (Fukuda Denshi CF Sonic UF-7500, Japan) was done for making the initial diagnosis. The basis of evaluation was on the presence or absence of the ute-

rus and ovaries and any other abnormal sonographic findings.

### Results

There were 53 patients with primary amenorrhea. The mean±SD age at diagnosis was 26.82±7.24 years. The anatomic cause of primary amenorrhea was outflow tract obstruction (müllerian anomalies) in 19 (35%), central factor (hypogonadotropic hypogonadism) in 12 (22%), and gonadal factor in 11 (20%) patients. Five patients had hypergonadotropic hypogonadism; eight had an adrenal cause (congenital adrenal hyperplasia); one had genital tuberculosis and another had androgen-producing ovarian tumor. One patient had normal hormonal, ultrasonography and karyotyping but she did not have progesterone withdrawal bleeding and the etiology of primary amenorrhea has still not been defined (Table 1).

According to the findings of transabdominal ultrasonography, the uterus was not visualized in 14 patients due to Rokitansky syndrome, in one with testicular feminization and in another one with true hermaphroditism. Five patients had hematometocolpos or hamatometra (Fig. 1). Thirty-two (60%) patients had a normal or hypoplastic uterus. Demonstration of

ovaries showed that ovaries were within normal limits in 39 patients; they were not visualized in nine patients—two had functional ovarian cyst and ovarian solid-cystic tumor. Ultrasonography was not conclusive in three patients.

All who had visible ovaries had normal karyotypes except one XY true hermaphrodite who had a two-lobed ovary which came out to be ovotestis in the pathology report. Ultrasonography showed a heterogeneous ovary and remarked it as non-conclusive.

## Discussion

There are limited case series on patients with primary amenorrhea. In 1998, Kumar assessed 48 patients with primary amenorrhea in India for three years. Twenty-six of these patients had müllerian anomaly, 11 had hypogonadotropic hypogonadism, eight had hypergonadotropic hypogonadism, and three had genital tuberculosis; their transabdominal sonography played a significant role in assessing their problems.<sup>3</sup>

Rattanachaiyanont and colleagues studied 110 patients with primary amenorrhea in Thailand retrospectively, to determine the etiologic factors of primary amenorrhea. The most common causes of primary amenorrhea were müllerian agenesis (39.65%) and gonadal dysgenesis (32.69%). Physical observation of four patients, and sonography and laparoscopy of one did not lead to a proper diagnosis. Findings in this study showed that diagnostic measures like sonography play a significant and supplementary role in the

diagnosis of primary amenorrhea.<sup>4</sup>

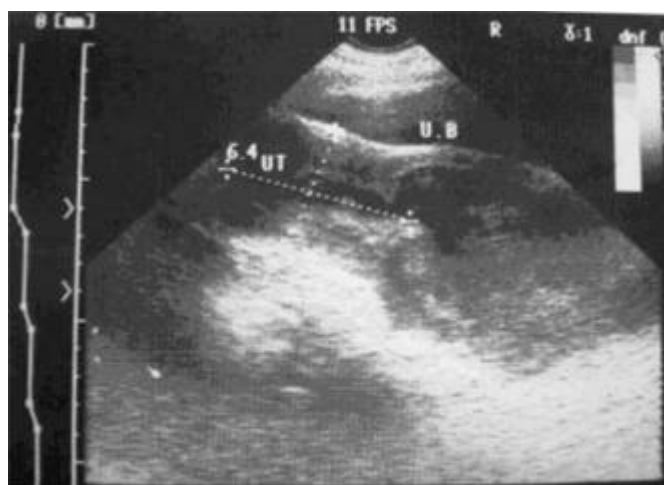Transabdominal ultrasonography of the pelvis can be the imaging method of choice for most medical problems presenting with primary amenorrhea, and its manifestations are crucial in guiding us through further work-ups.<sup>5</sup> Transperineal or translabial ultrasonographies had been proposed to assist in determining the causes of primary amenorrhea, when adequate vaginal access is not possible.<sup>6</sup>

Sonographic analysis can also be used to diagnose Turner syndrome which is characterized by the absence of the ovary. Yet, the existence of the ovary does not rule out Turner syndrome. Shawker and colleagues analyzed sonographic findings of Turner syndrome in 1986. The pelvic sonographies of 15 patients with Turner syndrome were analyzed. In patients with 45-XO karyotype, ovaries were not detected or were strip-shaped. In mosaic cases, there was a range of findings from non- or pre-mature ovaries to normal and mature ovaries.<sup>7</sup>

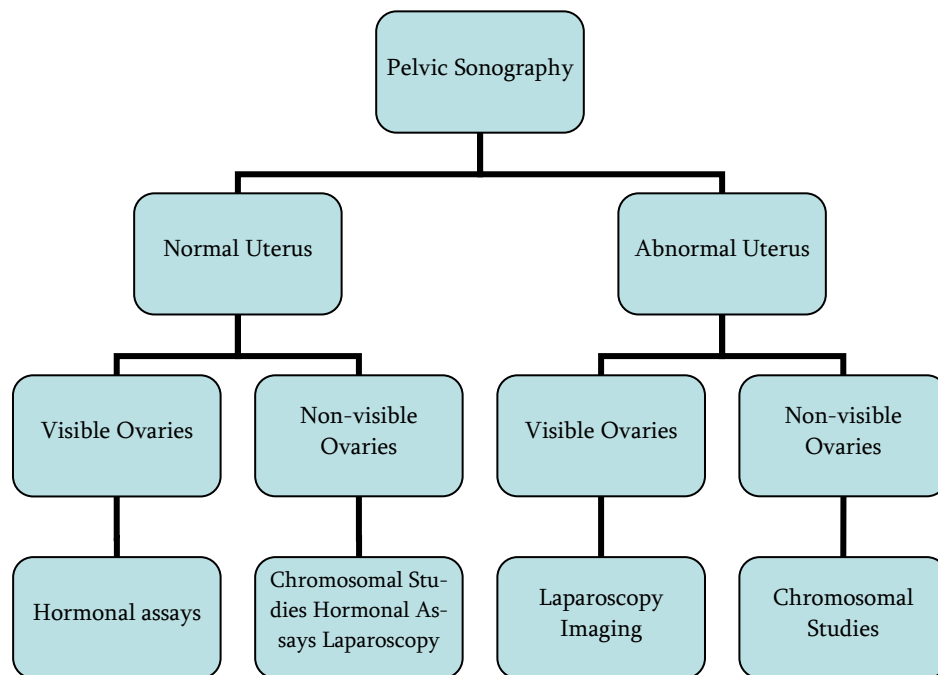
A patient-oriented approach, focused on diagnostic studies, provides an etiology in the majority of patients. As well as highlighting the role of transabdominal sonography in the work-up of these patients, this study selected patients who deserved further investigations.<sup>3</sup> Although magnetic resonance imaging (MRI) is used increasingly to inspect the uterus and cervix, it has become the imaging modality of choice for the diagnosis of congenital uterine anomalies.<sup>8</sup>

According to our experience and results, and also considering other reports, we propose an algorithmic approach based on sonography for evaluation and work-up of patients with primary amenorrhea. (Fig. 2)

Actually, we used to assess all patients with primary amenorrhea with one guideline that preserves complete laboratory and imaging tests, but this algorithm suggests that ultrasonography, as an initial imaging modality, can help us in individualizing further evaluations of patients according to the views it provides from the uterus and ovaries. Total absence or rudimentary uterus in the presence of normal ovaries during pelvic ultrasonography examination, suggests the diagnosis of Rokitansky syndrome<sup>9</sup>, and there is no need for routine chromosomal or hormonal studies. This is true for those with abnormal development of the uterus and müllerian abnormality who



**Fig. 1.** An 18-year-old patient with primary amenorrhea: Sagittal ultrasonographic view shows hematometocolpos.



**Figure 2.** The proposed algorithm based on ultrasonography findings for the diagnosis and work-up of patients with primary amenorrhea.

have visible normal ovaries. Conversely, they need further imaging or laparoscopic modalities for evaluation and diagnosis. In the presence of normal uterus and ovaries, hormonal assays should be done to find out the cause of the primary amenorrhea. Finally, if the ovaries are not visible at their normal sites or if the sonography report is not conclusive, chromosomal studies are indicated. Unfortunately, this algorithm does not always work well as it did not for a case in our series with true hermaphroditism with Y-bearing gonad. Nonetheless, this is rare. Performance of the ultrasonographies by different radiologists and also involvement of departments of gynecology, endocrinology and radiology with their own standards and diagnostic criteria were limitations of this study. Further large-scale studies are necessary to evaluate the feasibility of the proposed algorithm.

### Acknowledgement

We appreciate Ms. Yazdan, Dr. Kiamanesh and Dr. Samani for their contributions in data collection and follow-up of patients and also the departments of en-

docrinology and metabolism, Shaheed Beheshti university of medical sciences, Tehran, Iran for their technical and financial support.

### References

1. Master-Hunter T, Heiman DL. Amenorrhea: Evaluation and treatment. *Am Fam Physician* 2006 Apr 15;73:1374-82.
2. Rosenblatt M, Rosenblatt R, Kutcher R, Coupey SM, Kleinhaus S. Utero-vaginal hypoplasia: Sonographic, embryologic and clinical considerations. *Pediatr Radiol* 1991;21:536-7.
3. Kumar A, Mittal S. Primary amenorrhoea: analysis of 48 cases. *J Indian Med Assoc* 1998;96(4):119-20
4. Ruttanachaiyanont M, Kurra thikom S, Angyowattana S, Techatraisak K, Mekmahan O, Karavagul C, et al. Primary amenorrhea: a retrospective study at Siriraj hospital. *J Med Assoc Thai* 1997 Oct;80(10):619-25.
5. Spevak MR, Cohen HL. Ultrasonography of the adolescent female pelvis. *Ultrasound Q* 2002 Dec;18:275-88.
6. Meyer WR, McCoy MC, Fritz MA. Combined abdominal-perineal sonography to assist in diagnosis of transverse vaginal septum. *Obstet Gynecol* 1995 May;85(5 Pt 2):882-4.
7. Shawker TH, Garra BS, Loriaux DL, Cutler GB Jr, Ross JL. Ultrasonography of Turner's syndrome. *J Ultrasound Med* 1986 Mar;5(3):125-9.
8. Brown MA, Rachel A, Huch K, Reinhold C, Semelka R. Uterus and cervix. In: Semelka RC. *Abdominal-Pelvic MRI*. New Jersey: Wiley-Liss Inc; 2006.
9. Carranza-Lira S, Forbin K, Martinez-Chequer JC. Rokitansky syndrome and MURCS association clinical features and basis for diagnosis. *Int J Fertil Womens Med* 1999 Sep-Oct;44(5):250-5.