

L. Bayani MD<sup>1</sup>  
 A. Sadeghi Tari MD<sup>2</sup>  
 Kh. Hamzeh-doost MD<sup>3</sup>  
 A. Kasaii MD<sup>3</sup>

1. Assistant professor, Department of Radiology, Farabi Hospital, Tehran University of Medical Sciences, Tehran, Iran.

2. Associate professor, Department of Ophthalmology, Farabi Hospital, Tehran University of Medical Sciences, Tehran, Iran.

3. Assistant professor, Department of Ophthalmology, Farabi Hospital, Tehran University of Medical Sciences, Tehran, Iran.

Corresponding Author:

Leila Bayani

Address:

Eye Research Center, Farabi Hospital, Qazvin Sqr, Tehran, Iran.

Tel: 009821-88241855

Fax: 009821-88241855

E-mail: Leila.bayani@yahoo.com

Received November 12, 2005;

Accepted after revision February 14, 2006.

Spring 2006;3:173-177

## The Bony Interorbital Distance and Orbital Measurements in the Iranian Population: A CT Study

**Background/Objective:** Normal values for CT orbital measurements, which appear in reference books, may not be applicable to the Iranian population. The purpose of this study was to determine normal values in an Iranian population and compare them with published standards.

**Patients and Methods:** Orbital CT scans from adults were studied from March 2003 to June 2005. The scans had been ordered for complaints unrelated to craniofacial and orbital abnormalities, and in all of them, the presence of any pathology of the bones, globe and orbit were excluded. Four hundred CT scans (134 females, 266 males, mean age  $36.9 \pm 16.7$  years) were studied.

**Results:** The normal interorbital distance at the posterior border of the frontal process of the maxilla measured from 1.8 to 3.5 cm (mean 2.30) in men and 1.5 to 3.2 cm (mean 2.17) in women ( $p < 0.01$ ). At the level of orbital equator, the mean interorbital distance was 2.46 cm in women (range 1.7-3.2) and 2.65 cm in men (range 2-3.4) ( $p < 0.01$ ). Compared with the corresponding values of interorbital standards, all these measurements were smaller.

**Conclusion:** Normal values of orbital measurements are smaller and more varied in Iranian population and these values must be used when interpreting CT scans of the orbit.

**Keywords:** bony interorbital distance, CT scan, Iranian adults

### Introduction

The bony interorbital distance (BID) is one of the main diagnostic criteria in evaluation of the craniofacial anomalies including orbital clefts and orbital hypo- and hypertelorism.<sup>1,2</sup> Measurement of these distances is also useful for assessing the severity of such anomalies and for deciding on the choice corrective surgery.<sup>3,4</sup>

Regarding the importance of BID, during the past decades, several radiological studies have been conducted in adult western populations which have estimated the reference values for BID and variations due to different anomalies.<sup>5-8</sup> With emergence of CT scan, clearer assessments and more accurate measurements of orbital anatomy, its bony walls and BID have become feasible, which has led to more accurate clinical decision making by surgeons.<sup>3,4</sup> Mafee and co-workers described the normal range of the bony interorbital distance and other useful orbital measurements from four hundred CT scans of orbits in American adults who had CT for other purposes.<sup>9</sup> According to their results, the normal standard of orbital and interorbital measurements were established and published.<sup>3</sup>

Considering the ethnic and genetic differences between the Iranian and western populations, and the lack of data for BID values in the Iranians, this study has measured BID in a group of Iranian men and women using CT scan.

### Patients and Methods

The study population consisted of 400 Iranian adults (266 men and 134 women)

with normal orbits that referred to the CT department of Farabi eye hospital for visual disturbance after cerebrovascular events, brain tumors (without extension or metastasis to orbits) and skull trauma, from March 2003 to June 2005. None of them had any underlying craniofacial anomalies in the bony orbit (e.g. orbital hypoplasia and pathologic bone lesion), or orbital soft tissue (e.g. fibrous dysplasia), benign or malignant tumors of the orbit or brain parenchymal tumors (like glioma which involves orbits), trauma, congenital defect of the bone or soft tissue malformation (e.g. neurofibromatosis), anatomical deformities, myositis, thyroidal ophthalmopathy, metastasis to the orbit and globe, optic nerve lesions (e.g. glioma or meningioma), skull trauma associated with facial fracture, or fracture of any parts of the orbit. Personal and medical data were collected from all patients using a questionnaire, using a simple non-random sampling method.

Individuals were examined using a Picker CT 1200 SX scanner, to obtain uniform images for linear measurements, the window width and level were set at 400 and 60, respectively, for all patients, and CT data were collected from the nonrotated orbital sections at the plane of the optic nerves.

The horizontal CT sections through the orbits at this level generally show two appearances: (1) a parallel separation of the medial orbital walls and, (2) a fusiform or lateral spread of the ethmoidal air cells with the widest separation of the orbital walls occurring at the posterior pole of the globe.<sup>3</sup>

The distance between the medial walls of the bony orbits at various points and other measurements are illustrated in Figures 1 and 2. There are several reference points: the anterior pole is the central point of the anterior curvature of the eyeball and the posterior pole is the central point of its posterior curvature. These points are designated as point A and point B, respectively (Figure 1) and the line joining the two poles forms the optic axis (AP).

The primary axes of the two eyeballs are nearly parallel. The lacrimal bone and the lamina papyracea make a thin line of increased density posterior to the frontal process of the maxilla.

CT is the best method to evaluate the optic canal and optic nerves. The cranial opening of the optic canal is well demonstrated in Figure 2A. The optic

canal lies between the two roots of the lesser wings and is bounded medially by the body of the sphenoid bone. The anterior root is broad and flat and is continuous with the planum sphenoidale. The posterior root is shorter, thicker, and connected to the body of the sphenoid opposite the posterior border of the sulcus chiasmaticus.

In Figure 2, the JJ line is the distance between the central optic canals at their cranial openings, and the AT line shows the anteroposterior diameter of the globe on the anteroposterior (optic) axis, anterior to the interzygomatic line, that is important in the diagnosis of exophthalmia.

Statistical analysis was performed using SPSS version 11.5. Student's t-test was used to compare the means between the two genders. The level of significance was set at 0.05.

## Results

The average age of 400 participants (266 (66%) men and 134 (34%) women) was  $36.9 \pm 16.7$  years. The mean, standard deviation, maximum and minimum of measurements of the bony interorbital distance and some other orbital measurements are shown in Table 1. The narrowest interorbital distance at the site of the optic nerve was at the posterior border of the frontal process of the maxilla (2.3 cm in males, 2.2 cm in females), and the widest distance was at the level of the posterior poles of the eyeballs. There was no significant difference between the orbital measurements on either sides.

## Discussion

The results of this study provide the first report of reference values of the orbital diameters and the bony interorbital distance in an adult Iranian population. Almost all our measurements in this Iranian group were smaller, as compared to the corresponding values of interorbital standards and references, in the study by Mafee in the US.<sup>2,9</sup>

However the narrowest and widest interorbital distances reported in both Iranian and American studies are at the posterior border of the frontal process of maxilla and behind the posterior poles of the eyeballs, respectively. There is marked heterogeneity in race, age and many other factors between these two popu-

**Table 1.** CT orbital measurements in 400 Iranian adults

Line, Description	Measurements					
	Male			Female		
	Mean (SD)	Min.	Max.	Mean (SD)	Min.	Max.
AA, Approximates interpupillary distance	6.5(0.4)	5.3	7.8	6.3(0.4)	5.0	7.3
BB, BID measured at posterior border of frontal processes of maxillae	2.3(0.3)	1.8	3.5	2.2(0.3)	1.5	3.2
CC, BID measured posteriorly or at level of orbital equator	2.6(0.3)	2.0	3.4	2.3(0.3)	1.7	3.2
DD, distance between anterior margin of frontal processes of zygomatic bones at level of plane of optic nerves	4.7(0.4)	8.0	11.0	9.4(0.4)	8.0	10.3
EE, distance between optic nerves where they enter eyeballs	5.4(0.4)	4.1	6.5	5.2(0.4)	2.7	6.3
FF, BID measured at level of posterior poles of eyeballs	2.9(0.3)	2.1	4.0	2.7(0.3)	1.8	3.0
HH, BID measured at its most posterior part (apex of bony orbit)	2.9(0.3)	2.1	4.0	2.6(0.4)	2.0	4.1
JJ, distance between central position of cranial opening of optic canals	1.9(0.3)	1.2	3.2	1.9(0.2)	1.2	2.7
KK, distance between tips of anterior clinoid processes	2.6(0.3)	1.9	3.5	2.4(0.2)	1.8	3.0
EJ, length of intraorbital part of optic nerve						
Right	2.6(0.3)	2.0	3.2	2.6(0.3)	2.0	3.6
Left	2.6(0.3)	2.0	3.2	2.6(0.3)	2.0	3.6
AP, anteroposterior diameter of eyeball						
Right	2.4(0.2)	2.0	3.3	2.4(0.2)	2.0	3.0
Left	2.6(0.2)	2.0	3.2	2.6(0.2)	2.0	3.2
AT, anteroposterior diameter of eyeball on anteroposterior (optic) axis anterior to interzygomatic line						
Right	1.6(0.2)	1.1	2.1	1.4(0.2)	1.2	1.9
Left	1.6(0.2)	1.1	2.1	1.5(0.2)	1.2	1.9

BID: Bony Interorbital Distance p< 0.01 tp< 0.05 compared with male

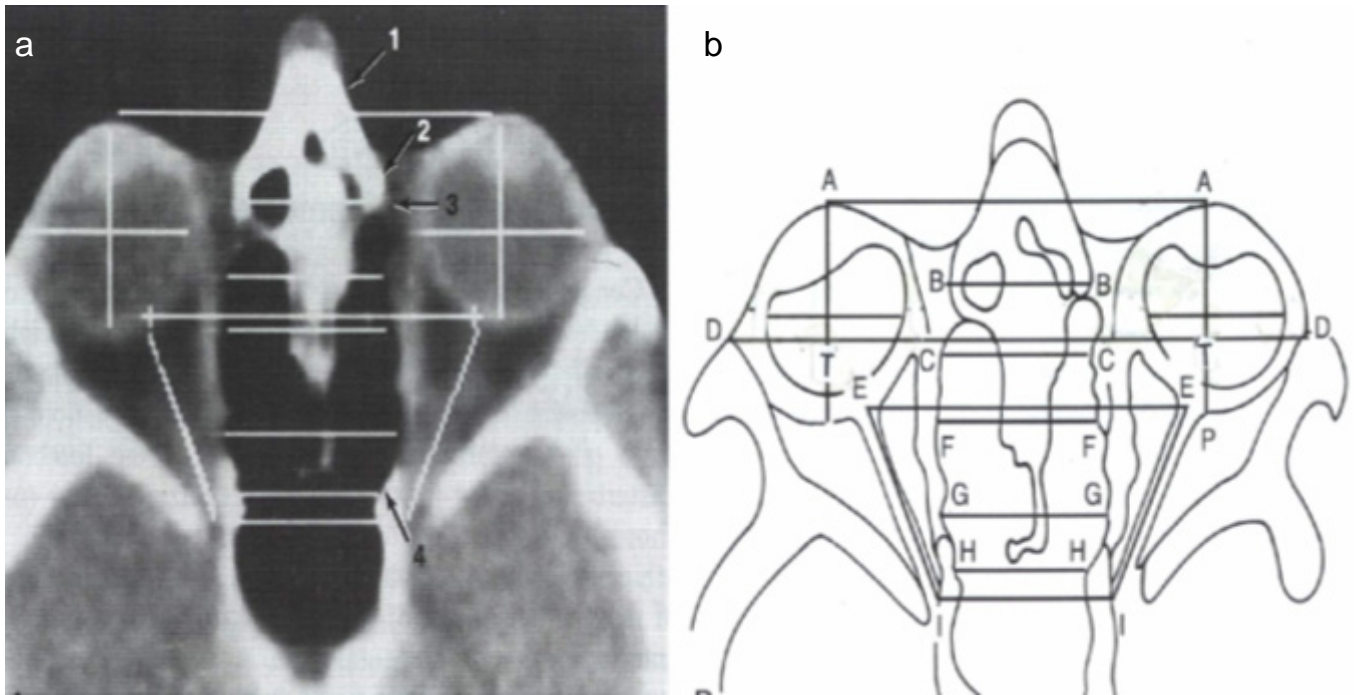
lations (Iranians and Americans) and since the details of the data from Mafee study was unavailable, applying similar statistical test for comparison between the two groups does not seem to be accurate. On the other hand, the purpose of this study is to obtain normal standard measurement of BID and other orbital distances in an Iranian population, not comparison between the two groups.

The bony interorbital distance is an important index and an essential measurement in diagnosing orbital hypotelorism and hypertelorism.<sup>5-10</sup>

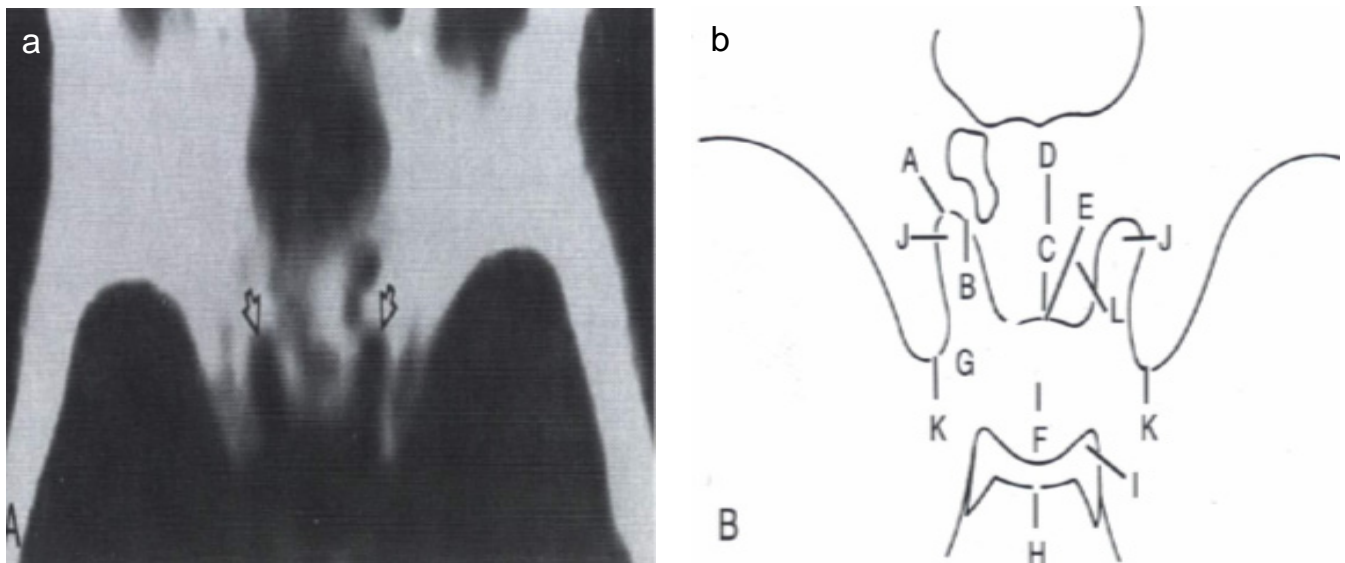
Before the advent of CT, the main methods used for such measurements have been based on cephalomet-

ric radiography and conventional posteroanterior projection.<sup>5-8,10,11</sup> Although such methods may be useful in the evaluation of normal individuals, their usefulness in pathologic conditions is questionable.

CT and base tomography are the best methods to evaluate the bony interorbital distance, since conventional radiography is a composite of various structures at different planes, rendering identification of measurement landmarks in some patients difficult.<sup>9</sup> Furthermore, CT provides significant information on facial and ethmoidal bones, sphenoid sinus, the median and paramedian craniofacial clefts and even central nervous system pathology.<sup>2</sup> For example CT can



**Fig 1.** a, Axial CT scan of the orbit at the level of the optic nerves shows the outline of the globes, lenses, and vitreous bodies, level of the medial check ligament (3), medial and lateral rectus muscles, optic nerves and retroorbital fat compartments, nasal bones (1) and frontal process of the maxilla (2) on either side. The lamina papyracea is seen as a very thin density hardly distinguishable from the medial aspect of the medial rectus muscle. Posterior to that is the most posterior part of the medial wall of bony orbit (4), which is related to the anterior part of the sphenoid sinus. b, diagram shows different points selected for various measurements presented in Table 1.



**Fig 2.** a, Axial CT scan of the head at the level of the planum sphenoidale and anterior roots of lesser wings shows the cranial opening of the optic canals. b, diagram shows structures in a. A, cranial opening of optic nerves. B, anterior wing of the lesser wing of sphenoid. C, posterior border of the chiasmatic groove. D, planum sphenoidale. E, tuberculum sellae. F, pituitary fossa. G, middle clinoid. H, dorsum sellae. I, posterior clinoid. K, anterior clinoid. L, anterior border of the chiasmatic groove.

be valuable in patients with severe nasomaxillary hypoplasia who were clinically found to have hypertelorism.

In these cases, CT clearly shows the nasal and maxillary deformity but the bony interorbital distance is normal. Increased soft tissue in the nasoorbital angles

has created the appearance of pseudo hypertelorism or telecantus.<sup>12</sup>

The bony interorbital distance for girls, according to Hansman's study based on radiographs of a large group of healthy subjects, is consistently narrower than for boys, from infancy to adulthood.<sup>8</sup> Starting at

year 1, there is graded increase in the size of the measurements for both genders. In girls, growth begins to level off at about 13 years of age. Since in boys it continues to increase till the age of about 21 years, the measurements in girls fall more markedly behind the boys' as growth is completed. The average adult measurement for BID in women was reported to be 25 mm and 28 mm in men.<sup>8</sup> In the present study all measurements in women are smaller than those in men, and most of the differences have statistical significance. According to Maffe study, similar differences were shown in American women compared to men, except for the values measured posterior to or at the level of the orbital equator, the distance between the anterior margin of the frontal processes of zygomatic bones, at the level of the plane of optic nerves, the values of the bony interorbital distance measured at its most posterior part (apex of bony orbit), and the distance between the tips of the anterior clinoid process.<sup>9</sup> Since no statistical test was used to examine the differences, it is difficult to compare the measurements of the two genders in his study.

The mean and maximum values of AT diameter, the anteroposterior diameter of the globe on anteroposterior (optic) axis anterior to the interzygomatic line, were 1.5 cm and 1.9 cm in women and 1.6 cm and 2.1 cm in men, respectively. According to the current references based on western populations, values more than 2.1 cm are diagnostic for exophthalmia, which may not be applicable to Iranian women.<sup>12</sup>

Even though this study was carried out in a referral center in Tehran and the participants came from all over the country, it is advisable that future studies be performed with larger samples including various ethnic populations of Iran.

Finally, we conclude normal values of bony interorbital distance and some other orbital measurements are smaller and more varied in this Iranian population compared to published standards of western populations, and therefore Iranian reference values must be considered when interpreting CT scans of the orbit.

## References

1. Mafee MF, Valvassori GE. Radiology of the craniofacial anomalies. *Otolaryngol Clin North Am* 1981; 14: 939-988
2. Converse JM, McCarthy JG, Wood-Smith D. Reconstructive plastic surgery for orbital hypertelorism. In: Converse JM, McCarthy JG, Wood-Smith D. Symposium on diagnosis and treatment of craniofacial anomalies, vol 20. St. Louis: Mosby; 1979: 207-221
3. Peter MS, Hugh DC. Head and Neck Imaging. 4th edition, vol 1. St. Louis: Mosby; 2003: 551-555
4. Becker MH. Computed tomography in the evaluation of the craniofacial malformations. in: Converse JM, McCarthy JG, Wood-Smith D. Symposium on diagnosis and treatment of craniofacial anomalies. Vol 20. St. Louis: Mosby; 1979: 182-185
5. Cameron J. Interorbital width. New cranial dimension. Its significance in modern and fossil man in lower mammals. *Am J Phys Anthropol* 1931; 15: 509-515
6. Currarino G, Silverman FN. Orbital hypotelorism, arhinencephaly, and trigonocephaly. *Radiology* 1960; 74: 206-217
7. Gerald BE, Silverman FN. Normal and abnormal interorbital distances with special reference to mongolism. *Am J Radiol* 1956; 95: 154-161
8. Hansman CF. Growth of interorbital distance and skull thickness as observed in roentgenographic measurements. *Radiology* 1966; 86 : 87-96
9. Mafee MF, Pruzansky S, Corrales MM, Phatak MG, Valvassori GE, Dobben GD et al. CT in the evaluation of the orbit and bony interorbital distance. *Am J Neuroradiol* 1986; 7: 265-269
10. Tessier P. Orbital hypertelorism I: Successful surgical attempts, material and methods, causes and mechanism. *Scand J Plast Reconstr Surg* 1972; 6: 155-185
11. Campbell JA. Craniofacial anomalies in: Newton TH, Potts DG, eds. *Radiology of the skull and brain*, vol 1, book 2. St. Louis: Mosby; 1971: 571-633
12. Mustarde JC. Epicanthus and telecanthus. *Br J Plast Surg.* 1963; 16: 346-56

