

F. Tafaghodi MD<sup>1</sup>  
L. Atarod MD<sup>2</sup>  
K. Daneshjou MD<sup>2</sup>

## Lymphocytic Interstitial Pneumonia: A Pediatric Case from Iran

We describe a 12-year-old girl with lymphocytic interstitial pneumonia (LIP) with common variable immunodeficiency (CVI). The patient was under closely followed during acute and remission phases, especially in her last year of life. We believe this case is an informative example of LIP in Iran.

**Keywords:** lung disease, pneumonia, interstitial, lymphoproliferative disorders

### Introduction

Lymphocytic interstitial pneumonia (LIP) is an uncommon disorder with benign proliferation of mature small lymphocytes and plasma cells in the interstitium and alveolar spaces of the lungs, with a wide range of severity from benign to malignant lymphoma.<sup>1-2</sup>

Small series of LIP have been reported with most patients being adults. It is rare in children; commonly it is seen in children with AIDS. Symptoms are usually insidious with mild hypoxemia, cough and progressive respiratory distress. The purpose of this report is to present a pediatric case of LIP not associated with AIDS, which to our knowledge has not been previously reported from Iran.

### Case presentation

A 12-year-old girl presented with fever, productive cough, weakness, myalgia and mouth thrush. In her past medical history, she had febrile convulsion when she was 2 years old, and underwent rectal polypectomy at the age of 5 for anal abscess.

At the age of 9, Crohn's disease was suspected on colonoscopy and she was treated for 4 years.

The immunological studies revealed hypogammaglobinemia (low IgG, low IgA) and low CD4+ T lymphocytes, she received monthly IVIG. Physical examination at the time of presentation to hospital revealed hepatosplenomegally and friction rub throughout both lungs. Marked digital clubbing was also noted. The bronchoalveolar lavage (BAL) sample was positive for EBV-1 and CMV (using PCR method). BAL sample was negative for fungal elements.

Admission chest x-ray showed bilateral, diffuse reticulonodular opacities, predominantly alveolar shadow, at the base of right lung (Figure 1). Opportunistic infection was suspected clinically, and therefore antibiotic and antifungal therapies were administered (vancomycin, amphotericin B, itraconazole).

Total T and B lymphocyte counts were normal, while natural killer cell count was low (CD 16, CD56). Chemotaxis and NBT were normal. Flow cytometry was repeated several times and showed normal CD3, CD8 and CD19, and

1. Assistant Professor, Department of Radiology, Imam Khomeini Hospital, Tehran University of medical sciences, Tehran, Iran.

2. Assistant Professor, Department of Pediatric, Imam Khomeini Hospital, Tehran University of medical sciences, Tehran, Iran.

Corresponding Author:

Farhad Tafaghodi

Address:

Department of Radiology, Imam Khomeini Hospital, Tehran University of medical sciences, Tehran, Iran.

Tel: 009821- 88009730

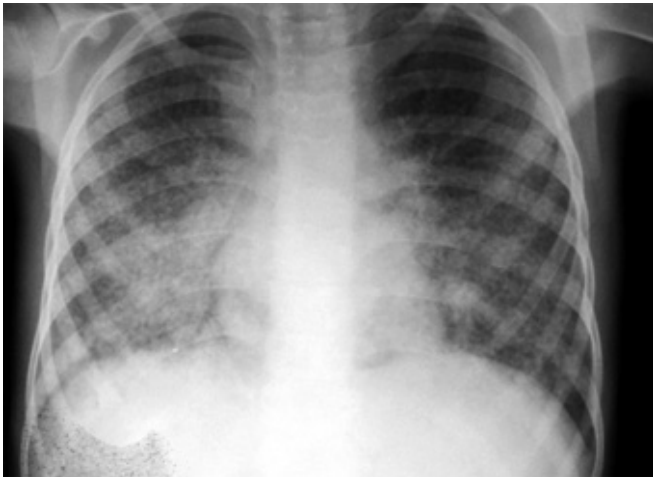
Fax: 009821- 88011001

E-mail: Tafaghodi 2001@ yahoo.com

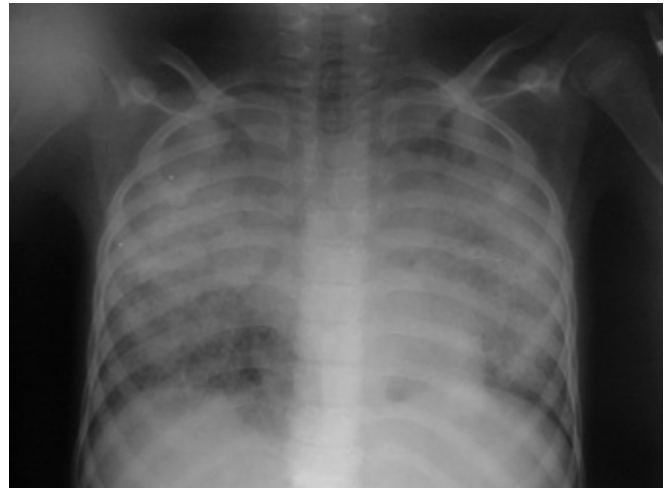Received October 31, 2005;

Accepted after revision April 9, 2006.

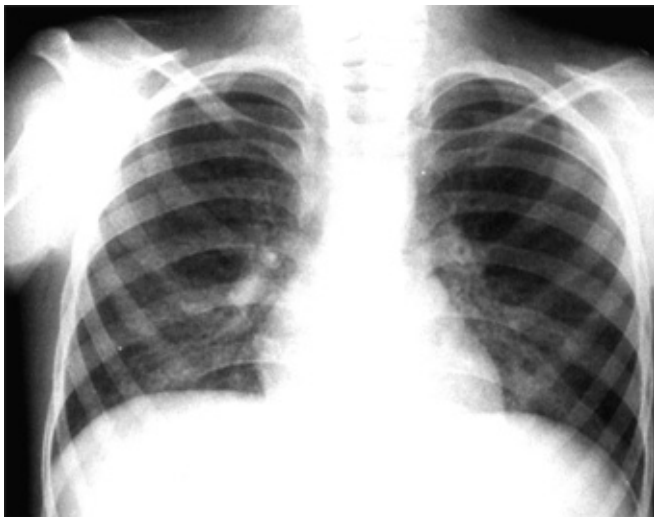Spring 2006; 3: 179-183



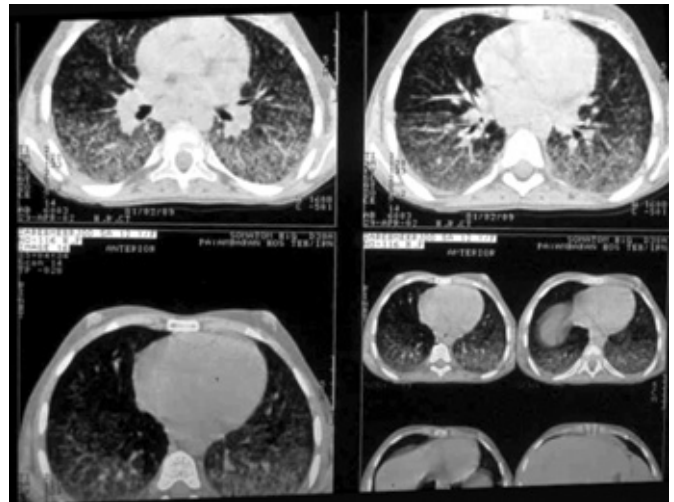
**Fig 1.** (8th of Dec 2001); The admission chest x-ray shows bilateral ,diffuse reticulonodular opacities, more alveolar shadow on the right base.



**Fig 2.** (11th Dec,2001); Chest X-ray of the 4th day of admission, shows bilateral, diffuse alveolar shadow in the mid and upper zones.



**Fig 3.** (20th Feb,1998); previous chest X- ray done 3 years earlier showed. bilateral linear marking with minimal nodularity on the right side.

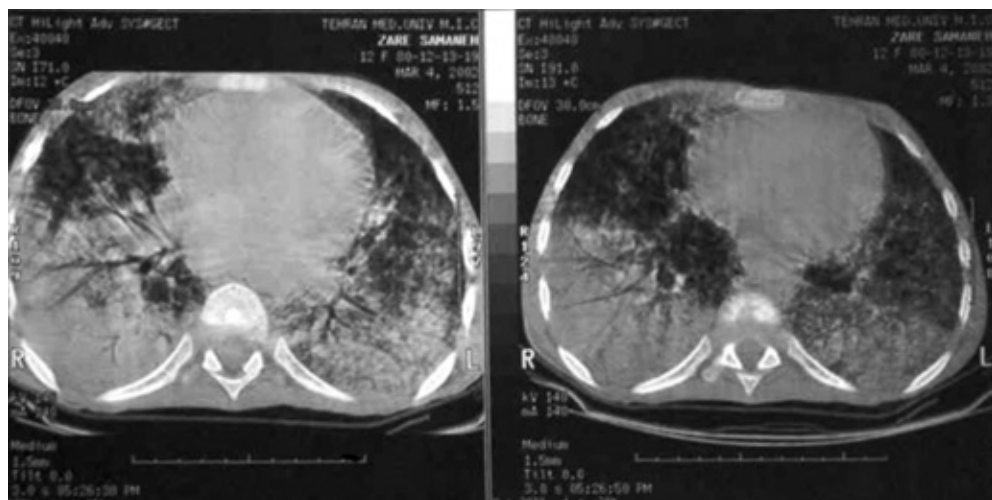


**Fig 4.** (11th Sep 1999); Previous CT was done 2 years before showed bilateral, diffuse reticulonodularity, more prominent on the right side ground glass shadows in some areas, minimal pleural thickening.

low CD4, CD16 and CD56. The findings were in favor of common variable immunodeficiency (CVID). Blood and urine cultures were negative.

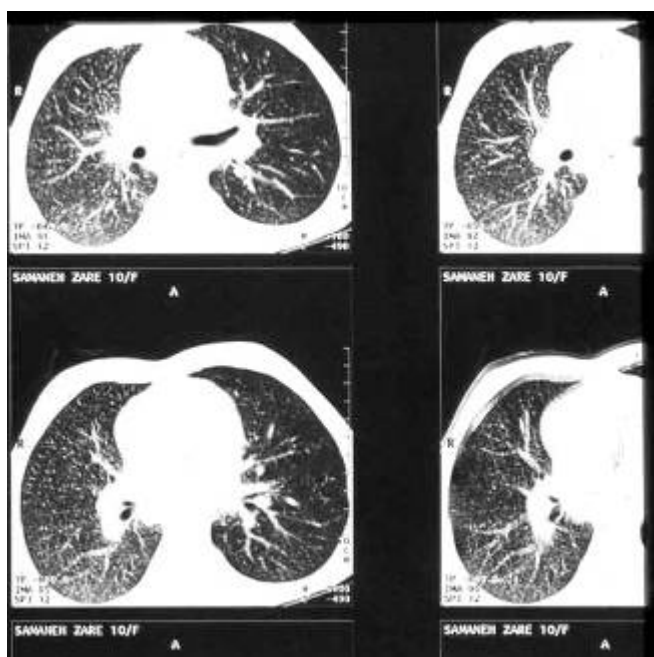
She developed respiratory distress on the 4th day of admission. Chest x-ray showed bilateral, diffuse alveolar shadows in the mid and upper zones (Figure 2). In reviewing the previous films, a chest x-ray taken 3 years earlier showed bilateral linear markings with minimal nodularity on the right side (Figure 3). A previous CT-scan taken 2 years earlier showed bilateral, diffuse reticulonodularity, more prominent on the right side with ground-glass shadows in the mid and upper zones, associated with some pleural thickening (Figure 4).

The patient gradually recovered from acute respiratory symptoms. The following serial films showed the alveolar shadows were subsequently replaced by interstitial shadows as the patient clinically recovered. Lung biopsy was performed that yielded heavy interstitial infiltrates of mononuclear cells, predominantly small-to-medium sized lymphocytes; and thus, implying a diagnosis of lymphocytic interstitial pneumonia. On the basis of lung biopsy, hydrocortisone and hydroxychloroquine were administered. The patient was discharged after 25 days with a relatively satisfactory general condition. Follow-up chest x-ray a week after discharge showed linear densities at both lungs bases.



**Fig 5.** (4th March 2002); HRCT of and chest showed diffuse, bilateral alveolar shadows, during acute phase.

She was re-admitted one month later with a clinical picture of dyspnea, restlessness, agitation, and decreased level of consciousness. Brain CT was normal. X-ray showed fluffy alveolar opacities distributed throughout both lungs. HRCT of the chest showed diffuse bilateral alveolar shadows, more prominent on the right side, with some areas of ground-glass opacities (Figure 5). CSF study was suggestive of aseptic meningitis. Bone marrow biopsy and aspiration were normal. Hydrocortisone, dexamethasone, and gancyclovir were administered. As the patient gradually recovered, the alveolar shadows displayed nodu-



**Fig 6.** (29<sup>th</sup> AP, 2002); CT, during recovery; centrilobular nodules, ground-glass opacities as the patient respiratory symptom's were subsided.

larity with some linear markings.

On her third admission, she suffered from back pain, headache, vertigo, and was unable to walk. Thoracolumbar x-ray and CT showed decreased disc spaces of T11–12, T12–L1, with no evidence of bony destruction. The cause remained obscure; yet, there was a possibility of EBV discitis.

A week later, the patient showed some recovery. HRCT showed centrilobular nodules, ground glass and honeycombing in some areas (Figure 6).

Four bouts of respiratory distress occurred to our patient over 9 months. On her fourth admission, she developed headache, and unconsciousness. Serum EBV IgG rose to 7.8 units and CSF anti-EBV IgG rose to 3 units over three months—therefore, EBV meningitis was suspected, which responded to the appropriate therapy.

A month later, she again developed respiratory distress and the chest x-ray showed bilateral alveolar shadows. No evidence of HIV infection was detected during all admissions. All findings are summarized in Table 1. She deceased of respiratory failure at a hospital in her homeland city of Yazd, two months after being discharge from our service.

## Discussion

Lymphocytic interstitial pneumonitis (LIP) has been called the most benign lymphoproliferative disorder, which involves the lungs. The dominant microscopic features of LIP are diffuse, polyclonal lymphoid cell infiltrate surrounding airways and expanding into the interstitium.<sup>2</sup> The pathological differential diagnoses include pseudolymphoma that represents a localized mass-like variant of LIP (a dense lymphoid-cell collection identical to LIP), hypersensitivity pneumonitis, plasma cell interstitial pneumonitis, and lymphoma.<sup>3-6</sup>

The natural history and prognosis of LIP are poorly understood and there is great variability in its clinical

course, from spontaneous resolution to progressive respiratory failure and death.<sup>1,2,5</sup> The latter occurred in our patient. Some patients, progress to chronic pulmonary disease with significant fibrosis.

Strimlan and associates found cough and dyspnea were the most common presenting symptoms with a high frequency of Epstein-Barr virus (EBV) infection—all seen in our case. In the literature, LIP is most commonly associated with underlying states of immunodeficiency, including Sjogren syndrome, primary biliary cirrhosis, chronic active hepatitis, common variable immunodeficiency, rheumatoid arthritis, Hashimoto's thyroiditis and AIDS.<sup>7-16</sup> LIP is found in 22-75% of pediatric patients with HIV who have pulmonary disease.<sup>15</sup> No evidence of HIV infection was found in our case; but the association with common variable immunodeficiency was detected. Mediastinal lymph nodes enlargement was seen in those with AIDS, and not seen in our patient.

Cyanosis and clubbing were present in roughly half of the patient described in one study, as seen in our case as well.<sup>13</sup> To our knowledge, LIP in a non-AIDS patient has not been reported from Iran.

CT features of LIP have been described in a small number of patients.<sup>17</sup> Carignan et al. described extensive bilateral ground-glass attenuation, focal areas of consolidation, ill-defined nodules and thick-walled cystic lesions on CT-scan of patients with lympho-

cytic interstitial pneumonia.<sup>13</sup>

Johkoh et al. studied HRCT in 22 adult patients with lymphocytic interstitial pneumonia.<sup>7</sup> Finding predominantly consisted of areas of ground-glass attenuation, poorly defined centrilobular nodules, air space consolidation, and pleural thickening, which were observed in our patient as well. Other common findings included thickening of bronchovascular bundles, cystic air spaces, and lymph node enlargement, which were not encountered in our patient.

Julsurd et al. described two general radiographic patterns on x-ray in 13 patients.<sup>3</sup> The first was a bilateral, predominantly basilar, coarse interstitial pattern. The second pattern was fluffy alveolar infiltrates distributed throughout both lungs. It was not clear to them whether these two patterns represented two distinct disease processes, or two stages of the same pulmonary abnormality. Whereas, both patterns were seen in our case, which correlated to her clinical situation. During her three episodes of acute respiratory distress, fluffy alveolar opacities were seen both on chest x-ray and CT-scan. However, when the patient's respiratory symptoms subsided, the radiological appearances were coarse reticulonodular patterns involving mainly the lower zones on chest x-ray, ground-glass opacities and poorly defined centrilobular nodules seen on CT-scan. Therefore, our observation suggests that these two different patterns

**Table 1.** Summary of findings during all admissions.

	First admission; 25 days		2 <sup>nd</sup> admission; 27 days		3 <sup>rd</sup> admission; 41days		4 <sup>th</sup> admission; Two months	
	Resp. distress	recovery	Resp. distress	recovery	vertigo	recovery	unconsciousness	Resp. distress
IgM (mg/dl)	-		38	53	20	-	30	
IgG (mg/dl)	-		520	470	668	-	595	
IgA (mg/dl)	-		39	60	19	-	36	
EBV(IgG) BAL	0.4		-	-	-	-	-	
EBV(IgM) BAL	0.1		-	-	-	-	-	
EBV(IgG) serum	1.0		1.8	-	7.8	-	3.8	Index
EBV(IgM) serum	0.1		0.1	-	0.1	0.08	1.0	IU/ml
EBV( IgG) CSF	-		-	-	0.2	3	0.2	Index
EBV(IgM) CSF	-		-	-	0.1	-	1.0	IU/ml
Hbc,AntiHIV,HbsAg,HbeAg,	Negative							
Chest	Alveolar shadows	Reticulo-nodular	Alveolar shadows	Nodular-shadow	-	-	Reticulonodular shadow	Alveolar shadows
CT	-	-	Alveolar Shadows	-	Ground-glass nodularity	-	-	-

described by Julsrud et al. are likely to be two stages of a single disease.<sup>3</sup>

Differential diagnoses of the alveolar shadows on chest x-ray of a patient with LIP include pulmonary edema, aspiration pneumonia, opportunistic infections, drug toxicity, alveolar proteinosis, and hypersensitivity pneumonitis. On CT-scan, which displays more details of LIP such as centrilobular nodules, and ground-glass attenuation, mycobacterial or fungal infection, alveolar microlithiasis, and desquamative interstitial pneumonitis can be added to the list of differential diagnoses.

## References

1. Merk. The Merk manual of diagnosis and therapy. 17th ed. Merk research laboratories. Wiley, John & Sons, Incorporated; 1999: 639
2. Swigris JJ, Berry GJ, Raffin TA, Kuschner WG. Lymphocytic Interstitial Pneumonia. *Chest* 2002; 122: 2150-2164
3. Julsrud PR, Brown LR, Li CY, Rosenow EC 3rd, Crowe JK. Pulmonary processes of mature-appearing Lymphocytes. *Radiology* 1978; 127: 289-296
4. Johkoh T, Muller NL, Pickford HA, Hartman TE, Ichikado K, Akira M et al: Lymphocytic Interstitial Pneumonia: thin section CT in 22 patients. *Radiology* 1999; 212: 567-572
5. Saukkonen JJ, Peters SP, Talavera F, Ouellette DR, Zab Mosenifar TD. Lymphocytic Interstitial Pneumonia. *e Medicine journal* 2001; 2: 1-18
6. Lynch D. Imaging of diffuse lung disease. Hamilton: B.C.Decker Inc; 2000; 23-27
7. Kaan PM, Hegele RG, Hayashi S, Hogg JC. Expression of bcl-2 and Epstein - Barr virus LNPI in lymphocytic interstitial pneumonia. *Thorax* 1997; 52: 12-19
8. Simmank K, Meyers T, Galpin J, Cumin E, Kaplan A. Clinical features and T- cell subsets in HIV-infected children with and without lymphocytic interstitial pneumonitis. *Ann Trop Pediatrics* 2001; 21: 195-201
9. Fishback N, Koss M. Update on Lymphocytic Interstitial Pneumonia. *Curr Opin Pulm Med* 1996; 2(5): 429-433
10. Oldham SA, Castillo M, Jacobson FL, Mones JM, Saldana MJ. HIV-associated lymphocytic pneumonia: radiologic manifestation and pathologic correlation. *Radiology* 1989; 170: 83-87
11. Nikolaidou P, Charocopos E, Anagnostopoulos G, Lazopoulou D, Kairis M, Lourida A et al. Cellular interstitial pneumonia in children: response to hydroxychloroquine treatment in two cases. *Pediatr Asthma Allerg immunol* 2003; 16: 45-51
12. Frazer R.S. Diagnosis of disease of the chest. 4th ed .Philadelphia: WB Saunders; 1999: 1271-1273
13. Carignan S, Staples CA, Muller NL. Intrathoracic lymphoproliferative disorders in the immunocompromised patient: CT finding. *Radiology* 1995; 197: 53-58
14. Becciolini V, Gudinachet F, Cheseaux JJ, Schnyder P. Lymphocytic interstitial pneumonia in children with AIDS: high -resolution CT findings. *Europ Radiol* 2001; 11: 1015-1020
15. Leland L.Fan: Interstitial lung disease in children. National Jewish medical & research center 1995; 3: 1-8
16. Almasi F, Hajabdolbaghi M, Rasooli Nejad M. HIV infection in children: case reports. *The Journal of faculty of Medicine* 2005; 63: 425-431
17. Webb WR, Muler NL, Naidich DP. High resolution CT of the lung 3rd ed.Philadelphia: Lippincott Williams & Wilkins; 2001:276-277