

LETTER TO EDITOR

How 3-Dimensional and Live 3-Dimensional Vaginal Ultrasound May Help in Diagnosing Mullerian Anomalies [(3-Dimensional Priorities over Histerosalpingography (HSG))]

Dear Editor,

Sometimes we face patients in whom hysterosalpingography (HSG) could not show certain mullerian anomalies because of technical limitations but vaginal three dimensional (3D) ultrasound could help well.

Recently 3D ultrasound has become available in gynecological practice. It is a noninvasive, outpatient modality and could assess the details of uterine morphology.

Previous studies explained that HSG is not a reliable technique for detecting congenital uterine malformations, with false-positive results of about 38% and the sensitivity of about 44%. In addition, this exam cannot differentiate septated from bicornuate uterus.^{1,2}

The advantages of 3D ultrasound and 3D hysterosonography over conventional X-ray HSG are simultaneous assessment of the uterine cavity and outer uterine outline; therefore, it shows the fundal shape and fundal cleft and could differentiate between the arcuate, septated and bicornuate uterus.³⁻⁵

We decided to explain one of our cases to show 3D vaginal ultrasound priority over conventional HSG in diagnosing mullerian anomalies. She is a 32-year-old woman with a past history of infertility from 12 years ago. The HSG report was normal (Fig. 1). We performed a vaginal ultrasound study which was suspicious for an arcuate or septated uterus (Fig. 2. A & B), then 3D revealed convex external uterine contour associated with fundal endometrial indentation (Fig. 3). The depth of fundal endometrial indentation was about 8 mm indicative of a subseptated uterus. The distance between the two internal tubal ostia was about 36 mm. The ratio of the depth of fundal endometrial concavity to the interostial line was about 22% which is significant (in cases with a less than 10% ratio, an adverse reproductive outcome is not expected).⁶ Findings indicate the usefulness of operative hysteroscopy in this case.

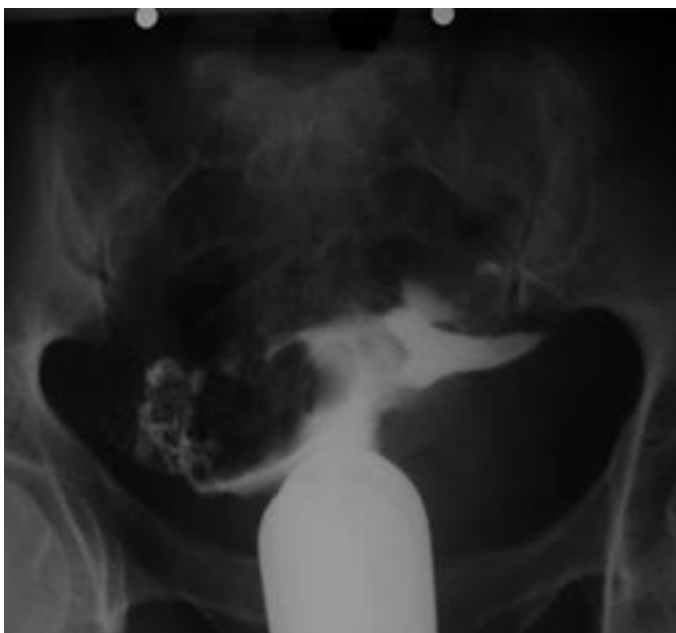

Fig. 1. HSG was reported normal.

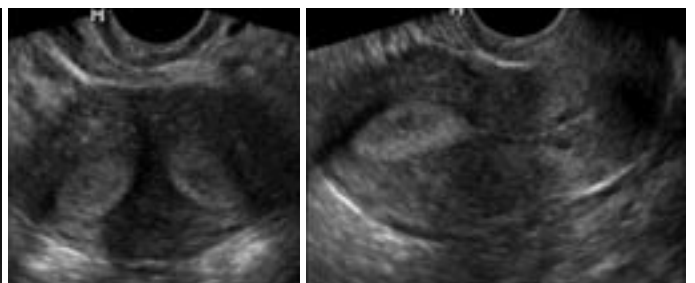


Fig. 2. Vaginal ultrasound study was suspicious for an arcuate or septated uterus.

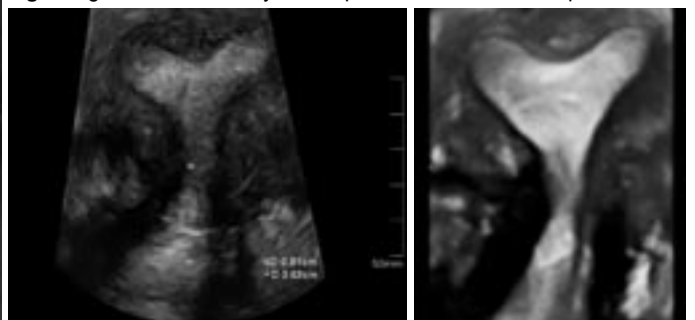


Fig. 3. 3D and live 3D confirmed subseptated uterus.

Authors:

F. Ahmadi MD¹

M. Noori MD²

M. Nik Nejadi MD¹

F. Zafarani BSc²

1. Assistant Professor of Radiology, Department of Reproductive Imaging, Royan Institute, Tehran, Iran.

2. Department of Reproductive Imaging, Royan Institute, Tehran, Iran.

Corresponding Author:

Maryam Noori

Address: Department of Reproductive Imaging, Royan Institute, Tehran, Iran.

Tel: +9821 2630 0027

Fax: +9821 2233 9935

E-mail: m_noori5005@yahoo.com

References

1. Raziel A, Arieli S, Bukovsky I, Caspi E, Golan A. Investigation of the uterine cavity in recurrent aborters. *Fertil Steril* 1994 Nov;62(5):1080-2.
2. Soares SR, Barbosa dos Reis MM, Camargos AF. Diagnostic accuracy of sonohysterography, transvaginal sonography, and hysterosalpingography in patients with uterine cavity diseases. *Fertil Steril* 2000 Feb;73(2):406-11.
3. Kupesic S. Clinical implications of sonographic detection of uterine anomalies for reproductive outcome. *Ultrasound Obstet Gynecol* 2001 Oct;18(4):387-400.
4. Kupesic S, Plavsic BM. 2D and 3D hysterosalpingo-contrast-sonography in the assessment of uterine cavity and tubal patency. *Eur J Obstet Gynecol Reprod Biol* 2007 Jul;133(1):64-9.
5. Ghi T, Casadio P, Kuleva M, Perrone AM, Savelli L, Giunchi S et al. Accuracy of three-dimensional ultrasound in diagnosis and classification of congenital uterine anomalies. *Fertil Steril* 2009 Aug;92(2):808-13.
6. Humer HA, Li TC, Cooke ID. The septate uterus: a review of management and reproductive outcome. *Fertil Steril* 2000 Jan;73(1):1-14.