

Fluoroscopy Guided Transurethral Placement of Ureteral Metallic Stents

Song Myung Gyu,¹ Tae Seok Seo,^{1*} Cheol Min Park,¹ Jae Woong Choi,¹ Jong Mee Lee,¹ and Yang Shin Park¹

¹Department of Radiology, Korea University Guro Hospital, Korea University College of Medicine, Seoul, Korea

*Corresponding author: Tae Seok Seo, Department of Radiology, Korea University Guro Hospital, Korea University College of Medicine, Seoul, Korea. Tel: +82-226261379, E-mail: glqipapa@korea.ac.kr

Received: May 21, 2014; Accepted: June 29, 2014

Ureteral stent exchange is usually performed under both fluoroscopic and cystoscopic guidance. We experienced two cases with retrograde placement of metallic ureteral stent via urethra under fluoroscopic guidance. When patients with double-J ureteral stent (DJUS) have symptom and want to change DJUS to metallic stent, fluoroscopic guided transurethral placement of ureteral metallic stent is a good option as alternative of cystoscopic procedure or percutaneous procedure through percutaneous nephrostomy tract.

Keywords: Fluoroscopy; Ureteral Neoplasms; Stents

1. Introduction

Since Zimskind et al. first suggested bypassing malignant ureteral obstruction using silicone tubing, internal ureteral stents are used to maintain ureteral patency in the management of various benign and malignant forms of ureteral obstruction (1). Today, placement of a double-J ureteral stent (DJUS) is a widely used treatment for palliative decompression by diversion of urine and prevention of uremia in patients with malignant ureteral obstruction. However, DJUS is associated with some adverse effects such as encrustation, stone formation, pain, infection, reflux, bladder irritation and decreased ureteral peristalsis (2, 3). Therefore, these stents have to be exchanged or removed within 4-6 months of placement and often cause significant patient discomfort and decrease quality of life. In an attempt to improve existing DJUS, metallic stents have been considered as an alternative (4, 5).

Ureteral stent exchange is usually performed under both fluoroscopic and cystoscopic guidance. In previous studies, ureteral stent exchange using a snare loop or foreign body forceps has been performed under fluoroscopic guidance (6-8). Herein, we have reported our experiences with retrograde placement of metallic ureteral stent via urethra under fluoroscopic guidance in two patients. This case report was approved by our Institutional Review Board. An informed consent to participate in this study was obtained.

2. Case Presentation

2.1. Case 1

A 56-year-old woman was admitted with left hydrone-

phrosis on computed tomography (CT). She had undergone an operation (total gastrectomy, distal pancreatectomy and splenectomy) for gastric cancer one month ago. The patient had undergone percutaneous nephrostomy (PCN) and placement of DJUS was performed electively via PCN tract after urine was clear. After one month, the patient complained dysuria and frequency and wanted to place metallic ureteral stent instead of DJUS.

Patient was placed in a supine position and povidone-iodine was used locally as aseptic agent. Analgesia (fentanyl citrate) was routinely administered intravenously (IV), immediately before the procedure without conscious sedation. After topical urethral anesthesia with lidocaine gel, insertion of 10F vascular sheath was performed. Under fluoroscopic guidance (Axiom Artis dTA, Siemens, Erlangen, Germany), a snare wire of 25mm-in-diameter (Amplatz GooseNeck® Snare, Covidien, Plymouth, MN, USA) was introduced through the sheath into the bladder lumen. After capture and partial extraction of the previously inserted DJUS (Figure 1 A), insertion of the wire (Radiofocus, Terumo, Tokyo, Japan) through DJUS into left renal pelvis and removal of the DJUS were performed. Tubogram obtained after insertion of the wire showed diffuse stricture of proximal to mid ureter with mild dilatation of pelvicalyceal system of the left kidney. After exchange of wire to stiff one (Radiofocus, Terumo) and dilatation using 6 mm - 10 cm balloon (Mustang Balloon, Boston scientific, Natick, MA, USA) with hand injection pressure, insertion of two 6mm-12cm metallic ureter stents (Uventa, TaeWoong Medical,

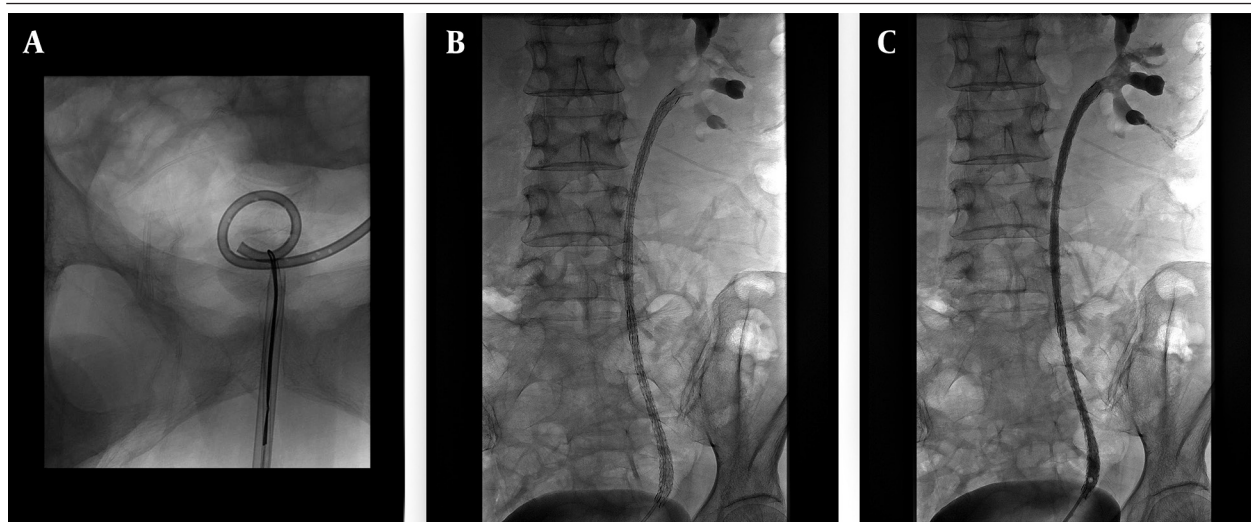


Figure 1. Fifty-six-year-old woman with left DJUS. A, Capture of the previously inserted DJUS as snare wire is seen. B, There are two ureteral stents in left ureter with sparing of distal ureter. C, Tubogram obtained after insertion of ureteral stents shows good passage of contrast media into urinary bladder through partially expanded stent.

Gimpo, Korea) were performed with sparing of distal ureter (Figure 1 B). Final tubogram using 5F Kumpe catheter (Cook, Bloomington, IN, USA) showed good passage of contrast media (Xenetix® 300, Guerbet, Roissy CdG cedex, France) into urinary bladder through partially expanded stent (Figure 1 C). The ureteral stent had been patent for six months and creatinine level remained normal on follow-up.

2.2. Case 2

A 54-year-old woman with gastric cancer was admitted with right hydronephrosis on follow-up CT. The patient had undergone PCN and placement of DJUS was performed. During six months after placement of DJUS, the patient continuously complained dysuria, frequency and discomfort and wanted to place metallic ureteral stent instead of DJUS. We placed 6 mm - 12 cm metallic ureteral stent (Uveta stent) via transurethral route as abovementioned method (Figure 2).

3. Discussion

PCN and DJUS are widely used to treat ureteral obstruction. PCN corrects the symptoms associated with ureteral obstruction. However, it evokes significant discomfort and decreases the quality of life because of the externally placed catheter. Although DJUS is more comfortable for patient than PCN, there are several flaws that prevent its widespread use. First, DJUS should be exchanged or removed periodically. Moreover, complications such as early obstruction, migration and fracture can occur easily after placement (4). Thus, metallic stents have been considered as an alternative. Metallic stent does not need change or removal periodically and decreases symptoms related to DJUS such as pain and urinary symptoms. Therefore, using metallic stent instead of DJUS leads to higher quality of life and longer ureteral patency (5).

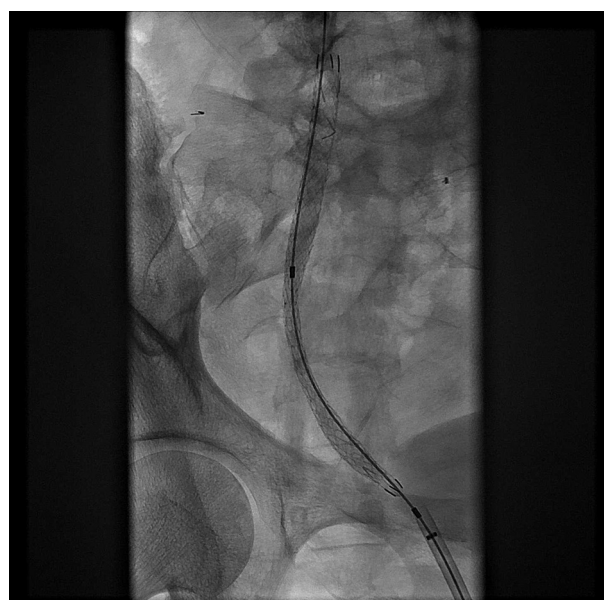


Figure 2. A 54-year-old woman with DJUS. A partially expanded ureteral stent in the right ureter; Guide wire was seen through transurethral route.

Antegrade approaches for removal and exchange of ureteral stents via PCN tract have been described (9). However, these are technically more difficult, are much more painful and psychologically demanding for patients than retrograde approaches, also require placement of a large catheter through a percutaneous tract with all the attendant risks and complications of that procedure (10). Therefore, this procedure was used in limited cases of failure of retrograde transurethral approach.

The standard technique used to exchange a DJUS is performed under cystoscopy (6, 7). However, because of the rigidity and larger diameter of a cystoscope, some patients need deep sedation or general or epidural an-

esthesia for pain management during the procedure (10). Fluoroscopic transurethral exchange of DJUS has been described with various techniques in the literature (6-8, 10). The simple snare technique using a goose-neck snare can be performed easily in most cases. The same as exchange of DJUS, fluoroscopy guided placement of metallic stent by transurethral approach was possible in patients with previously inserted DJUS. As above described cases, exchange of ureteral metallic stent was easy and safe by the same method of DJUS exchange. As compared with antegrade approach, this technique has advantage that there is no need to make a new PCN tract.

Generally, retrograde exchange of ureteral stents under fluoroscopic guidance is safe and easy (6-8, 10). It can be performed under topical anesthesia by radiologists after a short training period and the success rate is high with a low incidence of complications among women (7). However, these cases were female, which could be a weak point. Retrograde approach may be more difficult in men, because men have a longer urethral tract and the possibility of benign prostatic hyperplasia making the advancement of the sheath difficult.

In conclusion, in patients with DJUS and symptoms who want to change DJUS to metallic stent, fluoroscopic guidance of transurethral placement of ureteral metallic stent is a good option instead of cystoscopic procedure or percutaneous procedure through PCN tract.

Authors' Contributions

Study concept and design: Tae Seok Seo. Acquisition of data: Tae Seok Seo and Song Myung Gyu. Analysis and interpretation of data: Song Myung Gyu. Drafting of the manuscript: Song Myung Gyu. Critical revision of

the manuscript for important intellectual content: Tae Seok Seo and Cheol Min Park. Administrative, technical and material supports: Tae Seok Seo. Study supervision: Cheol Min Park, Jae Woong Choi, Jong Mee Lee and Yang Shin Park.

References

1. Zimskind PD, Fetter TR, Wilkerson JL. Clinical use of long-term indwelling silicone rubber ureteral splints inserted cystoscopically. *J Urol*. 1967;**97**(5):840-4.
2. Bultitude MF, Tiptaft RC, Glass JM, Dasgupta P. Management of encrusted ureteral stents impacted in upper tract. *Urology*. 2003;**62**(4):622-6.
3. Borboroglu PG, Kane CJ. Current management of severely encrusted ureteral stents with a large associated stone burden. *J Urol*. 2000;**164**(3 Pt 1):648-50.
4. Chung HH, Kim MD, Won JY, Won JH, Cho SB, Seo TS, et al. Multicenter experience of the newly designed covered metallic ureteral stent for malignant ureteral occlusion: comparison with double J stent insertion. *Cardiovasc Intervent Radiol*. 2014;**37**(2):463-70.
5. Maan Z, Patel D, Moraitis K, El-Husseiny T, Papatsoris AG, Buchholz NP, et al. Comparison of stent-related symptoms between conventional Double-J stents and a new-generation thermoexpandable segmental metallic stent: a validated-questionnaire-based study. *J Endourol*. 2010;**24**(4):589-93.
6. Kawahara T, Ito H, Terao H, Yamashita Y, Tanaka K, Ogawa T, et al. Ureteral stent exchange under fluoroscopic guidance using the crochet hook technique in women. *Urol Int*. 2012;**88**(3):322-5.
7. Chang RS, Liang HL, Huang JS, Wang PC, Chen MC, Lai PH, et al. Fluoroscopic guidance of retrograde exchange of ureteral stents in women. *AJR Am J Roentgenol*. 2008;**190**(6):1665-70.
8. Carrafiello G, Lagana D, Mangini M, Recaldini C, Dizonno M, Giorgianni A, et al. Fluoroscopically guided retrograde replacement of ureteral stents. *Radiol Med*. 2007;**112**(6):821-5.
9. Yeung EY, Carmody E, Thurston W, Ho CS. Percutaneous fluoroscopically guided removal of dysfunctional ureteral stents. *Radiology*. 1994;**190**(1):145-8.
10. Park SW, Cha IH, Hong SJ, Yi JG, Jeon HJ, Park JH, et al. Fluoroscopy-guided transurethral removal and exchange of ureteral stents in female patients: technical notes. *J Vasc Interv Radiol*. 2007;**18**(2):251-6.