

A. Mohammadi MD<sup>1</sup>  
M. Khodabakhsh MD<sup>2</sup>

## Foreign Body: A Sewing Needle Migrating from the Gastrointestinal Tract to the Liver

We report the case of an 18-year-old man with a needle-like foreign body embedded in the liver. The foreign body was found in the RUQ on the plain abdominal x-ray obtained for further evaluation of a previous ingested foreign body. Computed tomography confirmed the diagnosis. The patient was asymptomatic but surgery was performed and the needle was removed. Surgery confirmed the diagnosis.

Keywords: Foreign Body, Gastrointestinal, Liver

### Introduction

Most ingested foreign bodies pass through the gastrointestinal tract without causing complications.<sup>1</sup> Surprisingly, ingested sharp metallic foreign bodies seldom perforate the gut. Patients may present with unrelated symptoms and discovery of the foreign body on radiological examination of the abdomen may come as a surprise.<sup>2</sup>

Due to the intra-peritoneal location of the liver, hepatic foreign bodies are quite rare.<sup>3</sup> Only 32 cases have been reported in the English literature, of which more than 90% were adults.<sup>4</sup> We report this case because of its rarity and importance, as a possible cause of abscess formation, severe complication and also sudden death<sup>1-4</sup> due to foreign body of the liver. We believe that according to the previous reported complications due to ingested foreign bodies, all ingested foreign bodies, which have penetrated into the intestine and migrated to the liver, should be removed as soon as possible.

### Case Presentation

An 18-year-old young man was referred to our center for further evaluation of a previously ingested foreign body (needle) which had not migrated on abdominal x-ray during this 3-month period. Three months ago, the patient inserted a sewing needle into his mouth and suddenly swallowed it. He had been asymptomatic all this time with no obvious symptoms related to this problem such as abdominal pain, fever, jaundice and gastrointestinal bleeding. Physical examination showed no evidence of abdominal tenderness and abdominal mass.

The laboratory data were as follows: white blood cell count,  $5.94 \times 10^3$ ; hemoglobin, 130 g/L; AST, 35 U/L; ALT, 20 U/L; total bilirubin, 1.82  $\mu\text{mol/L}$ .

A foreign body, which appeared to be similar to a needle, was found in the right hypochondrium on plain abdominal x-ray (Fig. 1A).

Computed tomography scan confirmed that the needle was completely buried in the liver (Fig. 1B). The length of the foreign body was 2.7 cm in

1. Assistant Professor, Department of Radiology, Imam Khomeini Hospital, Urmia University of Medical Sciences, Urmia, Iran.

2. Department of Radiology, Imam Khomeini Hospital, Urmia University of Medical Sciences, Urmia, Iran.

Corresponding Author:  
Afshin Mohammadi  
Address: Department of Radiology,  
Imam Khomeini Hospital, Ershad Blvd.,  
Modaress St., Urmia, Iran.  
Tel: +98441-344-7113  
Fax: +98441-346-9935  
Email: mohamadi\_afshin@yahoo.com

Received December 28, 2008;  
Accepted after revision March 4, 2009.

Iran J Radiol 2009;6(4):199-201

computed tomography imaging which was shorter than the true length (3.3 cm). We investigated the patient with IV contrast CT scan (100cc Ultravist, 300mg/dl; 5mm slice thickness) for further evaluation of suspected liver parenchymal pathology such as granuloma or abscess formation. The Hounsfield Unit (HUF) of the needle-like foreign body was 530.

At laparotomy, the needle was removed after the position of the needle was confirmed by palpation. There was no suspected site of intestinal perforation at laparotomy, which may be due to an old fine perforation that had healed without scarring. The foreign body was a needle 3.3 cm in length (Fig. 1C).

The postoperative course was uneventful and the patient was discharged without any complication. The patient's general condition is good at present. There has been no complication in the 6-month period after surgery.

## Discussion

Most ingested foreign bodies pass through the gastrointestinal tract uneventfully within one week.<sup>4</sup>

There have been 32 reported cases of hepatic foreign bodies in the literature.<sup>4</sup>

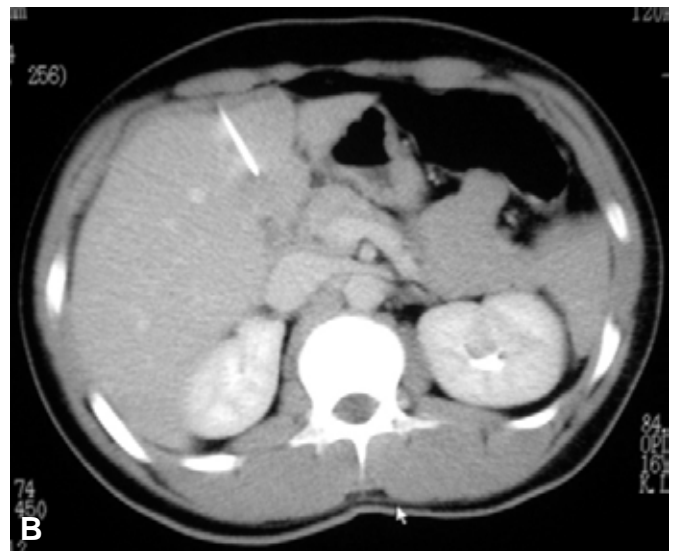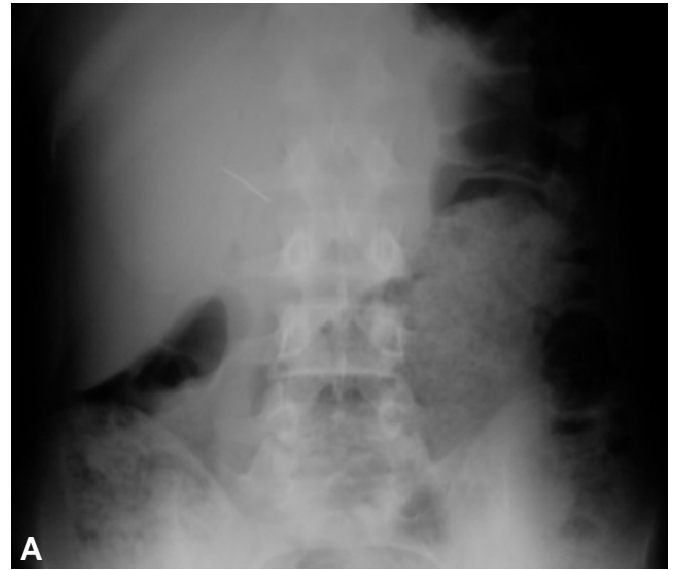
A fish bone (10 cases), a sewing needle (eight cases), a toothpick (six cases), a hairpin, a round air-rifle bullet, a pen, a pin, and a dental plate and an unknown object<sup>3-6</sup> have been the foreign bodies which have been found in the patients.

The most common sites of intestinal foreign body perforation are the ileo-cecal junction and the recto-sigmoid region. The foreign body migration to the liver and abscess formation are indeed rare with less than 20 cases reported in the world literature.<sup>7</sup>

Most patients with hepatic foreign bodies have no symptoms at first; symptoms such as abdominal pain, fever, and liver dysfunction are present in only a small number of patients. Our patient had no sign or symptom related to ingested foreign body just like the previous cases reported in the literature. There was no finding related to occult hepatic abscess in the abdominal x-ray or CT scan of this patient.

In general, patients with hepatic foreign bodies have been treated surgically.

Computed tomography scans are essential in making an accurate localization of foreign bodies. In our



**Fig. 1.** An 18-year-old man with an ingested foreign body.

**A.** Plain abdominal x-ray shows a needle-like object (arrow) in the RUQ.

**B.** Axial computed tomography shows the needle (arrow) inserted in the left lobe of the liver.

**C.** Photograph showing the sewing needle removed from the liver (3.3 cm in length).

patient, CT confirmed the diagnosis, similar to most previous studies.<sup>2-6</sup> The length of the needle in the CT image was shorter than the surgically removed needle (3.3 cm versus 2.7 cm); we think it is due to the oblique orientation of the needle in the computed tomography slice.

In one reported case of unexpected death, the cause discovered on autopsy was a migratory foreign body (portion of chicken fibula) and the prolonged course of illness, together with relatively non specific symptoms and signs, resulted in establishment of diagnosis only at autopsy.<sup>8</sup>

In conclusion, in the follow-up of ingestion of a sewing needle or a similar sharp object, we should bear in mind the possibility of penetration of the foreign body to contiguous organs; maybe revision of

the follow-up protocol should be considered.

## References

1. John KD, Segal I, Saadia R. Perforation of gastro-intestinal tract by a foreign body. A case report. *S Afr J Surg* 1996;34(2):78-80.
2. Harjai MM, Gill M, Singh Y, Sharma A. Intra-abdominal needles: an enigma (a report of two cases). *Int Surg* 2000;85(2):130-2.
3. Lotfi M. Foreign body in the liver. *Int Surg* 1976;61:228.
4. Crankson SJ. Hepatic foreign body in a child. *Pediatr Surg Int* 1997;12:426-7.
5. Ward A, Ribchester J. Migration into the liver by ingested foreign body. *Br J Clin Pract* 1978;32:263.
6. Omejc M. Laparoscopic removal of an ingested pin migrating into the liver. *Surg Endosc* 2002;16(3):537.
7. Kumar S, Gupta NM. Foreign bodies migrating from gut to liver. *Indian J Gastroenterol* 2000;19(1):42.
8. De la Vega M, Rivero JC, Ruiz L, Suarez S. A fish bone in the liver. *Lancet* 2001;358:982.