

A. Alamdaran MD¹
H.R Kianifar MD²
A. Adelkhah MD³

Diagnosis of Colorectal Polyps by Hydrocolonic Sonography in Children with Rectal Bleeding

Background/objective: Because of the inherent danger and associated discomfort of invasive procedures such as colonoscopy or double contrast barium enema involving exposure to radiation, we studied the value of hydrocolonic sonography in the diagnosis of colorectal polyps in children with rectal bleeding.

Patients and Methods: From March 2005 to January 2006, 46 children from 2.5-11 years of age presented with hematochezia were examined by means of hydrocolonic sonography and colonoscopy.

Results: On colonoscopy, 21 patients had normal results, 19 had polyps, 3 had proctitis, 2 had lymphonodular hyperplasia and 1 had anal fissure. Only 7 of 19 colorectal polyps were diagnosed by conventional abdominal sonography (37%), whereas hydrocolonic sonography permitted the diagnosis of 17 (89.5%) with a specificity equal to 92.5%. In comparison with colonoscopy, positive predictive value of hydrocolonic sonography was 89.4% and negative predictive value was 92.5%.

Conclusion: Hydrocolonic sonography is a accurate and safe approach to evaluating children with rectal bleeding. Thus, it can be regarded as an appropriate replacement of barium enema.

Keywords: child, gastrointestinal tract, colonic polyps, ultrasonography

Introduction

Rectal bleeding is a relatively common occurrence in the children. Colitis and juvenile polyposis (JP) are frequent causes of lower gastrointestinal bleeding in this group age.¹ Sonography has become increasingly important in the diagnosis of diseases of the gastrointestinal tract.² It may be used as the first diagnostic procedure in the evaluation of patients with abdominal complaint.³

The technical and scientific development of sonography with high-frequency transducers has made it possible to detect the intestinal lesions.⁴

In rectal bleeding, the diagnostic value of conventional transabdominal sonography is limited. The sonographic evaluation of the colon could be improved by the retrograde instillation of water into the colon in a procedure called hydrocolonic sonography. This technique enables a detailed sonographic examination of the colon. Thus, providing additional information and allowing a more precise diagnosis of many diseases of the colon.²

Only few studies so far have stressed the value of this diagnostic method in the diagnosis of causes of rectal bleeding, especially colorectal polyps in children. Walter et al in 1992 described a juvenile polyp detected on sonography in a child examined after instillation of water in the colon. Nagita et al in 1994, after colonic preparation, sonographically examined 39 children suspected of having intestinal polyps and reported good sensitivity for juvenile polyp detection.⁵ Baldisserotto et al (2002) reported seven cases of juvenile polyps detected by graded compression gray-scale.²

1. Assistant Professor, Department of Radiology, Doctor Sheikh Children Hospital, Mashhad University of Medical Sciences, Mashhad, Iran.

2. Assistant Professor, Department of Pediatrics, Doctor Sheikh Children Hospital, Mashhad University of Medical Science, Mashhad, Iran.

3. Department of Radiology, Doctor Sheikh Children Hospital, Mashhad University of Medical Science, Mashhad, Iran.

Corresponding author:

Ali Alamdaran

Address: Department of Radiology, Doctor Sheikh Children Hospital, Mashhad, Iran.

Tel: 0098-5117283033

Fax: 0098-5118417451

Email: SA_Alamdaran@mums.ac.ir

Received February 20, 2006;

Accepted after revision Jun 18, 2006.

Summer 2006; 4:235-239

Because of the inherent danger and associated discomfort of invasive procedures such as colonoscopy or double contrast barium enema involving exposure to radiation, we studied the value of hydrocolonic sonography in the diagnosis of colorectal polyps in children with rectal bleeding.⁶

Patients and Methods

From March 2005 to January 2006 in a prospective studying in Dr. Sheikh Children hospital, Mashhad, 46 consecutive patients (aged 2.5 to 11 years) who were referred for rectosigmoidoscopy or colonoscopy and suspicious for colorectal polyps because of lower gastrointestinal bleeding underwent conventional abdominal and pelvic sonography especially intestinal examination and hydrocolonic sonography before colonoscopy. All patients had a history of lower gastrointestinal bleeding and/or abdominal pain and the first suspected clinical diagnosis was colorectal polyps. Patients with abnormal coagulation tests and ill condition were excluded. The ethics committee of Mashhad faculty of medical sciences approved this study. All parents gave informed consent.

On the day before the examinations, oral intake was limited to clear liquids, and each patient began to use laxatives drugs (bisacodyl suppository and/or castor oil). Initially in supine position, 200 to 300 ml of warm water was instilled transrectally via a no.16 rectal tube to fill the rectosigmoid. After meticulous examination of this area, some more water (500-1000 ml) was instilled into descending, transverse, and ascending colon. Patients were turned to the right and left to fill the colon with water and reduce the shadowing effects of air in the lumen and differentiation of stool particles from polyp with their removal from the wall after patients turn. Attempts to move adherent stool fragments by instilling more water, by applying pressure with the ultrasound transducer, and or by changing the patient's position were often successful. At the time of instillation, sonography was performed in two transverse and longitudinal planes with 5, 7 or 10 MHZ transducers with a siemens unit (Sonoline Adara) and sonographic finding was recorded. After water defecation, colonoscopy was performed. A radiologist experienced in pediatric radiology performed the sonographic examinations. The

gastroenterologist performing colonoscopy was aware to the ultrasound results, because colonoscopy is considered as a gold standard test and all of sonographic results are compared with it.

Variables included age, sex, symptom duration, and presence of mucus, history of hard stools, bleeding type, size and location of colorectal polyps, and preparation status and colonoscopic results. Hydrocolonic sonographic evaluation was classified as true negative, true positive, false negative, or false positive for colorectal polyps according to colonoscopic report. After data coding, statistical analysis of nominal variables were performed using the chi-square test and t-test by SPSS® 11.5 software. A two-sided P value of <0.05 was considered significant.

Results

Forty-six children, (30 male and 16 female; average age, 5.3±2.57 years) were examined. They often suffered from hematochezia during or after defecation. Mean time of the duration of symptoms was about 10.61±12.84 months (from 0.25 to 72 months).

Colonoscopic diagnosis revealed normal appearance in 21 patients, polyps in 19, proctitis in 3, lymphonodular hyperplasia in 2 and anal fissure in 1. Except in one patient with two small polyps, the other polyps were solitary and 84% of them were pedunculated. Maximal diameter of polyps ranged from 9 mm to 35 mm (mean=18.5 mm). Two patients had polyps equal or less than 7 mm in diameter and 17 had polyps 9 mm or more in diameter. Polyps were located in the descending colon in 4 (21%) cases, the sigmoid colon in 8 (42%), and the rectum in 7 (37%). Mean distance from anal margin was 12.3 cm. Eighty four percent of polyps were in the first 20 cm of anal margin which was available in rectosigmoidoscopy.

About one third (7 of 19) of colorectal polyps were diagnosed by conventional abdominal sonography (Figure 1), whereas hydrocolonic sonography permitted the diagnosis of 17 (89.5%) cases. In conventional sonography, polyps larger than 12 mm were often detected, whereas smaller polyps were missed. Type, size, location and distance from anal margin of colorectal polyps were similar in colonoscopy and hydrocolonic sonography. In two patients, three small sessile polyps less than 0.7 cm in diameter at the rectum

had been missed. Hydrocolonic sonography also was non diagnostic in two cases and it was not possible to differentiate adherent fecal material from colorectal lesion. There was two false positive too. Hydrocolonic sonography couldn't diagnose proctitis and lymphonodular hyperplasia.

According to table 1, the sensitivity of the technique in the detection of colorectal polyps was 89.5% (17 of 19) and the specificity was 92.6% (25 of 27). Colorectal polyps larger than 9 mm diameter could be identified in 100% of cases. Positive predictive value of hydrocolonic sonography was 89.5% (17 of 19) and negative predictive value was 92.6% (25 of 27) in comparison with colonoscopy.

The polyps were hyperechoic spherical or ovoid masses fixed to the colonic wall. Cysts with diameters of 2-3 mm were visualized in the polyps and pedicles having visible feeding vessel extending to the colon wall could be identified as a hypoechoic tubular shadow (Figure 2).

There was mucus in fecal material in 37% (17 of 46) of patients and there was a significant correlation between presence of mucus and polyps ($p=0.014$). Our results show that type of bleeding (during and after defecation), history of constipation or hard defecation, sex, patient age, and the duration of symptoms do not seem to be helpful in the diagnosis of colorectal polyps ($p<0.05$).

In spite of using a standard preparation for all patients, 72% cases had stool particles in colon especially in cecum and it was excessive in 20% of patients especially in ascending colon. Stools appeared as mobile or adhering to the colonic wall, hyperechoic reflections in an ultrasound examination and sometime it was difficult to differentiate them from colonic lesions.

Except transient vomiting in two patients, no adverse reactions were noted in any child during or after the hydrocolonic sonography. There were no

complications of colonoscopy.

All patients underwent polypectomy. In one patient, colonic polyp that could not be resected through the colonoscopy was removed surgically and the other polyps were removed endoscopically.

Discussion

Hydrocolonic sonography is a simple, relatively non-invasive procedure that enables a detailed examination of the colonic lumen and its lesions.⁷ Although Chui et al, (1995) stated that hydrocolonic sonography has a limited value for identifying colorectal polyps, Limberg B (1992), Kellner H et al (1995) and Elewaut AE et al (1995) described its high diagnostic value in detection of colonic polyps and tumors.^{2,8-10} Hirooka et al described the value of Sono-Enterocolonography intestinal examination technique using per oral administration of water with D-sorbitol in the diagnosis of intestinal disease, especially in elevated polypoid lesions, but the most limitation of this method is its poor visualization of rectosigmoid area. Thus, they said that it seems unlikely that it would replace barium enema wholly.¹¹

In spite of the Limberg experience in adults, our results and the results of Baldisserotto et al show that relatively high percent of pediatric colonic polyps can be detected by conventional abdominal sonography.^{2,4} In our study as well as other researchs in children and adults, hydrocolonic sonography has had high predictive values and a high sensitivity and specificity rate of about 90%.^{2,8} Cervantes et al showed that the diagnostic efficacy of barium enema in colorectal polyp is lower (about 74%).³

The clinical findings, the number of polyps, the site of colorectal polyps, the mean duration of symptoms, and the mean distance from anal margin in this study are near or the same as other studies.¹²⁻¹⁴ In the two patients whose polyps were not detected in hydrocolonic sonography, there were small rectal (5 and 7 mm) polyps at colonoscopy. Limberg and Elewaut et al reported that most undetected cases were also smaller than 7 mm.^{2,6,10} In addition, the rectum is a potentially difficult colon segment to be evaluated sonographically. The rectum is located deep in the pelvic cavity so compressive maneuvers and the use of high-frequency transducers are difficult (Figure 3).

Table 1. Agreement of results of colonoscopy and hydrocolonic sonography in diagnosis of colorectal polyps

	Colonoscopy		Total	
	no polyp	polyp		
Hydrocolonic	no polyp	25	2	27
Sonography	polyp	2	17	19
Total		27	19	46

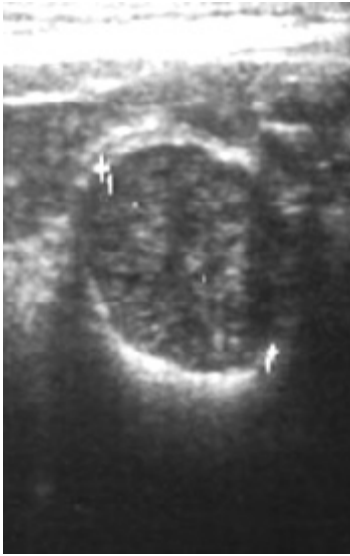


Fig 1. Colonic polyp appearance in conventional sonography

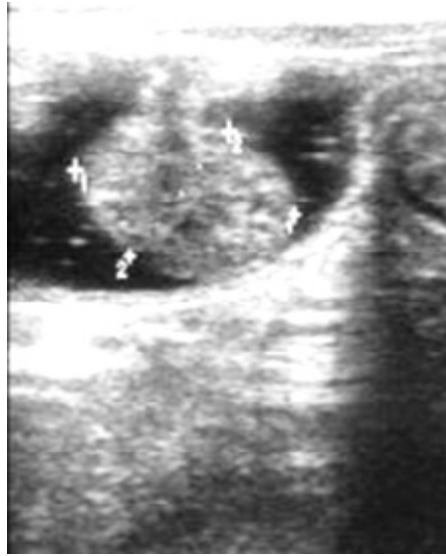

Fig 2. Pedunculated polyp in hydrocolonic sonography

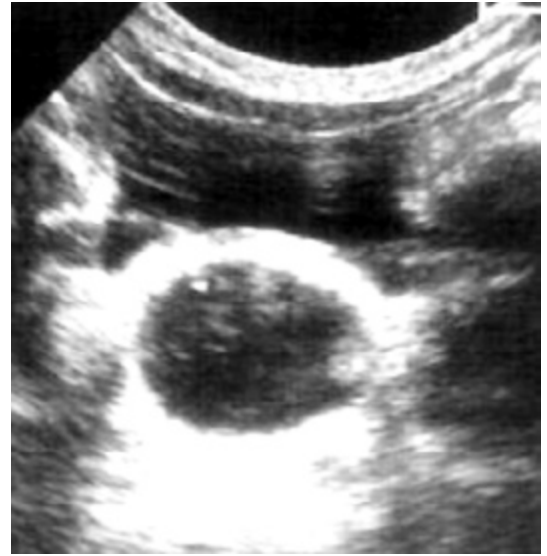

Fig 3. Small sessile polyp in left lateral wall of rectum

Thus, polyps in this segment may be overlooked.⁴

Other areas with poor visualization in some patients are the hepatic and splenic flexures and transverse colon, respectively due to subcostal anatomic location and air existence in transverse colon due to its relatively higher location in the abdomen.⁴ Other limitations of this method are adherent stools or thickened and asymmetric haustrations that is difficult to differentiate from colonic lesions. They cause false positive result, discomfort or the inability to retain water, dependent upon the experience of the examiner and the quality of the scanner.⁸ Although stool fragments attached to the bowel wall could be distinguished from polyps by confirming their removal from the wall after letting patients turn, in Chiu et al and our studies, hydrocolonic sonography is not diagnostic in some patients and it is not possible to differentiate adherent fecal material from colonic lesion.¹¹

In spite of these limitations, hydrocolonic sonography has many advantages in comparison with double contrast barium that makes it an appropriate diagnostic procedure and complementary to colonoscopy in the management of rectal bleeding in children. Advantages of this method include: absence of radiation exposure, a more precise diagnosis of diseases, the possibility to differentiate colorectal polyps from fecal materials or other lesions, solution of number of fundamental problems facing prior to polypectomy such as possible polyp malignancy and size of polyp that determines a appropriate treatment such as sig-

moidoscopy, colonoscopy or surgery, significant time saving in colonoscopy time and high detectability rate.^{10,13,14} The relatively small number of patients within any category is the limitation of this study that should be taken into account and warrants the need for further larger studies.

The radiation-free examination of the whole colon, safety and high diagnostic efficacy of hydrocolonic sonography show that this diagnostic method could be regarded as an appropriate replacement for barium enema as a troublesome procedure.

Acknowledgement

We thank Dr Hiradfar and radiology technologists' department of Mashhad Dr. Sheikh Children hospital for their assistance in this study.

References

1. Seibert JJ. The child with bloody stools in: Waldendurg Hiton S, Edwards DK. Practical pediatric radiology. 2nd ed. WB Sanders; 1994: 187-189
2. Limberg B. Diagnosis and staging of colonic tumors by conventional abdominal sonography as compared with hydrocolonic sonography. N Engl J Med 1992; 327: 65-69
3. Cervantes-Bustamante R, Ramirez-Mayans J, Mata-Rivera N, Zarate-Mondragon F, Munquina-Vanegas P, Soria-Garibay B et al. Juvenile polyposis in Mexican children. Rev Gastroenterol Mex 2002; 67: 150-154
4. Baldisserotto M, Spolidoro JV, Bahu Mda G. Graded compression sonography of the colon in the diagnosis of polyps in pediatric patients. Am J Roentgenol 2002; 179: 201-205

5. Nagita A, Amemoto K, Yoden A, Yamazaki T, Mino M, Miyoshi H et al. Ultrasonographic diagnosis of juvenile colonic polyps. *J Pediatr* 1994; 124: 535-540
6. Limberg B. Hydrocolonic Ultrasonography. *N Engl J Med* 1995; 332 : 1581-1582
7. Ling UP, Chen JY, Hwang CJ, Lin CK, Chang MH . Hydrosonography in the evaluation of colorectal polyps. *Arch Dis Child* 1995; 73: 70-73
8. Chui DW, Gooding GA, McQuaid KR, Griswold V, Grendell H. Hydrocolonic ultrasonography in the detection of colonic polyps and tumors. *N Engl J Med* 1994; 331: 1685-1688
9. Kellner H, Zoller WG. Diagnosis of colonic polyps and tumors by hydrosonography, *Z Gastroenterol* 1995; 33: 632
10. Elewaut AE, Afschrift M. Hydrocolonic sonography: a novel screening method for the detection of colon disease? *Bildgebung* 1995; 62: 230-234
11. Hirooka N, Ohno T, Misonoo M, Kobayashi C, Mori H et al. Sonoenterocolonography by oral water administration. *J Clin Ultrasound*. 1989; 17: 585-589
12. Waitayakul S, Singhavejsakul J, Ukarapol N. Clinical characteristics of colorectal polyp in Thai children: a retrospective study. *J Med Assoc Thai* 2004; 87: 41-46
13. Nagasaki A, Yamanaka K, Toyohara T, Ohgami H, Aoki T, Sueishi K. Management of colorectal polyps in children, *Acta Paediatr Jpn*. 1993; 35: 32-35
14. Uchiyama M, Iwafuchi M, Yagi M, Iinuma Y, Kanada S, Ohtaki M et al. Fiberoptic colonoscopic polypectomy in childhood: report and review of cases. *Pediatr Int* 2001; 43: 259-262

