

J. Najafi MD¹
 F. Abdolazzedeh Lahiji MD²
 Sh. Bagheri MD³

The Diagnostic Value of Sonography in Bucket Handle Tear of Meniscus and Complete MCL Tear Compared with Arthroscopy

Background/Objective: The concept of evaluating the musculoskeletal system with ultrasound was initially introduced in the late 1970s. For evaluating meniscal tears, which are a common injury in traumatic events of knee, linear probes with high resolution have been used. In this study, we compared the results of sonography with arthroscopy in diagnosing bucket handle tear of meniscus and MCL tear.

Patients and Methods: 218 clinically symptomatic knee joints with clinical indication of arthroscopy were examined by sonography in a referral sport medicine center. The patients eventually had arthroscopic exam. The results were compared, and statistically analyzed using Fisher's exact.

Results: In this study, of 218 patient who had arthroscopy and sonography, the sensitivity and specificity of sonography in meniscal tear were 68.1% and 100%, respectively. 34 patients had bucket handle tear of the posterior horn of the medial meniscus on sonography; six cases (17.6%) of which had abnormally small posterior horns of medial meniscus (in favor of meniscal tear) but in 60 patients with other types of meniscal tear, sonography revealed tear in 58 (96.6%)($P < 0.0001$). Six patients had complete MCL tear in arthroscopy, while in sonography 4 complete MCL tears were shown. Sensitivity of ultrasound in diagnosing complete MCL tear was 66.6% and specificity of 98%.

Conclusion: Ultrasound is easily applicable in evaluation of knee derangement; however, for bucket handle tears it has limited application. For MCL tears, sonography seems an accurate method. Ultrasonography is rapid, low-cost and non-invasive examination.

Keywords: ultrasonography, arthroscopy, bucket handle tear, meniscus, medial collateral ligament, knee joint

1. Assistant professor, Department of Radiology, Shaheed Modares Hospital, Shaheed Beheshti Medical Science University, Tehran, Iran.

2. Assistant professor, Department of Orthopedic surgery, Shaheed Modares Hospital, Shaheed Beheshti Medical Science University, Tehran, Iran.

3. Assistant professor, Department of Orthopedic surgery, Shaheed Modares Hospital, Shaheed Beheshti Medical Science University, Tehran, Iran.

Corresponding Author:

Jila Najafi

Address: Department of Radiology, Shaheed Modares Hospital, Shaheed Beheshti Medical Science University, Tehran, Iran.

Tel: 009821-22074090

Fax: 009821-22074101

Email: Jilanajafi@hotmail.com

Received September 1, 2005;

Accepted after revision January 10, 2006.

Winter 2006; 3: 103-106

Introduction

Ultrasonography is a feasible, inexpensive and accurate method for evaluating musculoskeletal injuries, which can be used as the first complementary diagnostic method. US is more sensitive than radiography when evaluating cartilage damage.¹

The most common causes of knee pain and disability are tears in medial or lateral menisci.^{2,3,4} Meniscal injuries are common in both elite athletes and the general population. In young patients with reflectory muscle spasm and those with acute trauma of the knee joint, clinical examination of the meniscal structures show poor results.⁵ Clinical examination still plays an important role in diagnosing meniscal tears, but the knee joint nerving is responsible for nonspecific pain, which often has too little specificity for meniscal tear.

Thus, accurate diagnosis depends upon imaging. Knee arthrography, which was once used widely, has been largely replaced by MR imaging.^{6,7} Although ultrasonography has been used to evaluate the musculoskeletal system for approximately 25 years, there has been a renewed interest in its application for several reasons. First and foremost, advances in technology

have dramatically improved the image quality.⁸ For example, commercially available transducers at frequencies of 9-13 MHz produce in-plane resolutions of 200-450 μ m and section thickness of 0.5-1 mm.⁹ The spatial resolution of sonography exceeds that of MR imaging without the use of small surface coils and specific imaging parameters.¹⁰ The resolution of ultrasound with standard high-frequency transducers allows visualization of individual neuronal fascicles.¹¹ Another reason for the increased interest in musculoskeletal sonography is that sonography can produce similar results when a focused evaluation is needed, and frequently it can be performed at less cost and with less delay.^{12,13}

In different studies, the sensitivity of 2D sonography in diagnosing meniscal tears proved to be between 71 to 92% for the medial meniscus and 41 to 88% for the lateral meniscus.¹⁴ To our knowledge, all the previous studies had used linear probes.¹⁴⁻²³

Patients and Methods

In a referral sport medicine center, 218 knee joints with clinical indication of arthroscopy were examined by ultrasound. The majority of patients had history of knee trauma and locking. As patients were arthroscopy candidates, no other imaging was requested. The sonographic exam was performed in the prone position, with full extension of the knee, by 6.5 MHz microconvex and 7.5 MHz linear probes and from the medial aspect of the knee with a 7.5 MHz linear probe (Dynamic Imaging Unit, UK). The length

of scanheads was 4 and 7 cm for microconvex and linear probes, respectively.

The ultrasonographic study started from the midline with the probe smoothly moved towards medial and lateral aspects of the popliteal fossa by both probes. The medial side of the knee was examined with a 7.5 MHz linear probe in sagittal and transverse planes.

The triangular hyperechoic posterior horn of menisci was checked.

MCL with hyperechoic longitudinal fibers was considered intact, while a hypoechoic transverse area along its length was considered complete MCL tear. Posterior horns of both menisci and MCL were examined. The exam took about 20 minutes for each knee.

Ultrasonographic exam was performed by a trained musculoskeletal radiologist. Arthroscopy was performed with a Scolap arthroscopic unit (using 30-degree lens). All arthroscopies were performed by one expert surgeon. The results of sonography were compared with arthroscopy using the chi-square test.

Results

There were 124 intact menisci, all of which were ultrasonographically diagnosed as normal. There were 94 torn menisci in arthrography, of which 64 were detected by ultrasound (table 1).

Thus, for diagnosing medial meniscus tears, ultrasound had a sensitivity of 68.1%, specificity of 100%, positive predictive value of 100% and negative predictive value of 80.5%. Efficiency of sonography in

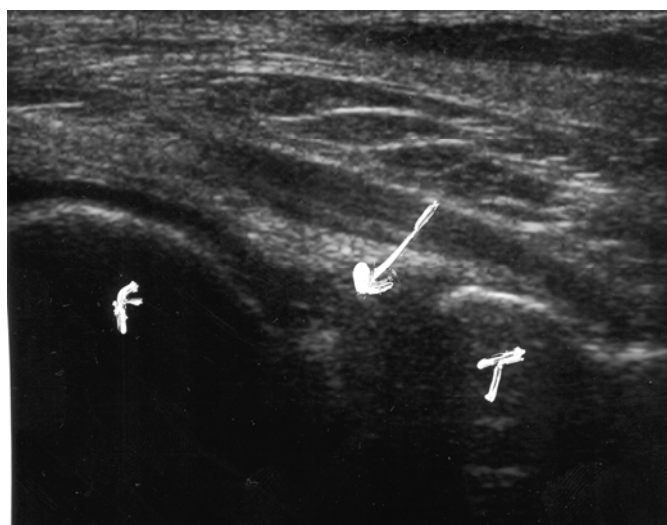


Fig 1. Posterior horn of medial meniscus is seen as triangular hyperechoic structure (arrow) femoral condyle (F) and tibia (T)..

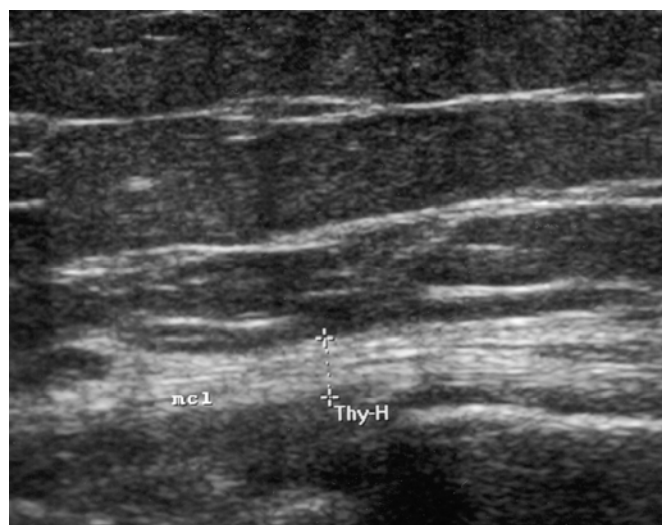


Fig 2. MCL is seen as hyperechoic longitudinal structure (arrow).

Table 1. The results of arthroscopy and sonography in all patients

	Sonography	Positive	Negative	Total
Arthroscopy				
Positive		64	30	94
Negative		0	124	124
Total		64	154	218

diagnosing medial meniscus tears was 86.2%.

Of 218 patients who had arthroscopy, 34 (male, athletes) (15%) had bucket handle tear of the posterior horn of medial meniscus, and we had 60 cases of other types of meniscal tear. Of all cases of bucket handle tear in arthroscopy (34 cases), six patients had signs of tear in the posterior horn of medial meniscus on sonography; thus, 28 (82.4%) of them were missed on sonography. However, missed on versus there was of all cases of non-bucket handle meniscal tear, only 2 cases were sonography (3.3%). The difference between the missing rates of meniscal tear in the two groups (bucket handle versus non-bucket handle tear) were statistically significant ($P < 0.0001$).

(In all patients, no limitation of the penetration of sound beam into the posterior horns of both menisci).

Six patients had complete MCL tear, of which, 4 patients had MCL tear on sonography (Table 2).

Table 2. Results of arthroscopy compared with sonography in MCL tear

	Sonography	Positive	Negative	Total
Arthroscopy				
Positive		4	2	6
Negative		4	208	212
Total				218

Ultrasound had 66% sensitivity for diagnosing complete MCL tear, 50% specificity, was positive predictive value, and 99% negative predictive value. Efficiency of sonography for diagnosing MCL complete tear was 97.2%.

Discussion

Recently, ultrasonography is largely used in musculoskeletal imaging due to advances in technology that have improved image resolution, allowing accurate delineation of anatomic structures and pathologic conditions, its use in meniscal tears is controversial. Recent trends towards cost reduction have made ultrasonography an attractive alternative to more ex-

pensive imaging methods, such as MR imaging.²⁴ Besides, in patients having a contraindication to MR imaging, such as cardiac pacers, cerebral clips, orbital metallic foreign bodies or non-titanium metallic prostheses, ultrasonography could be the best imaging modality. Sonography is also easily applicable in very heavy patients who cannot be examined by MRI.

Since 1988, ultrasonographic examination of meniscal structures of the knee joint has become a standard technique at St Josef Hospital in Bochum, Germany. According to their publications, the sensitivity of sonography of the medial meniscus using linear probes is 81%, and for the lateral meniscus it is 41%.²⁵

Ultrasound is also being increasingly employed in the United States.²⁶ Riedel et al. showed 92% sensitivity and 83% specificity for 2D sonography while the values were respectively 100% to 88% for 3D sonography. In their study positive of ultrasound in diagnosing meniscal tear, predictive values were 58%, and 67% for 2D and 3D ultrasound; negative predictive values were 98% and 100% for 2D and 3D sonography, respectively. These results are compatible with our study's results.²⁴ In another study carried on by Krifka in Bochum, 1186 menisci were examined by ultrasound. Their study showed 83% and 58% sensitivity for medial and lateral meniscus respectively, while the specificity was 90% and 98% for medial and lateral menisci.²⁷

Sensitivity of clinical examination for medial meniscal tear is 81% and for lateral meniscal tear is 47%.²⁸ Since clinical examination does not pinpoint the etiology of the anterior knee pain, an imaging modality will aid the diagnosis.

As it was shown, in the current study, sensitivity and negative predictive value of sonography were lower than many other studies; in fact 30 cases with proven meniscal tear were normal on sonography (28 of which had bucket handle type meniscal tear). Generally, similar to results of this study, bucket handle tears are more likely to be missed in sonographic evaluation in comparison to non-bucket handle tears. These tears occur mainly in certain groups, such as athletes, who have forceful and complex movements at their knee joints.

Because this study was done in a sports clinic, most of our patients were athletes and the frequency of bucket handle tears was higher in comparison to

other studies on patients of general orthopedic clinics. As these tears are more likely to be missed than other types of tear, we can conclude that the lower sensitivity and negative predictive value in our study are due to the higher percentage of athletes in the study sample that had more bucket handle tears in their knees.

The small sample size of the group of complete MCL tear was a problem, so that we cannot generalize the results of this study as a reliable index of diagnostic value of sonography in complete MCL tears.

Therefore, as a supplement to clinical findings, sonographic examination of the meniscus is a feasible, noninvasive, and time and cost saving imaging technique that can be used to optimize pre-operative diagnosis and show the indication for arthroscopy.²⁹ It should be noticed that in certain groups such as athlete with a high probability of bucket handle tears, sensitivity of test is relatively lower than other types of meniscal tear and in these patients, negative results of sonography should be carefully evaluated with other diagnostic tools. Although sensitivity of US for bucket handle tear is not high, regarding the easy application of US and high accuracy rate of diagnosing other types of meniscal tears it could be used as the primary imaging for knee pain; however, for diagnosing bucket handle tears MRI is still required.³⁰

Careful consideration of the technical requirements and systemic performance of the dynamic examination should lead to further improvement of the examination results even in bucket handle tears and to growing clinical significance in the future.³¹

References

- Buchman R, Fjaramillo Diego. Imaging of articular disorders in children. *Radiol clin NAM*. 2004; 42: 151-168.
- Crues JV III, Mink J, Levy TL, Lotysch M, Stoller DW. Meniscal tears of the knee: accuracy of MR imaging. *Radiology*. 1987; 164: 445-448.
- Dehaven KE, Amoczky SP. Meniscal repair. Part I. Basic science, indications for repair and open repair. *Bone Joint Surg Br*. 1979; 61 B: 443-444.
- Mancol LG, Berlow ME. Meniscal tears: comparison of arthrography, CT and MRI. *Crit Rev Diagn Imag*. 1989; 29: 151-179.
- Grifka J, Richter J, Gumatau M. Clinical and Sonographic meniscus diagnosis. *Ortopade*. 1994; 23: 102-111.
- Ireland J, Trickey EL, Stoker DJ. Arthroscopy and arthrography of the knee: a critical review. *J Bone Joint Surg*. 1980; 62: 3-6.
- Gray D, Caplan A, Dussault R. Imaging of the knee: current status. *Orthop Clin of North Am*. 1997; 28: 643-683.
- Mayer V. Ultrasound of the rotator cuff. *J. Ultrasound Med*. 1985; 4: 608-610.
- Erickson SJ. High-resolution imaging of musculoskeletal system. *Radiology*. 1997; 20: 593-618.
- Silvestri E, Martinoli C, Derchi LE, Bertolotto M, Chaisamondia M, Rosenberg I. Echotexture of peripheral nerves: correlation between US and histologic findings and criteria to differentiate tendons. *Radiology*. 1995; 197: 291-296.
- Jacobson JA. Musculoskeletal sonography and MR imaging: A role of both imaging methods. *Radial Clin North Am*. 1999; 37: 713-735.
- Teitz CC. Ultrasonography in the knee. *Radiol Clin North Am*. 1988; 26: 55-62.
- Jacobson J.A, Van Holsbeeck M.T, Musculoskeletal ultrasonography. *Orthop Clin North Am*. 1998; 29: 135-167.
- Reidel S, Tauscher A, Kuhner C, Gohring U, Sohn C, Meeder PJ. 3-D Ultrasound in clinical diagnosis of meniscus lesions. *Ultraschall Med*. 1998; 19: 28-33.
- Reidel S, Tauscher A, Kuhner C, Gohring U, Sohn C, Meeder PJ. 3-D sonography in the diagnosis of meniscal lesions. *Chirurg*. 1997; 68: 1150-1155.
- Reidel S, Kuhner C, Tauscher A, Gohring U, Sohn C, Meeder PJ. Experimental study of meniscus lesions. *Ultraschall Med*. 1996; 17: 247-252.
- Holzach P, Mattli J, Benz K, Streicher U, Matter P. Ultrasonography of meniscus lesions. *Sportverletz Sportaschaden*. 1990; 4: 135-138.
- Taubert K, Reimer P, Hendrickx P, Lobenhoffer P. Experimental meniscus sonography: the influence of imaging geometry on the visualization of meniscal lesions. *Rofo Fortscher Geb Rontgenstr Neuen Bildgeb Verfahr*. 1990; 153: 120-123.
- Harcke HT, Grisson LE, Finklestein MS. Evaluation of Musculoskeletal system with Sonography. *Am J Roentgenol* 1988; 150: 1253-1261
- Fusting M, Casser HR. Dynamic examination technique in meniscus sonography. *Sportverletz Sportschanden*. 1991; 5: 27-36.
- Selby B, Richardson ML, Montana MA, Teitz CC, Larson RV, Mack LA. High-resolution sonography of the menisci of the knee. *Invest Radiol* 1986; 21: 332-235.
- Verdonk P, Depaape Y, Desmyter S, De Muynck M, Almqvist KF, Verstrate Ket al. Normal and transplanted lateral meniscus :evaluation of extrusion using MRI & ultrasonography. *Knee Surg Sports Traumatol Arthrosc*. 2004; 12: 411-419.
- Richter J, Grifka J, Fissler-Eckhoff A, Mullerck M, Kramer J. Ultrasound morphologic criteria in evaluating meniscus changes. *Z Orthop Ihre Grenzgeb* 1996; 134: 137-143.
- Jacobson J, Van Holsbeeck MT. musculoskeletal Ultrasonography. *Orthop Clin North Am*. 1998; 29: 135-167.
- Silvestri E, Martinoli C, Derchi LE, Bertolotto M, Chaisamondia M, Rosenberg I. Echotexture of peripheral nerves: correlation between US and histologic findings and criteria to differentiate tendons. *Radiology* 1995; 197: 291-296.
- Harcke HT, Grisson LE, Finklestein MS. Evaluation of musculoskeletal system with sonography. *Am J Roentgenol*. 1988; 150: 1253-1261.
- Grifka J, Richter J, Gumatau M. Clinical and Sonographic meniscus diagnosis. *Ortopade* 1994; 23: 102-111.
- Casser HR. Ultrasound diagnosis of the meniscus. 2002; 31: 308-10.
- Jacobson J, Van Holsbeeck MT. musculoskeletal Ultrasonography. *Orthop Clin North Am* 1998; 29: 135-167.
- Najafi J, Bagheri Sh, Lahiji F. The value of microconvex probe in diagnosing meniscal tears compared with sonography. *J.U Med* 2006; 25: 593-597.
- Lin J, Chang Ch. A medial soft-tissue mass of the knee. The phys and sport Med. 1999; 27: 134-137.